

Anthony Hall

Atlas of Male Genital Dermatology

Atlas of Male Genital Dermatology

Anthony Hall

Atlas of Male Genital Dermatology

Anthony Hall
School of Medicine
Deakin University
Geelong, VIC
Australia

Skin and Cancer Foundation Inc
Carlton, VIC
Australia

ISBN 978-3-319-99749-0 ISBN 978-3-319-99750-6 (eBook)

<https://doi.org/10.1007/978-3-319-99750-6>

Library of Congress Control Number: 2018960383

© Springer Nature Switzerland AG 2019

This work is subject to copyright. All rights are reserved by the Publisher, whether the whole or part of the material is concerned, specifically the rights of translation, reprinting, reuse of illustrations, recitation, broadcasting, reproduction on microfilms or in any other physical way, and transmission or information storage and retrieval, electronic adaptation, computer software, or by similar or dissimilar methodology now known or hereafter developed.

The use of general descriptive names, registered names, trademarks, service marks, etc. in this publication does not imply, even in the absence of a specific statement, that such names are exempt from the relevant protective laws and regulations and therefore free for general use.

The publisher, the authors, and the editors are safe to assume that the advice and information in this book are believed to be true and accurate at the date of publication. Neither the publisher nor the authors or the editors give a warranty, express or implied, with respect to the material contained herein or for any errors or omissions that may have been made. The publisher remains neutral with regard to jurisdictional claims in published maps and institutional affiliations.

This Springer imprint is published by the registered company Springer Nature Switzerland AG
The registered company address is: Gewerbestrasse 11, 6330 Cham, Switzerland

This book is dedicated to my wife, Bronwyn and to our three wonderful children whom we love so dearly.

Preface

The perception of most patients and health professionals is that genital disease is mostly sexually transmissible infections (“STIs”). This approach leads to a diligent search for a sexually transmissible disease (“STD”) while the patient is left waiting with anxiety and fears. Once investigations are found to be negative for any sexually transmissible disease, many patients are simply informed they do not have an STD and discharged from care. Often no further treatment or advice is offered. Many patients are left uncertain of their diagnosis with persisting symptoms and some still fear they have cancer.

In reality, most genital disease is skin disease of the male genitalia. Most genital skin disease is either a common inflammatory skin disease involving genitalia, a benign skin disease with predilection for genitalia, or genital dysesthesia. Only a minority of patients with genital skin disease have an STD, and fewer have premalignant or an invasive genital cancer.

Most patients with genital disease are managed well by their family physician, sexual health physician, infectious disease physician, urological surgeon, or gynecologist. This atlas brings the perspective of a dermatologist who specializes in male genital skin diseases.

Managing patients with genital skin disease is both challenging and extremely rewarding. Making the correct diagnosis is fundamental to helping our patients. Hopefully this atlas will aid other health professionals in this field in making a correct diagnosis and offering appropriate treatments for our patients.

Geelong, VIC, Australia
Carlton, VIC, Australia

Anthony Hall

Acknowledgements

Thank you to my colleagues and staff at both Baycity Dermatology and the Skin & Cancer Foundation in Victoria and to Grant Weston, Lee Klein, Andre Tournois and Dinesh Vinayagam at Springer Nature for help with this project.

Contents

1 Introduction	1
Reference	2
2 History	3
3 Examination	5
Reference	6
Suggested Reading	6
4 Investigations and Genital Skin Biopsy	7
4.1 Choice of Investigations.....	7
4.2 Genital Skin Biopsy.....	7
4.2.1 Indications and Choice of Technique.....	7
4.2.2 Biopsy Technique.....	8
4.2.3 Increasing Diagnostic Accuracy	9
5 General Management of Genital Skin Disease	11
References.....	12
6 Pearly Penile Papules	13
6.1 Definition	13
6.2 Aetiology	13
6.3 Clinical Features	13
6.4 Diagnosis	13
6.5 Treatment	14
References.....	14
7 Ectopic Sebaceous Glands (Fordyce Spots) and Median Raphe Cysts	15
7.1 Definition	15
7.2 Aetiology	15
7.3 Clinical Features	15
7.4 Diagnosis	16
7.5 Treatment	16
References.....	17
8 Angiokeratoma of Fordyce	19
8.1 Definition	19
8.2 Aetiology	19
8.3 Clinical Features	19
8.4 Diagnosis	19
8.5 Treatment	19
References.....	20
9 Pigmentary Disorders and Color Variation	21
9.1 Definition	21
9.2 Aetiology	21

9.3	Clinical Features	21
9.4	Diagnosis	23
9.5	Treatment	23
	References	24
10	Phimosis	25
10.1	Definition	25
10.2	Aetiology	25
10.3	Clinical Features	25
10.4	Diagnosis	26
10.5	Treatment	26
	References	27
11	Balanitis and Balanoposthitis	29
11.1	Definition	29
11.2	Aetiology	29
11.3	Clinical Features	29
11.4	Diagnosis	30
11.5	Treatment	31
	References	32
12	Intertriginous Dermatoses	33
12.1	Definition	33
12.2	Aetiology	33
12.3	Clinical Features	34
12.4	Diagnosis	35
12.5	Treatment	35
	Reference	35
13	Psoriasis	37
13.1	Definition	37
13.2	Aetiology	37
13.3	Clinical Features	37
13.4	Diagnosis	38
13.5	Treatment	39
	References	40
14	Atopic Dermatitis (Atopic Eczema)	41
14.1	Definition	41
14.2	Aetiology	41
14.3	Clinical Features	41
14.4	Diagnosis	41
14.5	Treatment	42
	References	43
15	Irritant (Contact) Dermatitis	45
15.1	Definition	45
15.2	Aetiology	45
15.3	Clinical Features	45
15.4	Diagnosis	46
15.5	Treatment	46
16	Allergic Contact Dermatitis	49
16.1	Definition	49
16.2	Aetiology	49
16.3	Clinical Features	49
16.4	Diagnosis	49
16.5	Treatment	50
	References	51

17	Lichen Simplex Chronicus, Prurigo Nodularis, Picker's Nodule	53
17.1	Definitions	53
17.2	Aetiology	53
17.3	Clinical Features	53
17.4	Diagnosis	53
17.5	Treatment	54
	Reference	56
18	Seborrhoeic Dermatitis and Sebo-psoriasis	57
18.1	Definitions	57
18.2	Aetiology	57
18.3	Clinical Features	57
18.4	Diagnosis	58
18.5	Treatment	59
	Reference	59
19	Lichen Sclerosus	61
19.1	Definition	61
19.2	Aetiology	61
19.3	Clinical Features	61
19.4	Diagnosis	62
19.5	Treatment	62
	References	64
20	Lichen Planus	67
20.1	Definition	67
20.2	Aetiology	67
20.3	Clinical Features	67
20.4	Diagnosis	67
20.5	Treatment	68
	References	69
21	Plasma Cell (Zoon's) Balanitis	71
21.1	Definition	71
21.2	Aetiology	71
21.3	Clinical Features	71
21.4	Diagnosis	72
21.5	Treatment	73
	References	73
22	Candidiasis	75
22.1	Definition	75
22.2	Aetiology	75
22.3	Clinical Features	75
22.4	Diagnosis	76
22.5	Treatment	76
	References	77
23	Tinea (Dermatophytosis)	79
23.1	Definition	79
23.2	Aetiology	79
23.3	Clinical Features	79
23.4	Diagnosis	80
23.5	Treatment	81
	Reference	81

24	Herpes Simplex Virus	83
24.1	Definition	83
24.2	Aetiology	83
24.3	Clinical Features	83
24.4	Diagnosis	85
24.5	Treatment	85
	References	85
25	Genital Warts (Condyloma Acuminata)	87
25.1	Definition	87
25.2	Aetiology	87
25.3	Clinical Features	87
25.4	Diagnosis	89
25.5	Treatment	89
	Reference	89
26	Molluscum Contagiosum	91
26.1	Definition	91
26.2	Aetiology	91
26.3	Clinical Features	91
26.4	Diagnosis	92
26.5	Treatment	92
	Suggested Reading	92
27	Impetigo and Superficial Pyogenic Bacterial Infections	93
27.1	Definition	93
27.2	Aetiology	93
27.3	Clinical Features	93
27.4	Diagnosis	93
27.5	Treatment	94
	Suggested Reading	94
28	Fournier's Gangrene	95
28.1	Definition	95
28.2	Aetiology	95
28.3	Clinical Features	95
28.4	Diagnosis	95
28.5	Treatment	95
	Reference	96
29	Erythrasma	97
29.1	Definition	97
29.2	Aetiology	97
29.3	Clinical Features	97
29.4	Diagnosis	97
29.5	Treatment	98
	References	98
30	Syphilis	99
30.1	Definition	99
30.2	Aetiology	99
30.3	Clinical Features	99
30.4	Diagnosis	100
30.5	Treatment	100
	References	101

31 Scabies	103
31.1 Definition	103
31.2 Aetiology	103
31.3 Clinical Features	103
31.4 Diagnosis	103
31.5 Treatment	105
References	106
Suggested Reading	106
32 Pediculosis Pubis	107
32.1 Definition	107
32.2 Aetiology	107
32.3 Clinical Features	107
32.4 Diagnosis	107
32.5 Treatment	107
References	108
Suggested Reading	108
33 Genital Granulomatous Diseases	109
33.1 Definition	109
33.2 Aetiology	109
33.3 Clinical Features	109
33.4 Diagnosis	110
33.5 Treatment	111
References	111
34 Genital Edema and Lymphedema	113
34.1 Definition	113
34.2 Aetiology	113
34.3 Clinical Features	113
34.4 Diagnosis	114
34.5 Treatment	115
References	115
35 Male Genital Dysaesthesia	117
35.1 Definition	117
35.2 Aetiology	117
35.3 Clinical Features	117
35.4 Diagnosis	117
35.5 Treatment	117
References	119
36 Superficial Thrombophlebitis of the Penis (Penile Mondor's Disease)	121
36.1 Definition	121
36.2 Aetiology	121
36.3 Clinical Features	121
36.4 Diagnosis	121
36.5 Treatment	121
References	122
37 Fixed Drug Eruption (Reaction)	123
37.1 Definition	123
37.2 Aetiology	123
37.3 Clinical Features	123
37.4 Diagnosis	123
37.5 Treatment	124
References	124

38	Darier's Disease and Papular Acantholytic Dyskeratosis	125
38.1	Definition	125
38.2	Etiology	125
38.3	Clinical Features	125
38.4	Diagnosis	127
38.5	Treatment	127
	References	127
39	Hailey-Hailey Disease (Familial Benign Chronic Pemphigus)	129
39.1	Definition	129
39.2	Aetiology	129
39.3	Clinical Features	129
39.4	Diagnosis	129
39.5	Treatment	129
	References	130
40	Hidradenitis Suppurativa	133
40.1	Definition	133
40.2	Aetiology	133
40.3	Clinical Features	133
40.4	Diagnosis	135
40.5	Treatment	135
	References	136
41	Pemphigus and Pemphigoid	137
41.1	Definition	137
41.2	Aetiology	137
41.3	Clinical Features	137
41.4	Diagnosis	137
41.5	Treatment	138
42	Aphthous Ulcers and Behçet's Disease	141
42.1	Definition	141
42.2	Aetiology	141
42.3	Clinical Features	141
42.4	Diagnosis	141
42.5	Treatment	142
	References	143
43	Reactive Arthritis	145
43.1	Definition	145
43.2	Aetiology	145
43.3	Clinical Features	145
43.4	Diagnosis	145
43.5	Treatment	146
	References	146
44	Trauma and Artefactual Disease	147
44.1	Definition	147
44.2	Aetiology	147
44.3	Clinical Features	148
44.4	Diagnosis	148
44.5	Treatment	149
	References	149

45	Benign Melanocytic Nevus	151
45.1	Definition	151
45.2	Aetiology	151
45.3	Clinical Features	151
45.4	Diagnosis	152
45.5	Treatment	152
	References	152
46	Genital Melanotic Macules and Genital Lentiginosis	153
46.1	Definition	153
46.2	Aetiology	153
46.3	Clinical Features	153
46.4	Diagnosis	154
46.5	Treatment	155
	References	155
47	Seborrhoeic Keratoses	157
47.1	Definition	157
47.2	Aetiology	157
47.3	Clinical Features	157
47.4	Diagnosis	159
47.5	Treatment	159
	Reference	159
48	Vitiligo and Acquired Depigmentation	161
48.1	Definition	161
48.2	Aetiology	161
48.3	Clinical Features	161
48.4	Diagnosis	161
48.5	Treatment	163
	References	164
49	Scrotal Epidermal (Epidermoid) Cysts and Idiopathic Scrotal Calcinosis	165
49.1	Definition	165
49.2	Aetiology	165
49.3	Clinical Features	165
49.4	Diagnosis	167
49.5	Treatment	167
	References	167
50	Penile Intraepithelial Neoplasia (Erythroplasia of Queyrat, Bowen's Disease)	169
50.1	Definition	169
50.2	Aetiology	169
50.3	Clinical Features	169
50.4	Diagnosis	170
50.5	Treatment	170
	References	171
	Suggested Reading	172
51	Bowenoid Papulosis	173
51.1	Definition	173
51.2	Aetiology	173
51.3	Clinical Features	173
51.4	Diagnosis	174
51.5	Treatment	174
	References	175

52	Pseudoepitheliomatous Keratotic and Micaceous Balanitis and Penile Cutaneous Horn	177
52.1	Definition	177
52.2	Aetiology	177
52.3	Clinical Features	177
52.4	Diagnosis	178
52.5	Treatment	178
	References	178
53	Cancer of the Penis	179
53.1	Definition	179
53.2	Aetiology	179
53.3	Clinical Features	179
53.4	Diagnosis	180
53.5	Treatment	181
	References	182
54	Buschke-Löwenstein Tumour (Giant Condyloma Acuminatum) and Verrucous Carcinoma	183
54.1	Definition	183
54.2	Aetiology	183
54.3	Clinical Features	183
54.4	Diagnosis	183
54.5	Treatment	184
	References	185
55	Melanoma	187
55.1	Definition	187
55.2	Aetiology	187
55.3	Clinical Features	187
55.4	Diagnosis	187
55.5	Treatment	188
	References	188
56	Extramammary Paget's Disease	189
56.1	Definition	189
56.2	Aetiology	189
56.3	Clinical Features	189
56.4	Diagnosis	189
56.5	Treatment	190
	References	191
	Index	193

Most genital disease is disease of genital skin. Many male patients fear their genital skin disease is either a sexually transmissible infection (STI) or a genital cancer. Correctly diagnosing and managing patients with concerns about their genitalia or genital disease takes skill and expertise but can be mastered with practice. Improving management of these patients ameliorates symptoms and alleviates distress, anxiety and often hidden fears.

The anogenital region is the crossroad of four organ systems: skin (the integument), reproductive system, urinary system and alimentary system (gastro-intestinal system or gut). Diseases of male genital skin may be common dermatoses occurring on the genitalia or dermatoses with a predilection for genital skin. Confusion arises with variation of the appearance of genitalia, common anatomic variants, and different presentations of dermatoses of the anogenital

region. The presence of a foreskin (prepuce) may alter the appearance of genital skin disease and is associated with a higher likelihood of genital disease. Finally, the appearance of genital disease may be further altered by prescribed or self-prescribed (“over-the-counter”) treatments.

The glans penis (or simply “the glans”) may be partially or totally covered by the foreskin (prepuce) in the flaccid (non-erect) state (Figs. 1.1, 1.2, and 1.3). The foreskin is covered with non-hair-bearing, keratinised skin externally, but the inner aspect and frenulum are poorly keratinised [1]. The foreskin is attached to the ventral aspect of the glans at the frenulum, forming a web similar to the frenulum on the undersurface

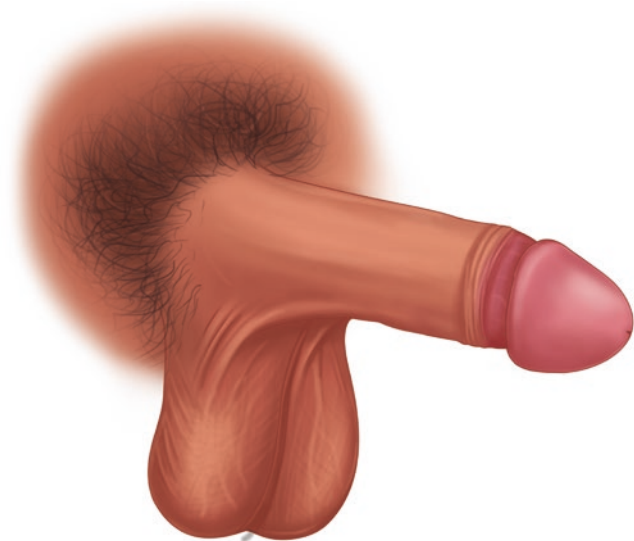

Fig. 1.1 Appearance of male genitalia (circumcised)

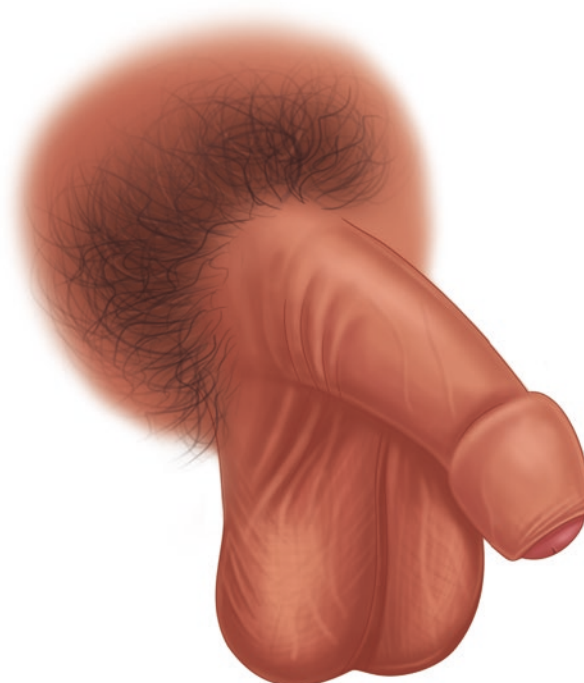

Fig. 1.2 Appearance of male genitalia (uncircumcised)

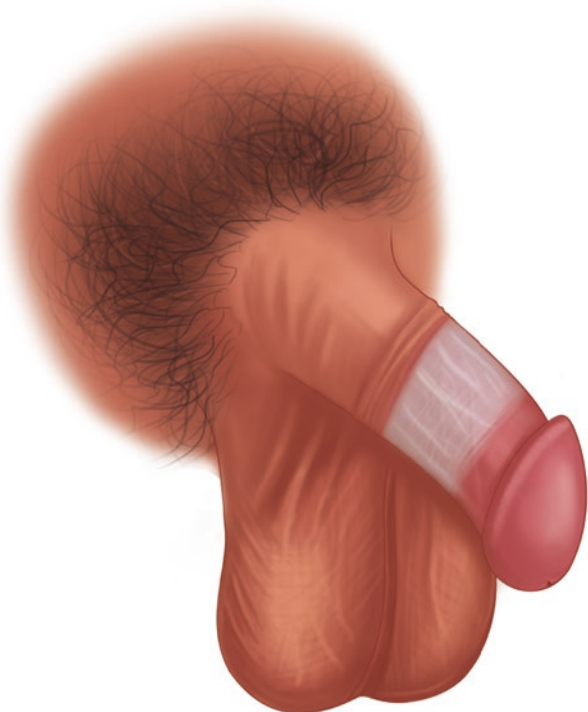

Fig. 1.3 Appearance of male genitalia (uncircumcised) with retraction of foreskin

(ventral aspect) of the tongue. The glans is keratinised in both circumcised and uncircumcised males [1]. The corona of the glans is a circumferential (annular) elevation at the base of the glans, often darker in colour than the rest of the glans. The narrowing at the junction of the glans and the penile shaft is termed the coronal sulcus, neck, or retroglandular sulcus.

Under the foreskin is an intertriginous region known as the preputial recess, balano-preputial recess, retroglandular sulcus, or simply subprepuce (Fig. 1.4). The balano-preputial recess (a potential space) disappears with full erection, when the foreskin becomes continuous with the elongated, erect penile shaft. When the prepuce is retracted in the flaccid

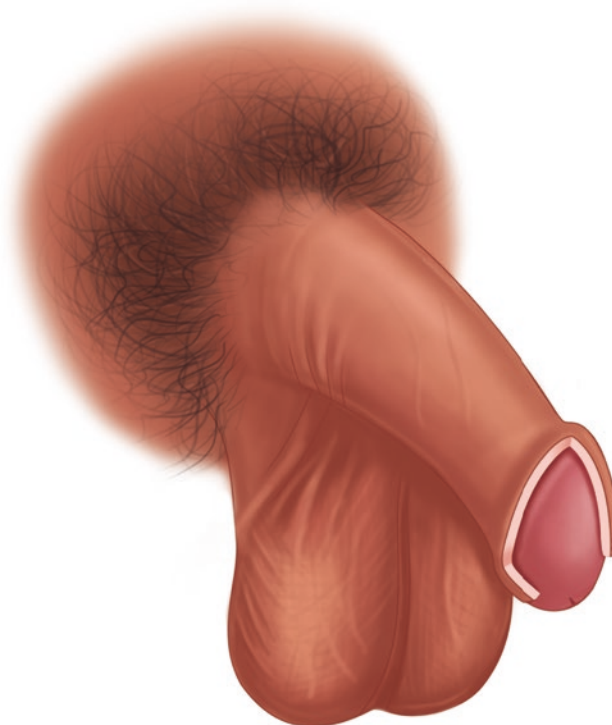


Fig. 1.4 Diagram of preputial recess or subprepuce (uncircumcised male)

state, the skin of the subprepuce appears thinner, partially translucent and more erythematous, with visible superficial blood vessels. Confusion may arise between the normal appearance of the subprepuce and irritant dermatitis. This confusion may be exacerbated by the use of a topical corticosteroid beneath the foreskin, leading to concern of possible corticosteroid atrophy.

Reference

1. McCoombe SG, Short RV. Potential HIV-1 target cells in the human penis. *AIDS*. 2006;20:1491–5.

Taking time to obtain a history (before examination) demonstrates that you are listening and that you care (Fig. 2.1). Listening forms part of the therapeutic process. By necessity, the initial history should be brief and focused. When taking a history, be relaxed and non-judgmental, recognising that many patients with genital problems conceal anxiety and possible fears. Many patients with a genital problem report that they feel previous doctors have not listened to them.

Careful history taking should take less than 8 minutes. A focussed history is often more valuable than rushing too quickly to arrange investigations. However, a more comprehensive history may yield irrelevant or confounding information. Begin with open questions, such as “What bothers you?” Then let the patient tell his story without interrupting. Few people can talk uninterrupted for more than 5 minutes. Clarify aspects of the history with direct or closed questions. Assume nothing. Ascertain whether the patient is currently using any topical preparation (both prescribed and “over the counter”) or taking any oral medications. Enquire about the response to previous topical treatments. Ask about previous

skin disease, sexually transmissible infections (STIs), and whether condoms are regularly used. Condom usage helps to determine the risk of a possible underlying STI. Ask if the patient is currently sexually active. If the patient is sexually active, are the sexual partners female, male, or both? Don’t assume preference. If your patient is sexually active, tactfully enquire about the number of sexual partners in the past few years. This helps to stratify the risk of a sexually transmissible infection (STI).

During the consultation, it is prudent to enquire about any underlying concerns of an STI or malignancy. Try to ascertain the patient’s belief about the cause of his genital problem. Many patients want to offer an explanation of the cause of their problem. However these beliefs may be erroneous, based on previous professional advice or misinformation from social media or the Internet. During history taking (and while examining a patient with genital disease) ask yourself “why is this patient here today?” and “why have they presented now?”



Fig. 2.1 Take time to obtain a history and listen to your patient

Pearls

- Taking time to obtain a history demonstrates that you are listening and you care. Listening is the beginning of the therapeutic process.
- “Listen to the patient. He is telling you the diagnosis.” —*William Osler*
- “It is much more important to know what sort of a patient has a disease than what sort of a disease a patient has.” —*William Osler*

Examination

3

Careful examination is very important to formulate a diagnosis. The time taken to note and record examination findings helps in making a clinical diagnosis. Clinical examination is guided by careful history taking. Ignoring clues in the history and proceeding too quickly to examination can lead to an incorrect diagnosis.

Male patients (like female patients) often feel uncomfortable with genital examination. Respect your patient's modesty when examining his genital region by offering a covering blanket or sheet (Fig. 3.1). Good lighting with magnification is essential.

First and most importantly, note if the patient is circumcised or uncircumcised. The presence of the foreskin is an important risk factor for many genital diseases. Some patients state that they are circumcised but on examination their glans is partly covered by a shortened or residual foreskin, sometimes referred to as a "neo-foreskin." If the patient is uncircumcised, carefully retract the foreskin to examine the subpreputial recess (subprepuce). Note if the foreskin retracts easily and painlessly. Both phimosis (inability to retract the foreskin) and constriction of the distal penile shaft on retracting a tightened foreskin ("waisting") are suggestive of lichen sclerosus. Smegma, a collection of secretions and shed skin under the foreskin [1], can mimic candidiasis or irritant (contact) dermatitis.

Methodically examine the glans, frenulum ventrally, coronal sulcus, penile shaft, scrotum and perianal region. Finally, quickly examine other important sites (scalp, conchal bowl, oral mucosa, nails, elbows, knees, and flexures) to look for evidence of more widespread dermatoses such as psoriasis or lichen planus. Even examination of the back may reveal significant disease that the patient is unaware of. Clinical photographs (with patient consent) are very useful, forming an important part of the medical record. Photographs are even more important when the diagnosis is uncertain. Clinical photography is helpful in monitoring genital disease and assessing response to treatment.

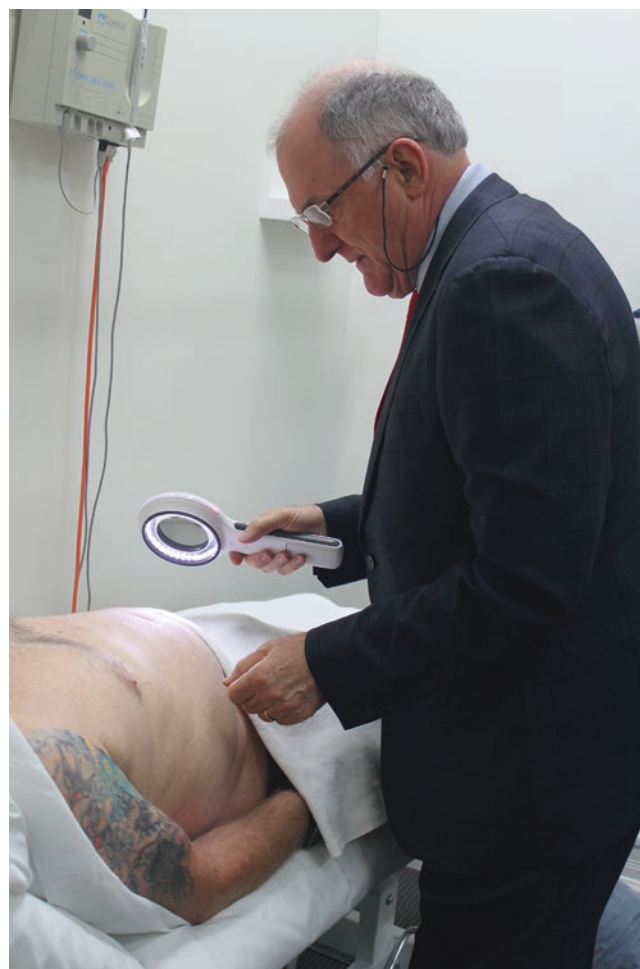

Fig. 3.1 Careful examination is important to formulate a diagnosis

Terminology is important in enabling a more accurate clinical diagnosis and communicating findings to colleagues. An accurate morphologic description of a lesion helps pathology colleagues to make a histopathologic diagnosis. Skin lesions

are described by morphology (shape and consistency) and size (Table 3.1). Differences in definitions exist. The size of skin lesions may be divided into those under or over 5 mm in diameter, while other experts set the defining boundary as under or over 10 mm in diameter. Flat lesions are simply changes in skin color. A flat skin lesion up to 5 mm in diameter is a *macule*; a flat lesion greater than 5 mm is a *patch*. A solid, raised skin lesion up to 5 mm in diameter is a *papule*, whereas a solid, symmetrical, raised lesion greater than 5 mm in diameter is a *nodule*. If the diameter of a solid, raised skin lesion is greater than its height, the lesion is a *plaque*. (Some define a plaque as greater than 20 mm in diameter). A lesion up to 5 mm in diameter filled with clear fluid is a *vesicle*. If the lesion filled with clear fluid is greater than 5 mm in diameter, the lesion is a *bulla*. A fluid-filled lesion containing polymorphs with opalescent (cloudy) fluid is a *pustule*, regardless of size. An *erosion* is superficial loss of skin that usually heals without scarring, whereas an *ulcer* is deeper loss of skin (involving dermis and possible underlying adipose tissue) that heals with scarring. Raised scars are either a *hypertrophic* scar or a *keloid scar*, if the scar extends beyond the original area of damage. Conversely a scar may be depressed. Secondary changes such as superficial secondary bacterial infection (impetiginisation) may alter the appearance of a lesion. If there are multiple lesions of various sizes, it is best to use the morphologic term that fits the majority of the lesions. Sometimes a combination of terms (eg, papulonodular, vesiculo-bullous) may be used for lesions of varying morphology.

After attempting to describe the morphology of each lesion, determine if there is any significant configuration or arrangement of lesions (eg, clustered or agminate, annular, serpiginous or dermatomal). Finally, note the anatomical dis-

tribution of lesions and decide whether the lesions are arranged symmetrically or asymmetrically. Inflammatory skin diseases (atopic dermatitis, stasis dermatitis, psoriasis) tend to be symmetrically arranged, whereas skin infections or neoplastic lesions tend to be asymmetric. Infections occur focally but may later spread. Neoplastic lesions are caused by a genetic mutation so are mostly solitary and asymmetric. There are exceptions to these generalisations. Both lepromatous leprosy (a cutaneous infectious disease) and cutaneous T-cell lymphoma (a cutaneous neoplastic disease) may be symmetrically arranged. Certain inflammatory skin diseases have characteristic arrangements. For example, psoriasis is mostly a symmetric disease of extensor aspects of elbows and knees, whereas atopic dermatitis is symmetrically arranged on flexor aspects of elbows and knees. Tinea cruris often presents symmetrically as an intertriginous eruption of groins where skin surfaces are opposed.

Pearls

- “More mistakes are made by not looking than by not knowing.”—*John Colvin (Ophthalmologist; Melbourne, Australia)*
- “The value of experience is not in seeing much but in seeing wisely.”—*William Osler*

Table 3.1 Descriptive (morphologic) terms for skin lesions

Description	Diameter < 5 mm	Diameter > 5 mm
Flat lesion	Macule	Patch
Raised, solid lesion	Papule	Nodule or plaque (flatter)
Fluid-filled (clear)	Vesicle	Bulla
Fluid-filled (cloudy)	Pustule	Pustule

Reference

1. Van Howe RS, Hodges FM. The carcinogenicity of smegma: debunking a myth. *J Eur Acad Dermatol Venereol*. 2006;20:1046–54.

Suggested Reading

Stamm AW, Kobashi KC, Stefanovic KB. Urologic dermatology: a review. *Curr Urol Rep*. 2017;18:62.

4.1 Choice of Investigations

Investigations for patients with genital skin disease are relatively few. The use of Wood's (UVA) lamp examination of groins and axillae is important if erythrasma is suspected. Microscopy of skin scrapings at the bedside helps confirm the diagnosis of scabies or pubic lice (pediculosis pubis). A skin swab for microscopy and culture is of value if a bacterial or yeast infection is suspected. A dry skin swab from any eroded or ulcerated area is important for nucleic acid amplification testing (polymerase chain reaction, PCR) to confirm or exclude herpes simplex virus (HSV) infection. Nucleic acid amplification testing (using a urethral swab or urine sample) has greatly increased diagnostic accuracy for HSV, *Neisseria gonorrhoeae*, and *Chlamydia trachomatis* infection. Skin scrapings for microscopy and culture are important to detect a dermatophyte infection such as tinea cruris. Serological screening for a possible underlying sexually transmissible infection (STI) is important to help reassure an anxious male patient who fears a possible underlying STI. If one STI is detected, screening for other STIs is mandatory, as "STIs travel in packs." Serological testing for syphilis, hepatitis B, hepatitis C, and HIV is determined by individual risk. Any patient with a genital ulcer should be investigated with a skin swab taken for microscopy and culture, HSV testing of the skin swab by PCR and serological testing for syphilis, hepatitis B, hepatitis C and HIV. Skin biopsy of a genital ulcer for histological examination is often useful. Finally, skin patch testing is essential if allergic contact dermatitis is suspected.

4.2 Genital Skin Biopsy

4.2.1 Indications and Choice of Technique

Clinico-pathological correlation is often important in making a diagnosis of genital skin disease. A carefully selected skin biopsy may help to differentiate between common

inflammatory dermatoses, premalignant diseases (lichen sclerosus, penile intraepithelial neoplasia) and invasive cancer of genital skin. There are limitations in histological interpretation of inflammatory disorders and some diseases of unknown aetiology (eg, plasma cell balanitis). Eczema or dermatitis (eg, irritant dermatitis) usually shows a spongiotic histological pattern but provides no information regarding the aetiology of the genital dermatitis. If the epidermis is missing in erosive lichen planus, histological interpretation is quite difficult. Other lichenoid reaction patterns (eg, fixed drug eruption) may be difficult to interpret histologically.

Knowing what type of skin biopsy to perform and when to take a skin biopsy is crucial. Having a low threshold for genital skin biopsy is wise if premalignant or malignant disease is suspected or needs to be excluded. Reluctance to perform a genital skin biopsy inevitably complicates subsequent management and jeopardises treatment. Most male patients are apprehensive about genital skin biopsy but a clinician who projects confidence and explains the benefits of the biopsy usually overcomes fear of the procedure. Explaining that the pain of infiltration of the local anesthetic is short-lived and that the local anesthetic results in a pain-free procedure helps to overcome any apprehension.

The glans penis is involved in many male genital skin diseases. Bleeding and scarring are the main complications of biopsy of the glans. Punch biopsy with a 3- or 4-mm punch biopsy sample is the preferred method for suspicious non-pigmented lesions of the glans. (Often larger 5- or 6-mm punch biopsy samples are preferred for biopsying the vulval region in women, as bleeding and scarring are not as likely.) Alternative biopsy techniques for the glans penis include deep incisional biopsy or excisional biopsy, especially when invasive cancer is suspected.

For a suspicious pigmented lesion, shave biopsy or total excision biopsy is preferred, enabling the whole lesion to be removed for histological examination. Pigmented lesions are not necessarily uniform throughout the entire lesion so punch biopsy is contraindicated. A punch biopsy may miss

a malignant focus by sampling a site without significant pathology. If not confident in shave biopsy technique, then total excision biopsy is preferred for a pigmented lesion. Shave biopsy is both a diagnostic and therapeutic procedure for removing a suspicious lesion of the penile shaft. Curette or snip biopsies (for pedunculated lesions) are occasionally used for genital skin disease.

4.2.2 Biopsy Technique

Before taking a genital skin biopsy, ascertain if there has been a previous adverse reaction to a local anesthetic agent. Warn the patient that taking a genital skin biopsy may result in scarring of the glans. After obtaining consent, proceed quickly with biopsy, as further delay increases patient anxiety. Constant patient reassurance during the procedure (“talk therapy”) helps an anxious patient. Use of a topical anesthetic gel or cream prior to infiltration further delays taking the genital biopsy and (in the author’s opinion) is not beneficial.

The patient should be lying supine in case of vasovagal response. Mark the biopsy site before infiltrating the local anesthetic (Fig. 4.1). Infiltrate slowly with a 30-gauge needle.

A suitable local anaesthetic is 1% or 2% lignocaine (lidocaine) combined with 1:200,000 adrenaline (epinephrine). The addition of adrenaline (epinephrine) to local anaesthetic for genital infiltration is considered controversial by some clinicians. Each clinician needs to decide if they are comfortable using adrenaline (epinephrine) with the local anaesthetic for penile infiltration. The author has never experienced

any problems using a small volume (0.1–0.2 mL) of 1% or 2% lignocaine (lidocaine) combined with 1:200,000 adrenaline (epinephrine), producing a small dermal bleb with the local anaesthesia. After achieving local anaesthesia (test with the infiltrating needle) gently rotate a 3-mm (disposable) punch biopsy with minimal pressure (Fig. 4.2).

Elevate the biopsy specimen with the same infiltrating needle, to avoid crushing the biopsy specimen. (Crushing the biopsy specimen makes histological interpretation of the tissue more difficult.) Cut the elevated skin biopsy with surgical scissors or a scalpel blade (Fig. 4.3). Haemostasis is achieved by inserting an absorbable suture (Figs. 4.4 and 4.5). After suturing the biopsy site, apply a gauze dressing to help absorb any haemoserous ooze. The absorbent dressing also provides psychological support to an apprehensive patient.

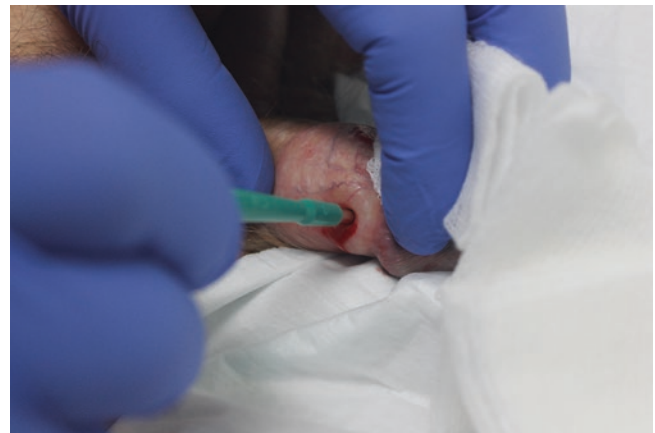

Fig. 4.2 Gently inserting and rotating the punch biopsy with minimal pressure

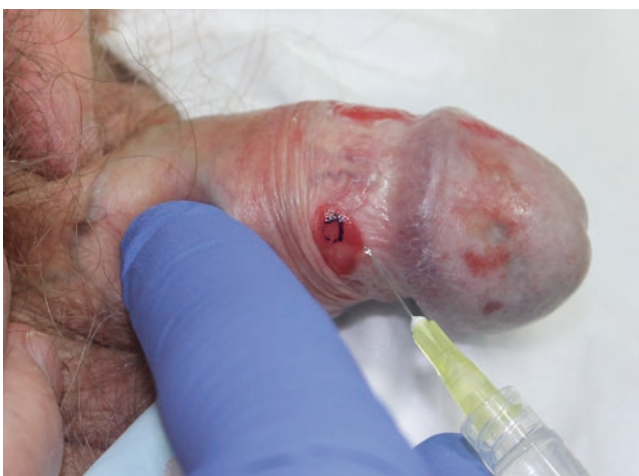

Fig. 4.1 Infiltrating marked biopsy site with patient supine

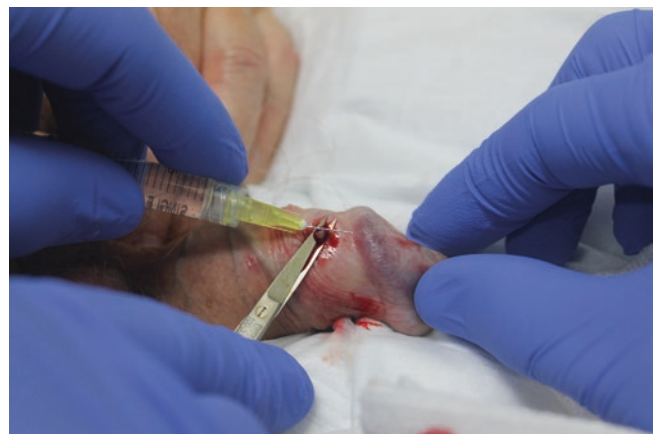

Fig. 4.3 Removing elevated skin biopsy with surgical scissors

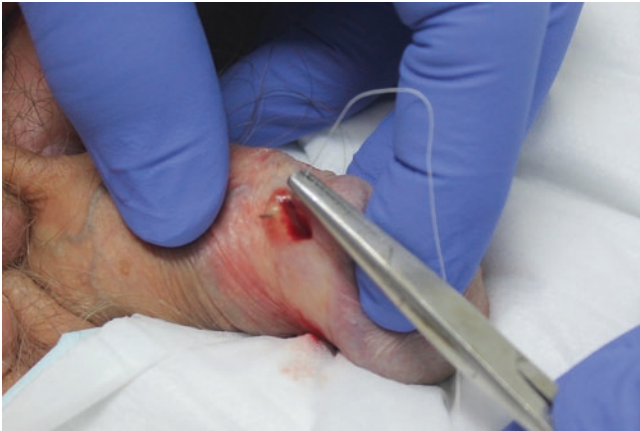

Fig. 4.4 Suturing biopsy site

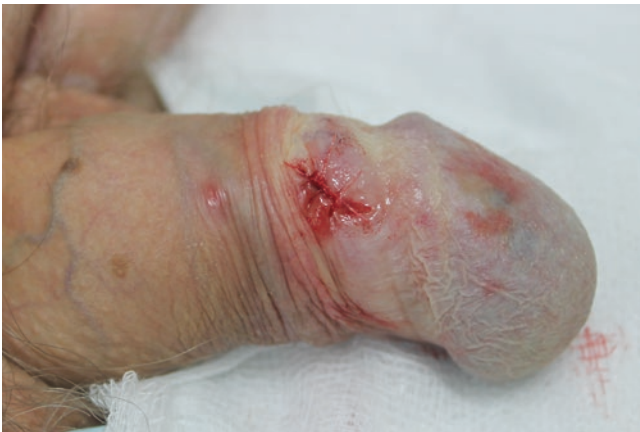

Fig. 4.5 Final result after suturing

To biopsy a suspicious pigmented lesion or remove a keratotic lesion by shave excision, use a flexible razor blade rather than a rigid scalpel blade. Making a flexible razor blade

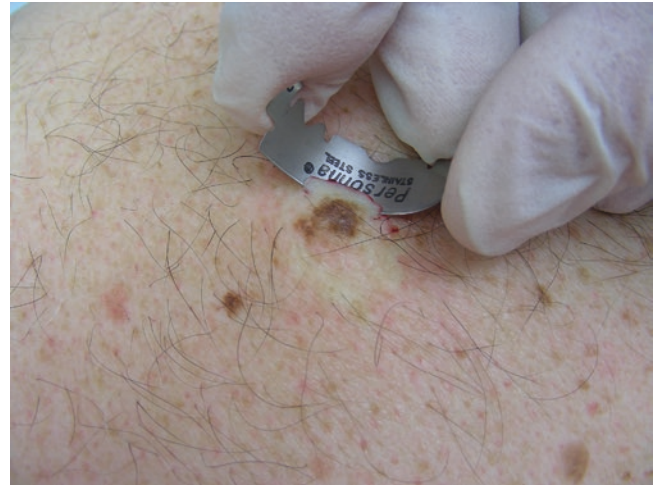

Fig. 4.6 Shave biopsy technique with flexible razor blade

convex enables a deeper shave biopsy to be taken, minimising transecting the base of the pigmented lesion (Fig. 4.6). A chemical haemostatic solution such as 20% aluminium chloride hexahydrate helps to achieve haemostasis after a shave biopsy.

4.2.3 Increasing Diagnostic Accuracy

Provide the referring histopathologist with all relevant clinical information and important differential diagnoses. If there is marked discrepancy between the clinical and histopathological diagnosis, talk with your histopathology colleague. Clinico-pathological correlation increases the accuracy of the diagnosis. Making an accurate diagnosis is important not only for better management but also for ongoing research into genital skin diseases.

Pearls

- Have a low threshold for biopsying any genital lesion.
- Genital biopsy is essential if malignancy cannot confidently be excluded on clinical grounds.

General Management of Genital Skin Disease

5

Diagnostic accuracy is the cornerstone of successful management of genital skin disease, but it is not always possible. Some diseases defy an initial specific or accurate diagnosis. Conferring with colleagues from different disciplines, being prepared to repeat a skin biopsy, and undertaking careful long-term follow-up (“tincture of time”) are all essential in managing a patient with genital skin disease.

The first principle in managing any patient with a genital disease is to explain the diagnosis in terms the patient can understand. Many patients complain they were never given a specific diagnosis. Next, address any fears of an underlying sexually transmissible infection (STI) or possible cancer. If one STI is diagnosed, screening for other STIs is essential. Partner notification and screening is essential for any patient with a diagnosed STI. Notification of health authorities of a communicable disease is mandatory in many countries.

General measures include encouraging use of non-soap wash, regular use of moisturiser (particularly after washing), and removing any skin irritants. Bland emollients such as soft white paraffin (white petrolatum, petroleum jelly) or 50% liquid paraffin in white soft paraffin are useful as both a moisturiser and a lubricant for sexual activity. Advise the patient to cease all unnecessary topical preparations, including over-the-counter antiseptic or antibacterial preparations that are heavily promoted for “skin hygiene”. Topical applications applied to the genital region may be skin irritants. Cool bathing (“Sitz” or hip bath) is soothing for any weeping, infected, or painful genital dermatosis. Plain water, saline, dilute sodium bicarbonate, or dilute white vinegar may all be used in a Sitz bath. If bathing is not possible, cool soaks with a cloth or gauze moistened with saline or dilute white vinegar provide great symptomatic relief.

Topical corticosteroids are still the mainstay of topical therapy in genital dermatology, having stood the test of time. Topical corticosteroids are safe and effective for most inflammatory genital dermatoses. There is a tendency to use low-potency topical corticosteroids (Group VII) on the genital region rather than more potent topical corticosteroids (Group

I to III). A better and quicker response is achieved by starting with moderate or ultrapotent topical corticosteroids (Group I–II) for a short period (2–4 weeks) to induce remission. After this induction phase, wean to a less potent topical corticosteroid (Group VI–VII). This regimen allows the patient to receive the greatest benefit from topical corticosteroids with minimal adverse effects. Make sure the patient does not continue to use a moderate or ultrapotent topical corticosteroid for a longer period on genital skin.

Vitamin D analogues (*eg*, calcipotriol) are useful as monotherapy for psoriasis at non-genital sites but may cause irritation when used on anogenital skin. Irritation from topical Vitamin D analogues may be reduced by combination with a mild (Class VII) topical corticosteroid.

Tar-based topical preparations (*eg*, 3–5% LPC in Aqueous cream) combined with a weak topical corticosteroid (*eg*, 1% hydrocortisone) often help perianal psoriasis but are irritant to genital skin. Use of tar-based topical preparations should be avoided on genital skin.

Calcineurin inhibitors (pimecrolimus, tacrolimus) are widely used as corticosteroid-sparing topical agents at non-genital sites but they may cause irritation and stinging when applied to genital region. Uncertainty about the long-term safety of calcineurin inhibitors on mucosal surfaces has been expressed [1]. Calcineurin inhibitors are also more expensive than topical corticosteroids.

Topical antibiotics or topical azole preparations are useful for superficial or concurrent anogenital skin infections. Use of topical anthralin (dithranol), topical tazarotene and ultraviolet (UV) light treatment should be avoided in the genital region [2].

Long-term follow-up for premalignant genital skin diseases such as penile intraepithelial neoplasia (in situ squamous cell carcinoma, erythroplasia of Queyrat, or Bowen’s disease) and extramammary Paget’s disease is necessary to detect transformation to invasive disease. Reviewing patients and careful follow-up are essential when the diagnosis is uncertain, aided by clinical photography and repeated skin biopsy, if necessary.

Pearls

- Topical corticosteroids are safe and effective for most inflammatory genital skin disease.
- Start with a more potent topical corticosteroid and then wean to a milder topical steroid, to be used only as needed.
- Poor response of an inflammatory genital dermatosis to topical corticosteroids requires reassessment of the diagnosis and evaluation of compliance.

References

1. Margesson LJ. Overview of treatment of vulvovaginal disease. *Skin Therapy Lett.* 2011;16(3):5–7.
2. Meeuwis KA, de Hullu JA, Massuger LF, van de Kerkhof PC, van Rossum MM. Genital psoriasis: a systematic literature review on this hidden skin disease. *Acta Derm Venereol.* 2011;91(1):5–11.

Pearly Penile Papules

6

6.1 Definition

Pearly penile papules are common small, asymptomatic papules occurring on the corona of the glans in normal males.

6.2 Aetiology

The aetiology of pearly penile papules is unknown, as for other cutaneous angiofibromas. Pearly penile papules are histologically angiofibromas, identical to other cutaneous angiofibromas including fibrous papules of the nose and angiofibromas of the face associated with tuberous sclerosis.

6.3 Clinical Features

Pearly penile papules consist of small, asymptomatic, pale pink to red papules (1–3 mm in diameter), that are often arranged in single, double or triple rows on the corona of the glans (Figs. 6.1, 6.2, and 6.3). They are seen in up to one third of normal males [1], are more visible in uncircumcised men, and regress with age [2]. Occasionally, pearly penile papules are filiform and may occur on the penile shaft or the glans itself. Pearly penile papules may cause significant distress and anxiety in adolescent males, who are concerned about possible genital warts (condyloma acuminata) [3].

6.4 Diagnosis

Diagnosis is usually straightforward clinically. Dermoscopic features have been described. Papules demonstrate a whitish-pink cobblestone or grape-like appearance with central dotted or comma-like vessels surrounded by crescent-shaped white structures [4]. Differential diagnosis includes Fordyce spots and condyloma acuminata (genital

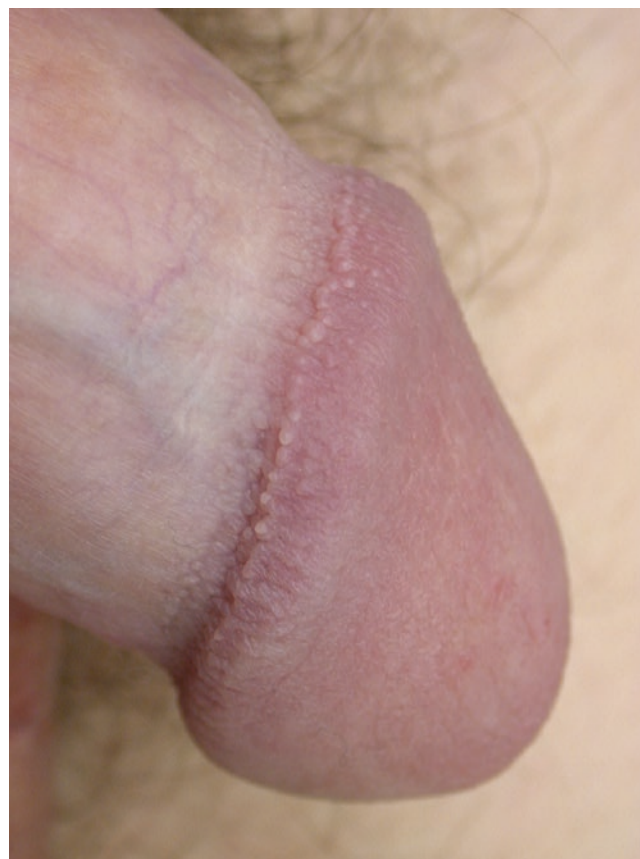

Fig. 6.1 Complete single row of pearly penile papules

warts). Pearly penile papules rarely need to be biopsied but histologically are benign, fibrous neoplasms with an increase in dilated blood vessels surrounded by an increased number of plump, spindle-shaped, and stellate fibroblasts. The histology of pearly penile papules is identical to the histology of angiofibromas, fibrous papules of the nose and acral angiofibromas.

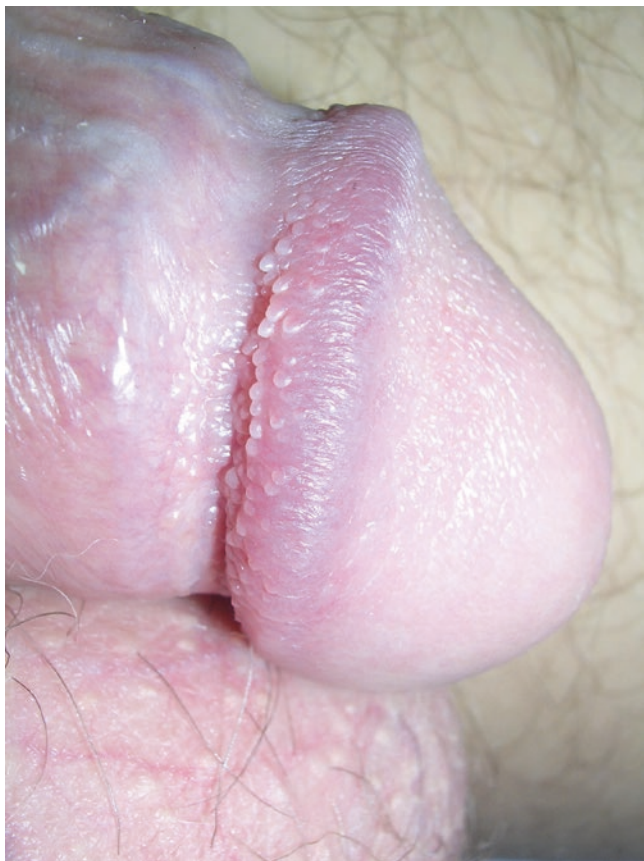

Fig. 6.2 Incomplete double row of pearly penile papules

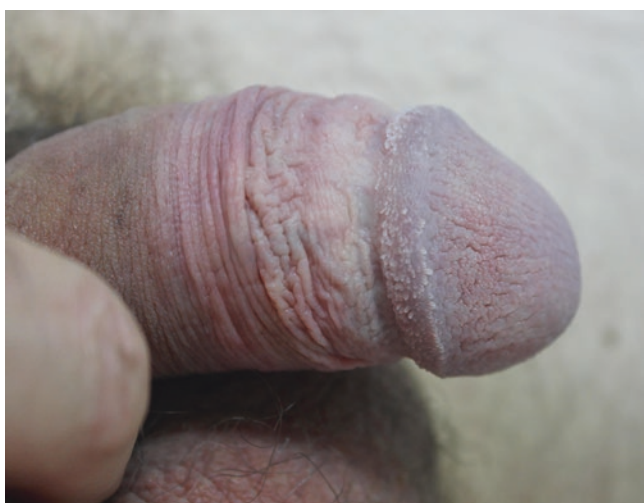

Fig. 6.3 Multiple rows of pearly penile papules around the corona of the glans penis

6.5 Treatment

Reassurance that pearly penile papules are a common, normal variant is important. Pearly penile papules may cause concern at puberty and have been incorrectly treated as genital warts. Treatment of these benign lesions should be discouraged, but patients occasionally request removal of pearly penile papules for cosmetic reasons. Destructive treatments may be both painful and potentially scarring. Destructive treatments described include cryotherapy [5], electrodesiccation, curettage, and surgical excision. Laser treatment with carbon dioxide laser [6], pulsed dye laser [7], Er:YAG laser [8], and fractionated CO₂ laser [9] have all been reported. Laser treatment is claimed to offer an improved cosmetic outcome with minimal complications and discomfort [10].

Pearls

- Pearly penile papules are a common normal variant.
- Patients may confuse pearly penile papules with genital warts, creating considerable anxiety.
- Reassure patients of benign nature of pearly penile papules and try to avoid treatment.

References

1. Hogewoning CJ, Bleeker MC, van den Brule AJ, Voorhorst FJ, van Andel RE, Risse EK, et al. Pearly penile papules: still no reason for uneasiness. *J Am Acad Dermatol*. 2003;49:50–4.
2. Agha K, Alderson S, Samraj S, Cottam A, Merry C, Lee V, Patel R. Pearly penile papules regress in older patients and with circumcision. *Int J STD AIDS*. 2009;20:768–70.
3. Aldahan AS, Brah TK, Nouri K. Diagnosis and management of pearly penile papules. *Am J Mens Health*. 2018;12:624–7.
4. Ozeki M, Saito R, Tanaka M. Dermoscopic features of pearly penile papules. *Dermatology*. 2008;217:21–2.
5. Ocampo-Candiani J, Cueva-Rodriguez JA. Cryosurgical treatment of pearly penile papules. *J Am Acad Dermatol*. 1996;35:486–7.
6. Lane JE, Peterson CM, Ratz JL. Treatment of pearly penile papules with CO₂ laser. *Dermatol Surg*. 2002;28:617–8.
7. Sapra P, Sapra S, Singh A. Pearly penile papules: effective therapy with pulsed dye laser. *JAMA Dermatol*. 2013;149:748–50.
8. Baumgartner J. Erbium: yttrium-aluminium-garnet (Er:YAG) laser treatment of penile pearly papules. *J Cosmet Laser Ther*. 2012;14:155–8.
9. Gan SD, Graber EM. Treatment of pearly penile papules with fractionated CO₂ laser. *J Clin Aesthet Dermatol*. 2015;8:50–2.
10. Maranda EL, Akintilo L, Hundley K, Nguyen AH, Moore KJ, Zullo J, Jimenez JJ. Laser treatment for the treatment of pearly penile papules. *Lasers Med Sci*. 2017;32:243–8.

Ectopic Sebaceous Glands (Fordyce Spots) and Median Raphe Cysts

7

7.1 Definition

Fordyce spots are sebaceous glands of genitalia, not associated with hair follicles (ectopic). Median raphe cysts are uncommon, benign developmental cysts on the midline of the ventral aspect of the penile shaft or glans penis.

7.2 Aetiology

Fordyce spots are common, ectopic sebaceous glands of unknown aetiology. Fordyce spots were originally described on oral mucosa but occur commonly on male genitalia. Sebaceous glands are usually associated with hair follicles, as seen on the face. Fordyce spots of oral mucosa and genitalia are not associated with hair follicles. Typical sebaceous glands associated with hair follicles are seen on fully keratinised skin of the scrotum. Confusion occurs with the term *Tyson's glands*. Tyson's glands open onto the ventral aspect of the coronal sulcus on either side of the frenulum and are involved with smegma production. Histologically Tyson's glands are ectopic sebaceous glands [1]. Median raphe cysts are midline developmental cysts thought to arise from defective embryological closure of the median raphe. They may first appear after trauma or infection, but this association may be coincidental.

7.3 Clinical Features

Genital ectopic sebaceous glands of Fordyce spots are asymptomatic, yellow to white micropapules most commonly on the inner surface of the foreskin in 65% of uncircumcised males (Figs. 7.1 and 7.2). Ectopic sebaceous glands are usually few in number and so often go unnoticed. Occasionally ectopic sebaceous glands occur on the glans penis or are more widespread on the genitalia (Fig. 7.3) [2]. Like pearly penile papules, ectopic sebaceous glands may

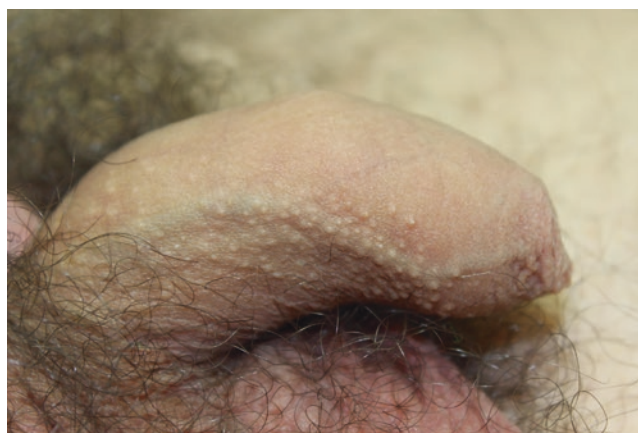

Fig. 7.1 Fordyce spots on the penile shaft and extending onto the outer foreskin

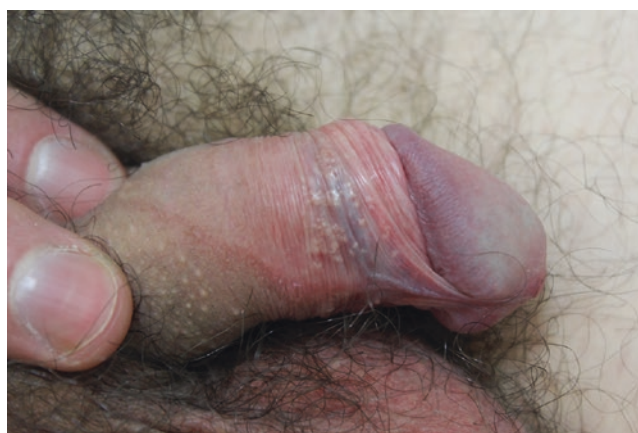

Fig. 7.2 Fordyce spots on the mucosal aspect of the foreskin

cause distress and concern for pubertal males worried about possible genital warts. Ectopic sebaceous glands have been misdiagnosed as molluscum contagiosum [3].

Median raphe cysts usually appear before 30 years of age. Most are asymptomatic and are noted incidentally. Common sites are midline of the ventral aspect of the urethra, glans,

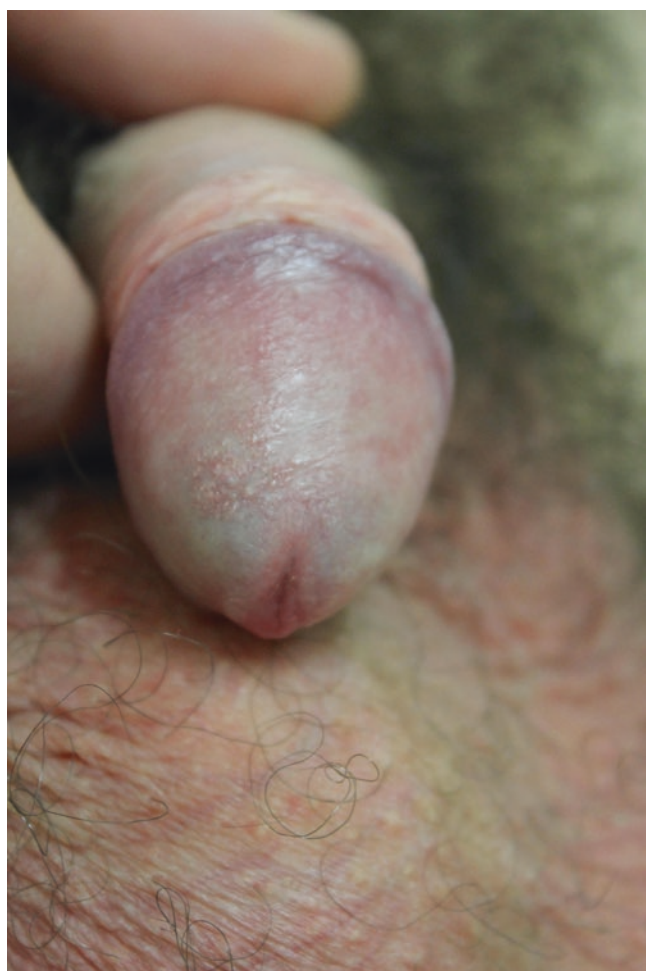

Fig. 7.3 Fordyce spots on the glans penis (an uncommon site)

penile shaft (Fig. 7.4), medial raphe of the scrotum, the perineal raphe or the perianal region. Median raphe cysts contain clear fluid, and may be up to 10 mm in diameter. Rarely median raphe cysts may be pigmented. At puberty, a median raphe cyst may become a cosmetic issue or raise concerns about a possible sexually transmissible infection.

7.4 Diagnosis

Diagnosis of ectopic sebaceous glands (Fordyce spots) is clinical. Differential diagnoses include genital warts and molluscum contagiosum [3]. Even in males who are not sexually active, ectopic sebaceous glands have been wrongly diagnosed as genital warts.

The diagnosis of median raphe cysts is mostly clinical. Excision may be necessary if the cyst is inflamed, for cosmetic

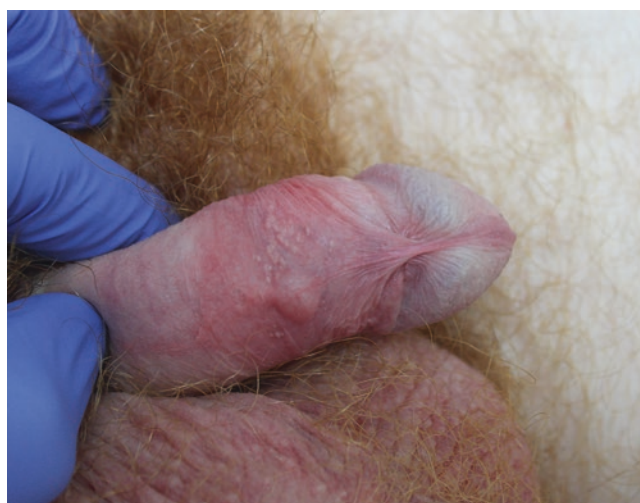

Fig. 7.4 Fordyce spots on the ventral foreskin, with a median raphe cyst

reasons, or if there is concern about a possible sexually transmissible infection (STI) or cancer. Histologically, a median raphe cyst is lined by pseudostratified columnar epithelium or stratified squamous epithelium with occasional mucous glands in the wall. They are not connected with the overlying epidermis.

7.5 Treatment

The treatment of choice for ectopic sebaceous glands (Fordyce spots) or a median raphe cyst is reassurance. Active treatment of ectopic sebaceous glands should be discouraged, as physical treatments may be associated with pain and possible scarring. Surgical treatments reported include curettage and electrodesiccation [4], CO₂ laser [5], and micro-punch excision [6].

If treatment of a median raphe cyst is necessary for cosmetic concern, recurrent infection or concern of a possible cancer, simple excision and primary closure is usually definitive and curative.

Pearls

- Ectopic sebaceous glands (Fordyce spots) are common, asymptomatic micropapules on the inner surface of the foreskin, seen at puberty.
- Treatment of ectopic sebaceous glands (Fordyce spots) is reassurance.
- Median raphe cysts are benign developmental cysts on the midline ventral penile shaft or glans.

References

1. Hyman AB, Brownstein MH. Tyson's "glands." Ectopic sebaceous glands and papillomatosis penis. *Arch Dermatol.* 1969;99:31–6.
2. Massmanian A, Vallis GS, Sempere FJV. Fordyce spots on the glans penis. *Br J Dermatol.* 1995;133:498–9.
3. Piccinno R, Carrel CF, Menni S, Brancalion W. Preputial ectopic sebaceous glands mimicking molluscum contagiosum. *Acta Derm Venereol.* 1990;70:344–5.
4. Chern PL, Arpey CJ. Fordyce spots of the lip responding to electro-desiccation and curettage. *Dermatol Surg.* 2008;34:960–2.
5. Ocampo-Candiani J, Villarreal-Rodríguez A, Quiñones-Fernández AG, Herz-Ruelas ME, Ruíz-Esparza J. Treatment of Fordyce spots with CO2 laser. *Dermatol Surg.* 2003;29:869–71.
6. Pallua N, Stromps JP. Micro-punch technique for treatment of Fordyce spots: a surgical approach for an unpleasant condition of the male genital. *J Plast Reconstr Aesthet Surg.* 2013;66:e8–11.

8.1 Definition

Angiokeratoma of Fordyce is a benign vascular anomaly of ectatic veins presenting as asymptomatic red to purple papules involving the scrotum.

8.2 Aetiology

The aetiology of angiokeratoma of Fordyce is unknown.

8.3 Clinical Features

Angiokeratoma of Fordyce is a relatively common disorder of few to many small, asymptomatic red to purple papules scattered symmetrically over the scrotum, sparing the penile shaft (Figs. 8.1, 8.2, 8.3, and 8.4). An equivalent disease of the vulva is seen in women, involving the labia majora. Occasionally, angiokeratoma of Fordyce may bleed [1, 2]. Although angiokeratoma of Fordyce has no systemic associations, widespread angiokeratomas in the bathing trunk region (periumbilical region, inner thighs, lower back, buttocks) and on the genitalia should lead to suspicion of X-linked inherited angiokeratoma corporis diffusum (Fabry's or Anderson-Fabry disease). Fabry's disease is a lysosomal disorder associated with deposition of glycosphingolipids in vascular smooth muscle cells and other tissues, resulting in significant systemic involvement.

8.4 Diagnosis

Diagnosis of angiokeratoma of Fordyce is clinical. A thrombosed solitary angiokeratoma of Fordyce can mimic a melanoma and cause concern. Differentiation from angiokeratoma corporis diffusum (Fabry's or Anderson-Fabry disease), benign nevi and melanoma is important.

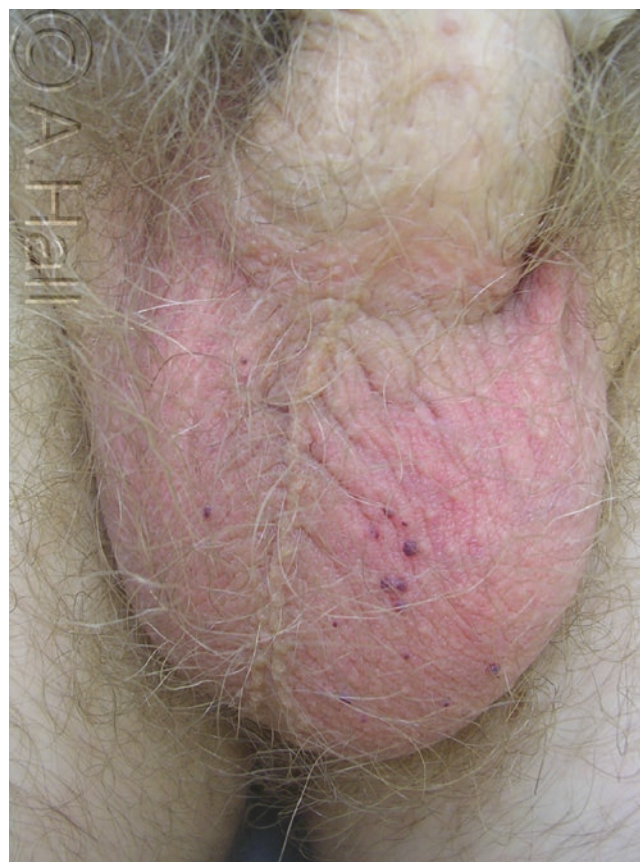

Fig. 8.1 Angiokeratoma of Fordyce appearing sparsely on the scrotum

8.5 Treatment

Reassurance is the treatment of choice. Active treatment should be avoided, but symptomatic bleeding can be easily treated with light electrocautery. If treatment is requested, options include cryotherapy, surgery, or laser treatment [3–5].

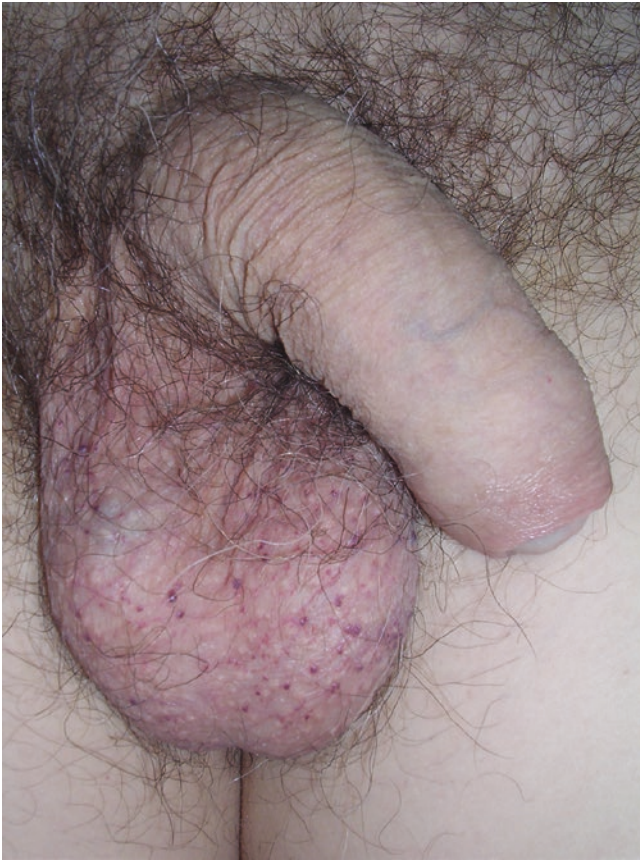

Fig. 8.2 More numerous angiokeratomas of Fordyce

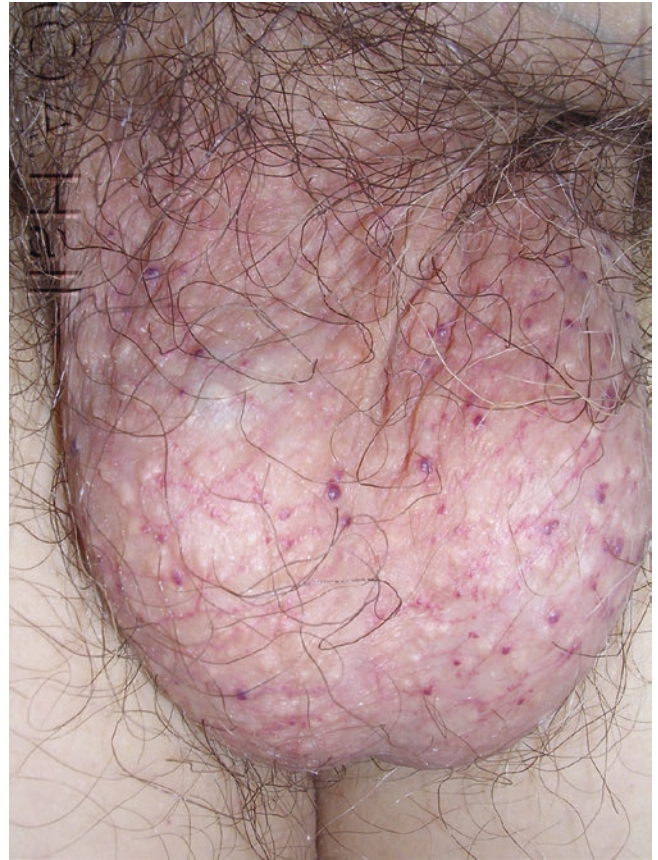

Fig. 8.4 Angiokeratomas of Fordyce

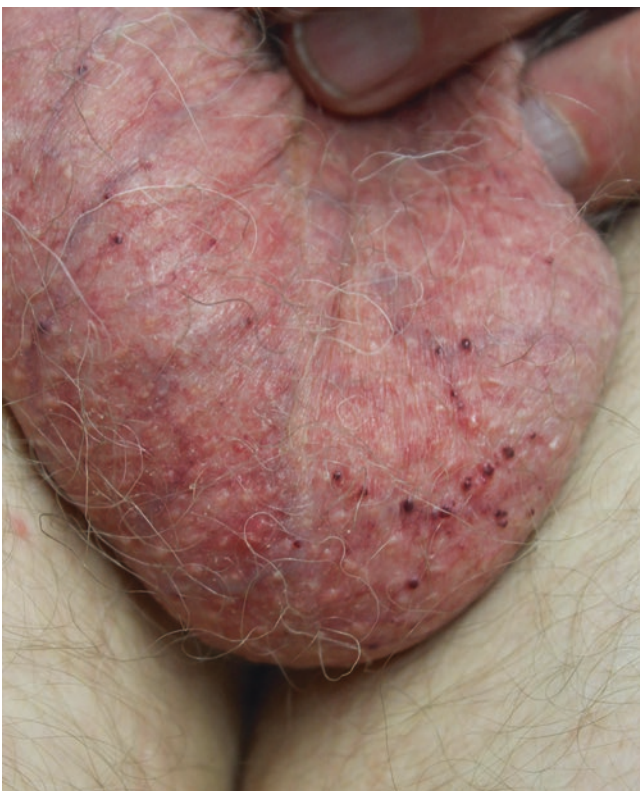

Fig. 8.3 Angiokeratomas of Fordyce

Pearls

- Angiokeratoma of Fordyce is a common, benign anomaly of ectatic veins of the scrotum.
- Thrombosed angiokeratoma of Fordyce can mimic melanoma of the scrotum.
- Preferred treatment of angiokeratoma of Fordyce is reassurance.

References

1. Taniguchi S, Inoue A, Hamada T. Angiokeratoma of Fordyce: a cause of scrotal bleeding. *Br J Urol.* 1994;73:589–90.
2. Trickett R, Dowd H. Angiokeratoma of the scrotum: a case of scrotal bleeding. *Emerg Med J.* 2006;23:e57.
3. Lapidot M, Ad-El D, David M, Azaria R. Treatment of angiokeratoma of Fordyce with pulsed dye laser. *Dermatol Surg.* 2006;32:1147–50.
4. Zeng Y, Zhan K, Xie WL, Lin QZ. Angiokeratoma of Fordyce response to long pulsed Nd:YAG laser treatment. *Dermatol Ther.* 2016;29:48–51.
5. Ibrahim SM. Pulsed dye laser versus long pulsed Nd:YAG laser in the treatment of angiokeratoma of Fordyce: a randomized, comparative, observer-blinded study. *J Dermatolog Treat.* 2016;27:270–4.

Pigmentary Disorders and Color Variation

9

9.1 Definition

Hyperpigmentation, hypopigmentation or depigmentation of many diverse aetiologies may involve genital skin.

9.2 Aetiology

Differences in skin color have shaped history and are still an issue today. Pigmentary disorders of male genitalia may be congenital or acquired, and may be part of a generalised pigmentary disorder or localised to genitalia. Pigmentary disorders may involve the whole genitalia or only a part (focal). Male genitalia vary markedly in color, similar to the wide variation in the color of skin of different people throughout the world. Most variation in color of male genitalia reflects genetic influences. The genitalia of “skin of color” males (Fitzpatrick skin phototypes 4–6) are commonly darker than the color of the rest of their skin (Fig. 9.1). Post-inflammatory hyperpigmentation (PIH) is secondary to many different inflammatory disorders, including dermatitis (eczema), lichen planus, psoriasis and fixed drug reaction. Superficial infections (*eg*, erythrasma, tinea cruris) may produce focal hyperpigmentation. Benign or malignant skin lesions present as focal hyperpigmented papules, nodules, or plaques, including congenital or acquired melanocytic nevi, seborrhoeic keratoses, genital melanotic macules, pigmented genital warts (condyloma acuminata), pigmented basal cell carcinomas (BCCs) and melanoma. Common hypopigmented or depigmenting disorders include vitiligo, lichen sclerosus, and post-inflammatory hypopigmentation. Vitiligo is the most important depigmenting disorder worldwide, affecting approximately 1% of the world’s population.



Fig. 9.1 Normal pigmentation of genitalia of a skin phototype 4 male

9.3 Clinical Features

Males of Fitzpatrick skin phototypes 4 and 5 (light tan to dark brown) may present concerned about darkening of their genitalia at adolescence. Darkening of the penile shaft may

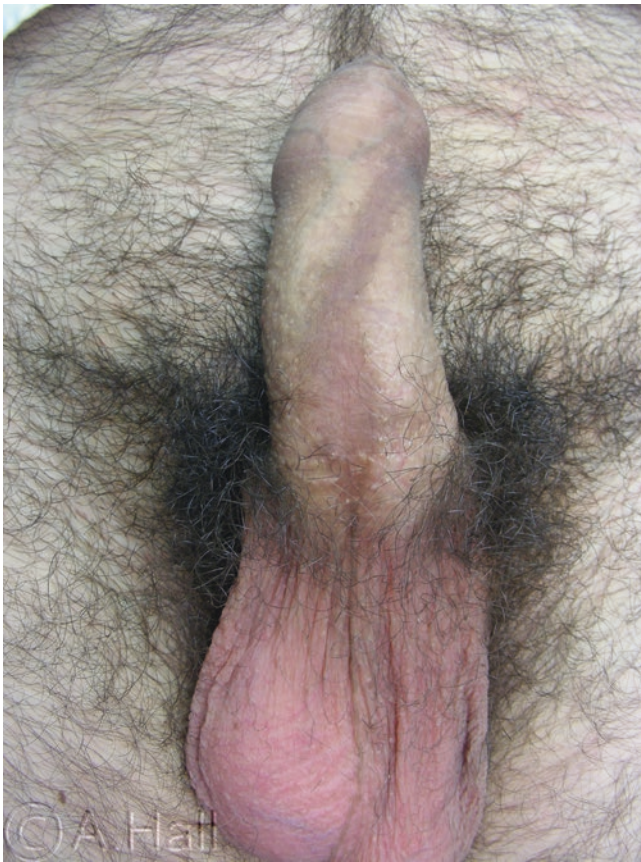

Fig. 9.2 Normal variant of a pigmented band of the ventral penile shaft (skin phototype 4 male)

be continuous with the medial raphe of the scrotum (Fig. 9.2). Flat epidermal nevi of the penile shaft may have a similar appearance and cause concern. Males with Fitzpatrick skin phototype 1 (red or ginger hair with freckling who sunburn easily and are unable to tan) may be concerned about asymptomatic redness of their scrotum (Fig. 9.3). This is a common variant, different from symptomatic “red scrotum syndrome,” in which burning and discomfort (dysaesthesia) may be distressing symptoms [1]. Redness of the scrotum is more common in males with facial rosacea [2]. Though many pigmentary disorders are asymptomatic, many have a significant impact on quality of life. Hypopigmented and depigmenting disorders often cause greater distress, with a disproportionate negative impact on quality of life and sexuality. Vitiligo is a major cosmetic issue to “skin of color” patients (Fitzpatrick skin phototypes 4–6) worldwide. Vitiligo may involve only the genitalia resulting in a significant negative impact on quality of life and sexuality.

While genital pigmentary disorders are usually asymptomatic, genital pigmentary disorders may be symptomatic, depending on aetiology. Itching, scaling, burning and discomfort with sexual activity may be reported in different inflammatory diseases that cause post-inflammatory hyperpigmentation. Burning and discomfort (dysaesthesia) are

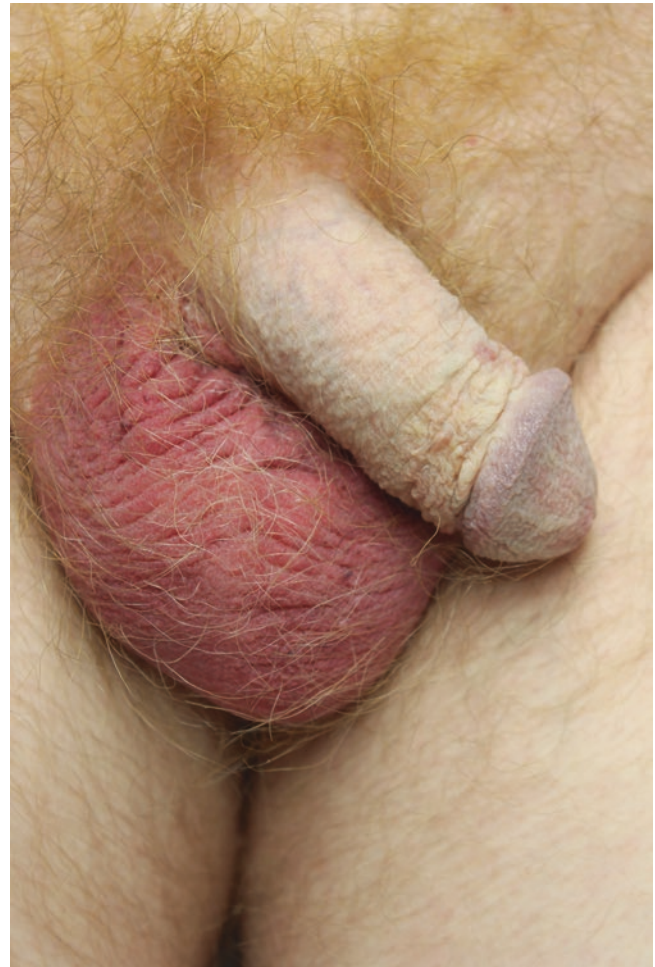


Fig. 9.3 Normal variant asymptomatic redness of scrotum in skin phototype 1 male

reported with “red scrotum syndrome” (male genital dysaesthesia). Genital lichen sclerosis often results in hypopigmentation of the foreskin and glans. Itch, difficulty retracting the foreskin and discomfort with erections or sexual activity are commonly reported with male genital lichen sclerosis.

When assessing any patient with a genital pigmentary disorder, it is important to determine their background general health. Enquire about systemic symptoms such as fever, anorexia, loss of weight and gastrointestinal or urinary disturbance. Careful history taking should reveal any significant past history of inflammatory skin diseases (dermatitis, psoriasis, lichen planus) and autoimmune disease such as vitiligo. Recent changes in medication or commencing a new medication may be significant. A family history of atopic diseases (eczema, asthma, hay fever, urticaria), psoriasis or autoimmune diseases should be noted. Clinical examination includes a full body examination, not just examination of the anogenital region. Note the patient’s background genetic skin color. Look for evidence of a widespread dermatosis (eg, dermatitis, psoriasis, lichen planus, vitiligo). Careful examination of the oral mucosa, hair and nails may reveal evidence of lichen planus.



Fig. 9.4 Genital vitiligo

9.4 Diagnosis

Diagnosis of most pigmentary disorders is mainly clinical. A Wood's (UVA) lamp examination is helpful to detect erythrasma and delineate the extent of depigmentation in vitiligo (Fig. 9.4). As with melanocytic lesions at other body sites, the diagnosis of focal pigmented lesions of the genitals is aided by epiluminescence microscopy (dermoscopy). Skin biopsy may be necessary for focal pigmented lesions of concern, including suspicious nevi or genital melanotic macules to exclude melanoma (Fig. 9.5).

9.5 Treatment

If the pigmentary disorder is a normal variant, reassurance alone is sufficient. Treatment is specific for each acquired pigmentary disorder. Treatment of post-inflammatory hyperpigmentation (PIH) is aimed primarily at treating the underlying inflammatory skin disease. Treatment measures for post-

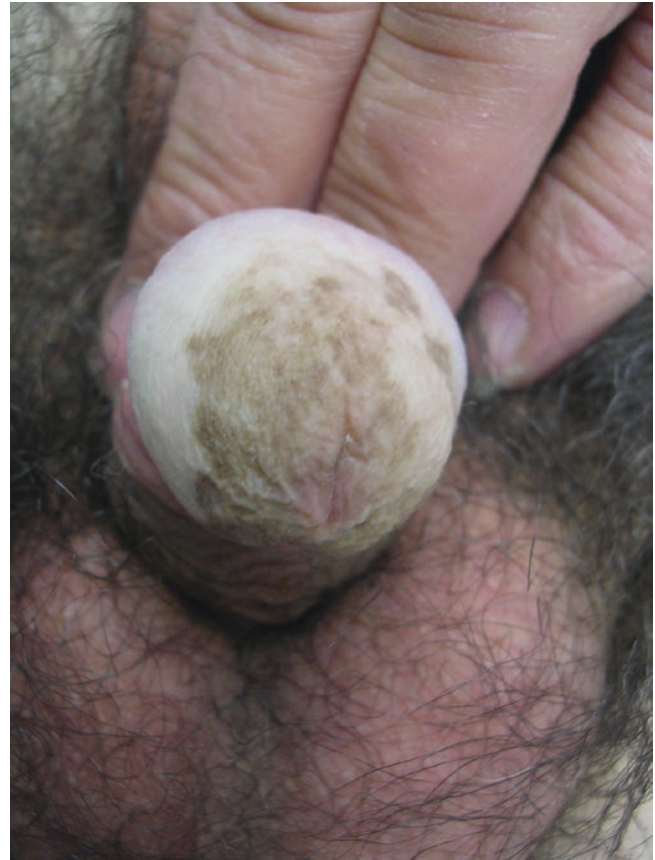

Fig. 9.5 Genital melanotic macules

inflammatory hyperpigmentation (PIH) at other body sites (minimising sun exposure, maximising sun protection and use of depigmenting preparations) have no role in pigmentary disorders of genitalia. If a patient requests treatment for genital vitiligo, a treatment trial with a topical corticosteroid or topical calcineurin inhibitor preparation may be helpful.

Ongoing supportive care for patients with genital pigmentary disorders is important. Recognition and acknowledgment of the significant negative psychosocial and sexual impact of genital pigmentary disorders is paramount in management. Addressing this issue is as important as treating the specific causative disease.

Pearls

- Pigmentary disorders of genitalia often have significant negative psychological and sexual impact on quality of life.
- Awareness of the negative impact of genital pigmentary disorders is essential in management.
- “To cure sometimes, to relieve often, to comfort always” —*Ambroise Paré (French surgeon, 1510–1590)*

References

1. Fisher BK. The red scrotum syndrome. *Cutis*. 1997;60:139–41.
2. Michajłowski I, Sobjanek M, Michajłowski J, Włodarkiewicz A, Matuszewski M. Normal variants in patients consulted in the dermatology clinic for lesions of the male external genitalia. *Cent European J Urol*. 2012;65:17–20.

10.1 Definition

Phimosis is difficulty or inability to easily retract the foreskin (prepuce) over the glans penis.

10.2 Aetiology

Physiologic phimosis is normal at birth and in infancy (Fig. 10.1) [1, 2]. Inability to retract the foreskin in a neonate is due to embryonic adhesions between the inner aspect of the foreskin and the glans (balano-preputial adhesions). Physiologic phimosis usually spontaneously resolves. It is important to distinguish physiologic phimosis from pathologic phimosis. Pathologic phimosis is non-retraction of the foreskin secondary to scarring [3]. A more practical definition of pathologic phimosis is non-retraction of the foreskin extending beyond puberty and of concern to the patient. *Waisting* is the clinical sign of formation of visible tightening or constriction band around the penile shaft on attempted retraction of the foreskin. Waisting is a useful sign of early lichen sclerosus. *Paraphimosis* refers to the situation where the foreskin is fixed in the retracted position resulting in edema of the foreskin and glans [4].

The term *balanitis xerotica obliterans* (BXO) is used in urology for male genital lichen sclerosus of the glans. *Posthitis xerotica obliterans* refers to lichen sclerosus of the glans associated with phimosis but the term *balanitis xerotica obliterans* is more commonly used for lichen sclerosus with phimosis. While *lichen sclerosus with phimosis* is the preferred term, *balanitis xerotica obliterans* (BXO) will probably persist in the urology literature. Pathologic phimosis persisting beyond puberty is nearly always a result of lichen sclerosus, as confirmed by histology of circumcision specimens [5]. Other possible causes of pathologic phimosis include trauma and scarring from forceful retraction of the foreskin.

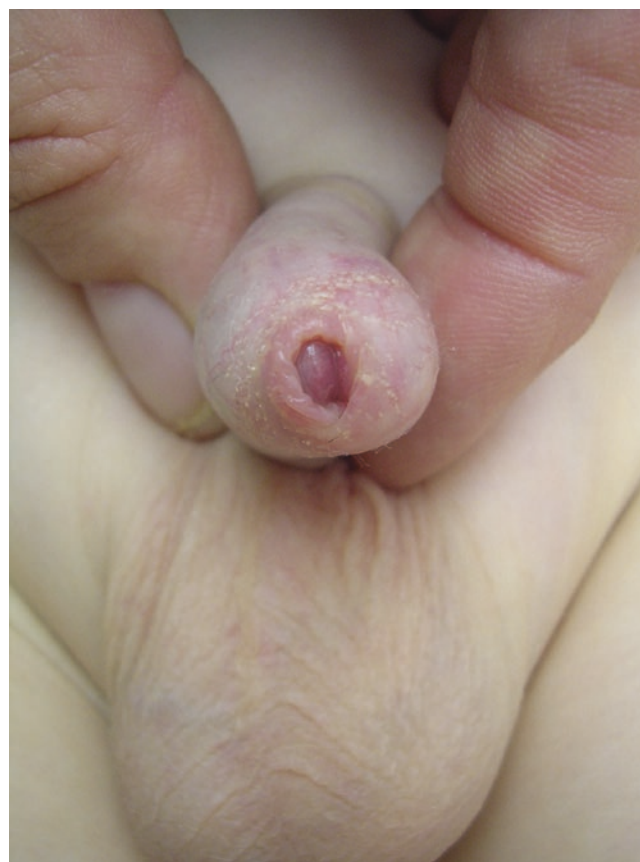

Fig. 10.1 Phimosis in an infant

10.3 Clinical Features

Patients may complain of tightness of the foreskin on attempted retraction. Tearing of the foreskin with erection or with sexual activity may result in pain (dyspareunia) leading to total avoidance of sexual activity. Patients with a very tight

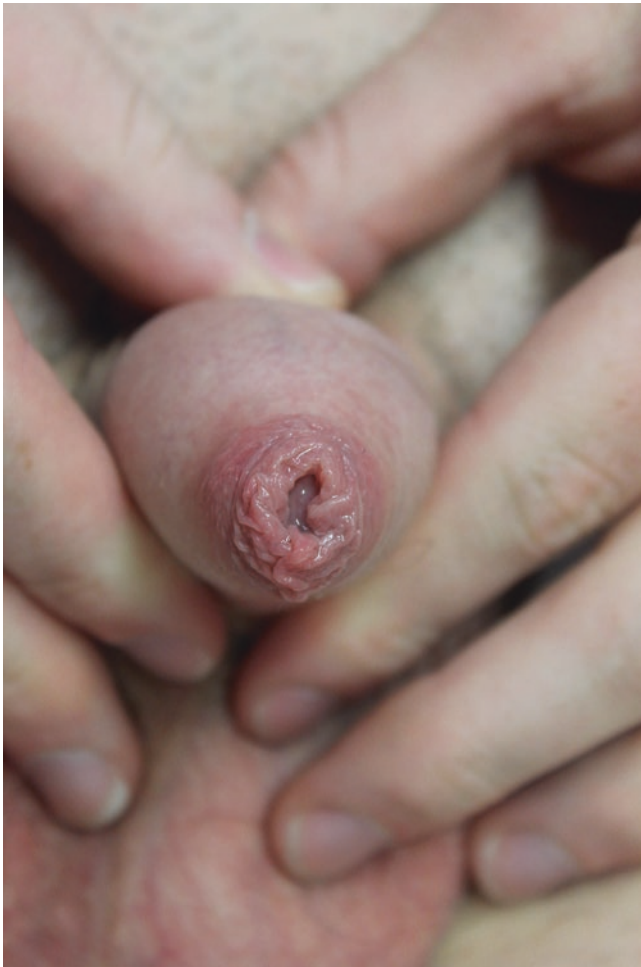

Fig. 10.2 Persisting phimosis in an adolescent male

phimosis might report spraying of their urinary stream. Physiologic and pathologic phimosis are clinically evident when attempting to retract the foreskin. The phimotic foreskin may be partially retractable and may appear normal in the resting position or may appear as a white, thickened, inelastic, non-retractile foreskin with a pinhole opening. Telangiectases, purpura, scarring and adhesions across the coronal sulcus may be seen in lichen sclerosis with phimosis. Lichen sclerosis of the glans may involve the urethral meatus with erythema and stenotic narrowing of the meatus (Figs. 10.2, 10.3, and 10.4).

10.4 Diagnosis

Phimosis is diagnosed clinically. Lichen sclerosis of the glans often occurs with a pathologic phimosis. Skin biopsy is not usually needed for phimosis but histological examination of the foreskin specimen at circumcision usually demonstrates lichen sclerosis.

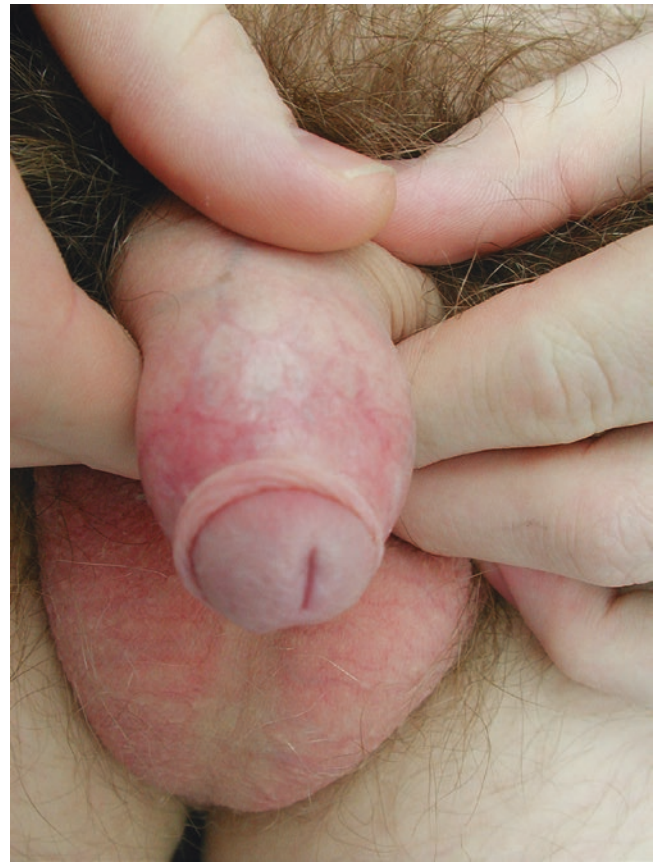

Fig. 10.3 Persisting phimosis in an adolescent male associated with lichen sclerosis

10.5 Treatment

Physiologic phimosis in infants or young boys does not need treatment but parental pressure may be brought to bear. Conservative medical treatment should be tried before circumcision in young boys. Physiologic and pathologic phimosis in young boys is best treated with a topical corticosteroid preparation. A moderately potent topical corticosteroid preparation (Group IV in US classification), such as mometasone furoate 0.1% cream or ointment, applied daily under the foreskin for 4–8 weeks is often effective in relieving the phimosis [5, 6]. No significant adverse effects have been reported with use of topical corticosteroids for phimosis [5]. If medical treatment fails, circumcision is considered. The risks and benefits of circumcision should be openly discussed with parents. Circumcision is associated with risks of haemorrhage, infection, anaesthesia-related events and psychological stress [5]. Preputioplasty is an alternative to circumcision that can be performed under local anaesthesia.

Paraphimosis requires immediate manual reduction, and occasionally surgical relief or circumcision is necessary [4].

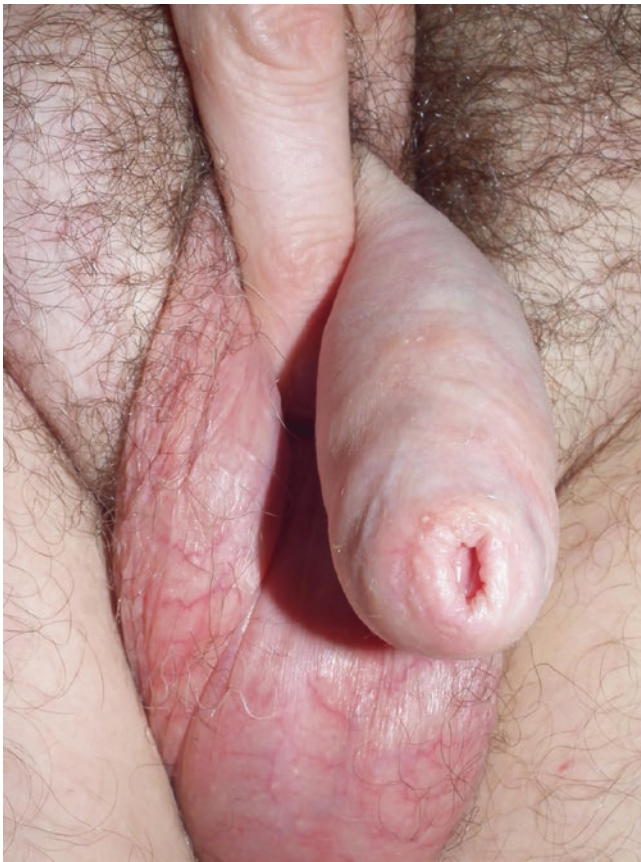

Fig. 10.4 Tight, stenotic phimosis associated with lichen sclerosus

Pearls

- The presence of foreskin is associated with a much higher rate of genital skin disease.
- Pathologic phimosis is non-retraction of the foreskin extending beyond puberty and of concern to the patient. Pathologic phimosis should be considered a medical disease rather than a surgical issue.
- Phimosis should be treated with a trial of topical corticosteroid before circumcision.

References

1. Gairdner D. The fate of the foreskin, a study of circumcision. *Br Med J*. 1949;2(4642):1433–7.
2. Shahid SK. Phimosis in children. *ISRN Urol*. 2012;2012:707329.
3. McGregor TB, Pike JG, Leonard MP. Phimosis--a diagnostic dilemma. *Can J Urol*. 2005;12:2598–602.
4. Hayashi Y, Kojima Y, Mizuno K, Kohri K. Prepuce: phimosis, paraphimosis, and circumcision. *Sci World J*. 2011;11:289–301.
5. Moreno G, Corbalán J, Peñaloza B, Pantoja T. Topical corticosteroids for treating phimosis in boys. *Cochrane Database Syst Rev*. 2014;9:CD008973.
6. Kuehhas FE, Miernik A, Sevcenco S, Tosev G, Weibl P, Schoenthaler M, Lassmann J. Predictive power of objectivation of phimosis grade on outcomes of topical 0.1% betamethasone treatment of phimosis. *Urology*. 2012;80:412–6.

11.1 Definition

Balanitis is non-specific inflammation of the glans penis, with no reference to aetiology. *Balanoposthitis* is non-specific inflammation of the glans penis and foreskin.

11.2 Aetiology

Balanitis and *balanoposthitis* are descriptive terms. Balanoposthitis refers to inflammation of both the glans penis and foreskin (prepuce), and also a clinical sign of non-specific redness of the glans and foreskin. Similarly, balanitis refers to inflammation of the glans alone and a clinical sign of non-specific redness of the glans. Many clinicians attribute redness of the glans and foreskin (balanoposthitis) to candidiasis (“fungal”) but there are many diverse causes of redness of the glans and foreskin. Balanoposthitis is more common than balanitis alone, as the presence of the foreskin creates an intertriginous site (preputial recess, balano-preputial recess or subprepuce) that predisposes to many genital skin diseases. Infective causes of balanitis and balanoposthitis are overemphasised in medical literature because of the great importance of sexually transmissible infections and the ability to easily detect cutaneous microbes. Balanitis and balanoposthitis may be acute or chronic, infective or non-infective, part of a generalised dermatosis or a dermatosis with a predilection for male genitalia. Causes include infections (eg, candidiasis), inflammatory diseases (eg, psoriasis), autoimmune diseases (eg, lichen sclerosus), immunobullous diseases (eg, pemphigoid), irritant factors (eg, irritant contact dermatitis), allergic factors (eg, allergic contact dermatitis), medications (eg, fixed drug eruption), trauma (eg, dermatitis artifacta), diseases of unknown cause (eg, Zoon’s plasma cell balanitis), and neoplasia (eg, penile intraepithelial neoplasia) [1, 2]. The mnemonic “PENIS” (psoriasis, eczema, neoplasia, infections, and scabies) includes many common causes of balanitis and bala-

noposthitis. The expanded mnemonic “RED PENIS” lists important causes of focal redness (macules, papules and plaques) and causes of diffuse redness on male genital skin (balanitis and balanoposthitis):

- R** - Reactive arthritis
- E** - Eczema (dermatitis)
- D** - Drug reaction (fixed drug eruption)
- P** - Psoriasis, Plasma cell balanitis (Zoon’s), Planus (lichen planus)
- E** - Erythroplasia of Queyrat (penile intraepithelial neoplasia)
- N** - Neoplasia (eg, Bowen’s disease, bowenoid papulosis, SCC, extramammary Paget’s disease)
- I** - Infections (candidiasis, genital warts)
- S** - Sclerosus (lichen sclerosus), Scabies, Syphilis

11.3 Clinical Features

Balanitis and balanoposthitis may be asymptomatic or patients may complain of itch, irritation, a burning sensation or pain. Balanitis and balanoposthitis may be associated with scaling, swelling, edema, erosions, ulceration, purpura or scarring. Redness may be absent or difficult to discern in males with darker skin (“skin of color”). Balanitis and balanoposthitis may be part of a generalised dermatosis, so evidence of skin disease at other sites should be sought. Important sites include the scalp (psoriasis, seborrhoeic dermatitis, lichen planus), conchal fossae (psoriasis), oral mucosa (lichen planus, pemphigus vulgaris), nails (psoriasis, lichen planus), palms and soles (psoriasis), elbows and knees (psoriasis), flexures (atopic dermatitis, irritant dermatitis), and trunk (psoriasis, seborrhoeic dermatitis, lichen planus, pemphigoid, pemphigus vulgaris) (Figs. 11.1, 11.2, 11.3, 11.4, 11.5, and 11.6).

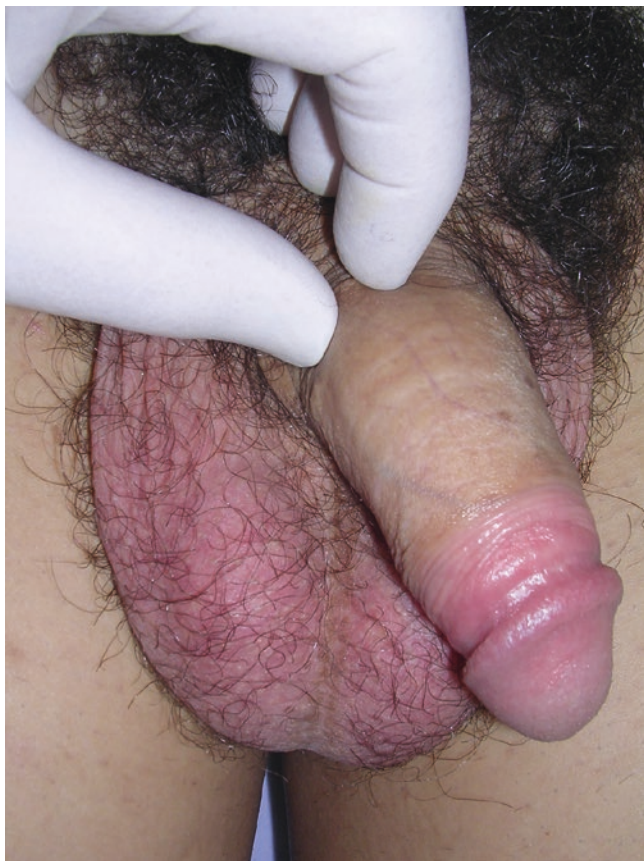

Fig. 11.1 Diffuse balanoposthitis due to irritant dermatitis

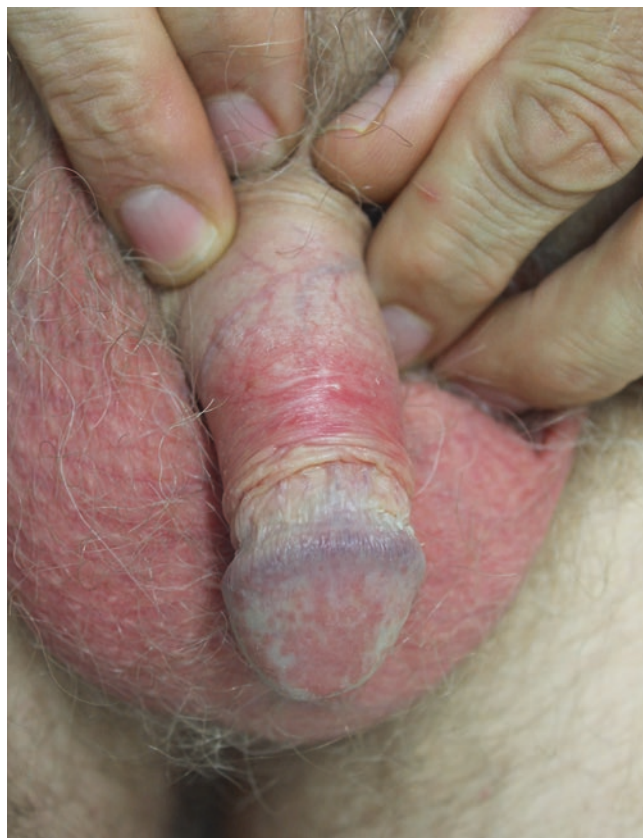

Fig. 11.2 Balanoposthitis due to irritant dermatitis and secondary candidiasis

11.4 Diagnosis

It is important to make an aetiological diagnosis of balanoposthitis or balanitis. Careful history taking and examination are important. The age of the patient, the presence or absence of a foreskin, current general health, past history of atopy, previous skin diseases and other past health problems are all important. A family history of skin disease may be relevant. Enquire about current topical preparations used or previous treatments tried. Current or recent oral medications may be the cause of the balanoposthitis or balanitis. Clinical judgment is needed to make an aetiological diagnosis of balanoposthitis and balanitis that is partly based on probability. The aetiology of balanoposthitis or balanitis may be clinically evident, but selected investigations are often necessary. If infection is suspected, a skin swab for microscopy and culture is appropriate. If the skin is eroded or ulcerated, a skin swab for polymerase chain reaction (PCR) testing to exclude herpes simplex virus (HSV) is essential. Patch testing is nec-

essary if allergic contact dermatitis is suspected. Taking a skin biopsy from a patient with balanoposthitis may help to exclude important diseases, but attempting to make a diagnosis based on histology alone may confuse rather than help. Genital skin biopsy from an uncircumcised male with diffuse balanoposthitis often reveals non-specific spongiosis. Previous histologic descriptions such as “inflammatory non-cicatrical balanoposthitis” are not helpful to clinicians [3]. If there is a solitary focal red papule, patch, or plaque on the glans or foreskin, skin biopsy is essential to exclude in situ squamous cell carcinoma (penile intraepithelial neoplasia) or early invasive squamous cell carcinoma (SCC). The commonest cause of balanoposthitis in a healthy uncircumcised male is irritant dermatitis. Irritant dermatitis is more likely if the patient has a past history of atopy (genetic predisposition to dermatitis, asthma, hayfever, urticaria and food allergies). Candidal balanoposthitis is more likely in an older, obese uncircumcised male with diabetes mellitus, especially with an indwelling urinary catheter.

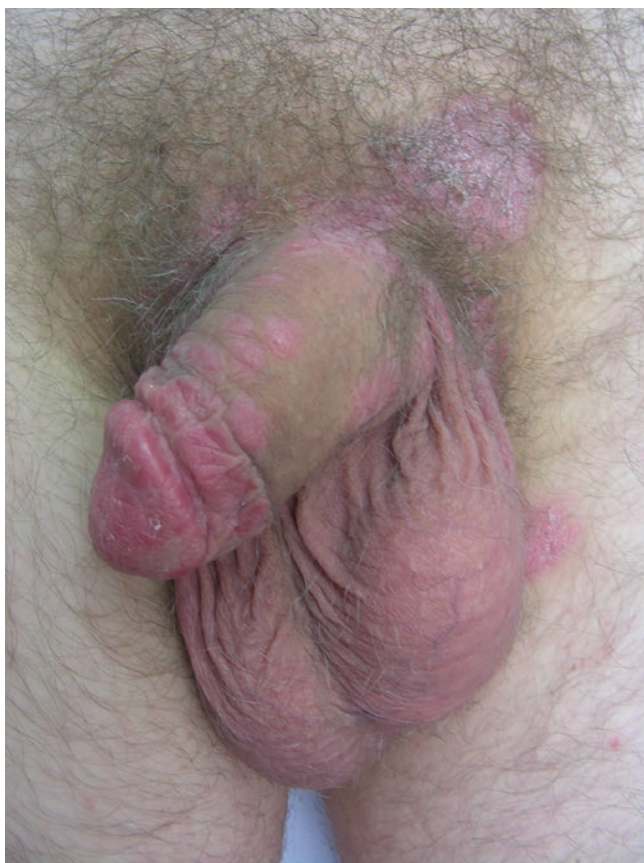

Fig. 11.3 Psoriasis as balanitis

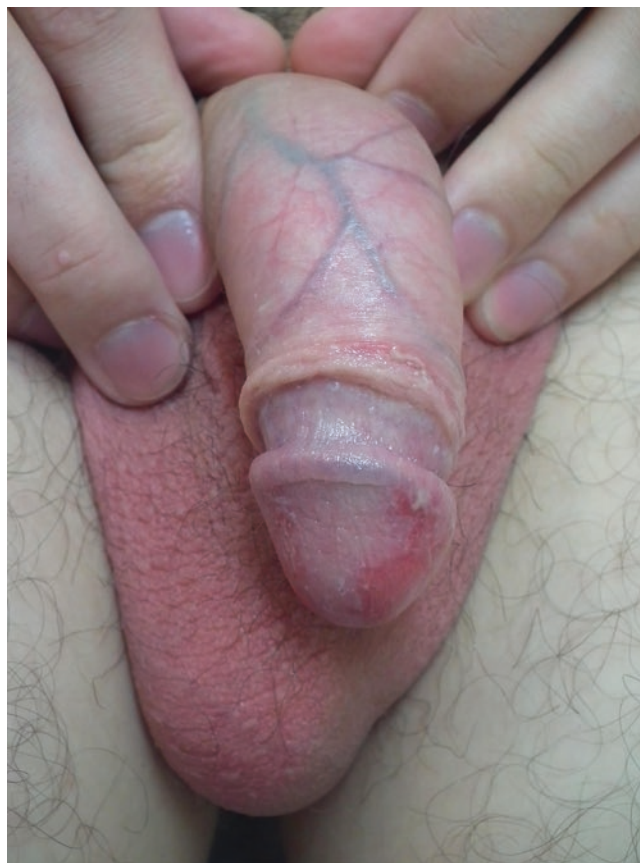

Fig. 11.4 Erosive lichen planus as focal balanitis

11.5 Treatment

Once an aetiological diagnosis of balanitis and balanoposthitis has been made, treatment should be directed at the cause, if possible. Avoid assuming that balanoposthitis is candidiasis and implementing empiric treatment with an imidazole cream. Irritant dermatitis is more common than candidal balanoposthitis. Treatment of genital irritant dermatitis is the same for treatment of irritant dermatitis at other body sites. Attempt to remove irritant factors (soap, friction, sweat, urinary incontinence), cease use of any unnecessary topical applications, encourage use of a moisturiser after washing and a lubricant for sexual activity. A mild-potency topical corticosteroid preparation (*eg*, 1% hydrocortisone cream) (US Category VII) is often adequate.

If there is a poor response to 1% hydrocortisone cream, short-term use of a medium-potency topical corticosteroid (US Category IV) is often effective. The combination of a low-potency topical steroid with topical imidazole cream (*eg*, 1% hydrocortisone with 1% clotrimazole cream) is beneficial for irritant dermatitis with secondary candidiasis. Topical calcineurin inhibitors (pimecrolimus, tacrolimus) are alternatives to topical corticosteroids but may cause irritation on genital skin. Follow-up is important to assess response to treatment. Poor response to treatment necessitates a review of compliance with treatment and a review of the diagnosis.

Treatment of other genital diseases causing balanoposthitis and balanitis is based on making an aetiological diagnosis and will be discussed in the relevant chapter.

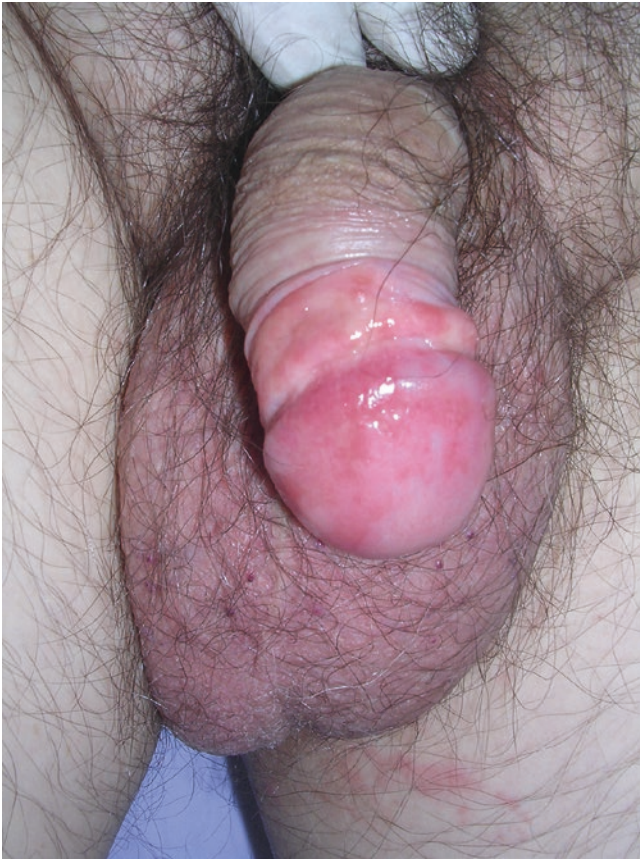

Fig. 11.5 Plasma cell (Zoon's) balanitis as diffuse balanoposthitis

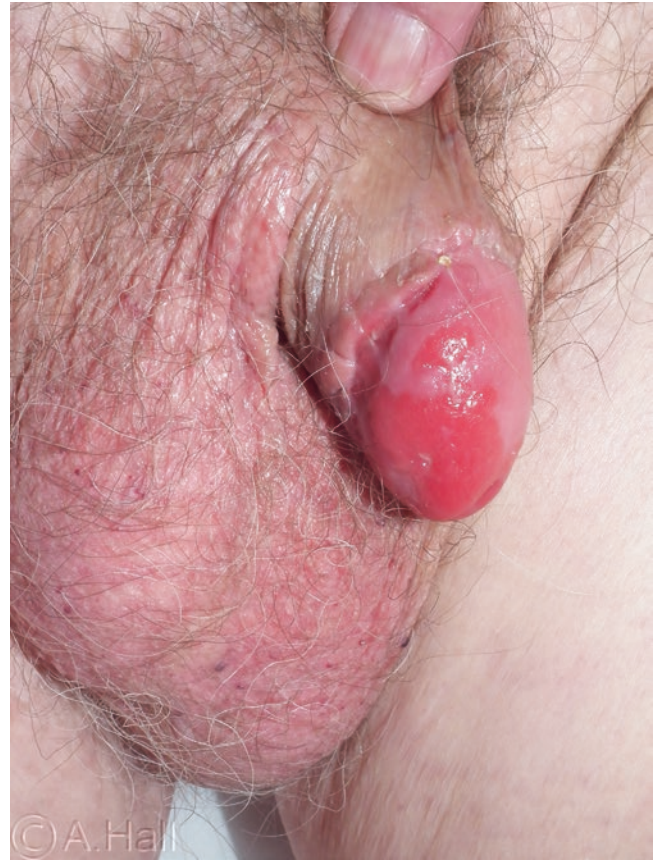

Fig. 11.6 Penile intraepithelial neoplasia (erythroplasia of Queyrat) as balanitis

Pearls

- Balanoposthitis and balanitis are clinical signs, not aetiologic diagnoses.
- Attempt to make an aetiologic diagnosis of balanoposthitis or balanitis before commencing treatment.
- “Errors in judgment must occur in the practice of an art which consists largely of balancing probabilities”—*William Osler*

References

1. Edwards SK. European guideline for the management of balanoposthitis. *Int J STD AIDS*. 2001;12(Suppl 3):68–72.
2. Edwards S. Balanitis and balanoposthitis: a review. *Genitourin Med*. 1996;72:155–9.
3. Alessi E, Coggi A, Gianotti R. Review of 120 biopsies performed on the balanopreputial sac. From Zoon's balanitis to the concept of a wider spectrum of inflammatory non-cicatrical balanoposthitis. *Dermatology*. 2004;208:120–4.

12.1 Definition

Intertriginous sites are where skin surfaces are apposed. Many skin diseases occur in or involve intertriginous sites. Inflammatory intertriginous dermatoses are often grouped together as *intertrigo*.

12.2 Aetiology

Host factors predisposing to intertriginous dermatoses include obesity, diabetes, sweating, friction, occlusion and urinary or faecal incontinence. The presence of a foreskin (being uncircumcised) is the most important factor for intertriginous dermatoses of male genitalia. Intertriginous dermatoses may be genetic or acquired, infective or non-infective, may have a predominantly intertriginous distribution or may be part of a generalised dermatosis. Intertriginous dermatoses are more commonly seen in immunocompromised patients and in people with difficulty attending to personal care such as immobility, dementia, psychiatric disorders or homelessness.

Causes of intertriginous dermatoses are extensive:

- Inflammatory diseases (eg, irritant dermatitis, flexural psoriasis) (Figs. 12.1 and 12.2)
- Yeast infections (eg, candidiasis) (Figs. 12.3 and 12.4)
- Fungal infections (eg, tinea cruris) (Fig. 12.5)
- Bacterial infections (eg, erythrasma)
- Sexually transmissible diseases (eg, condyloma acuminata)
- Genetic diseases (eg, Darier's disease, Hailey-Hailey disease)
- Immunobullous diseases (eg, pemphigus erythematosus, pemphigus vegetans)
- Hidradenitis suppurativa
- Granulomatous disorders (eg, cutaneous Crohn's disease)
- Pigmentary disorders (eg, acathosis nigricans, vitiligo)

- Langerhans histiocytosis
- Neoplastic disorders (eg, extra-mammary Paget's disease) (Fig. 12.6)

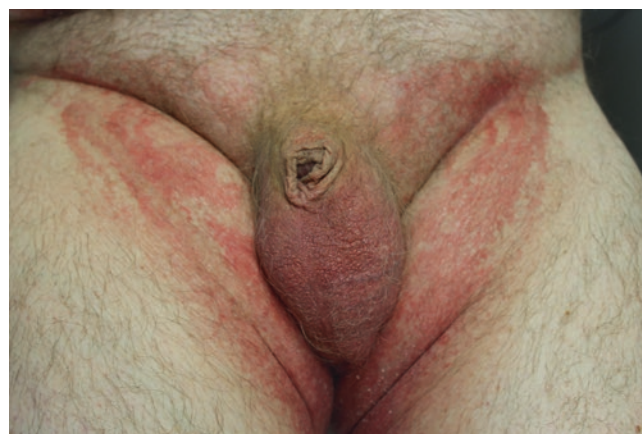

Fig. 12.1 Irritant dermatitis

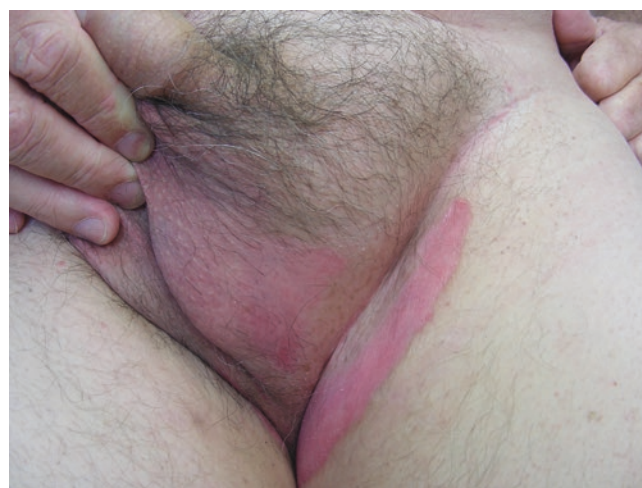

Fig. 12.2 Inverse psoriasis

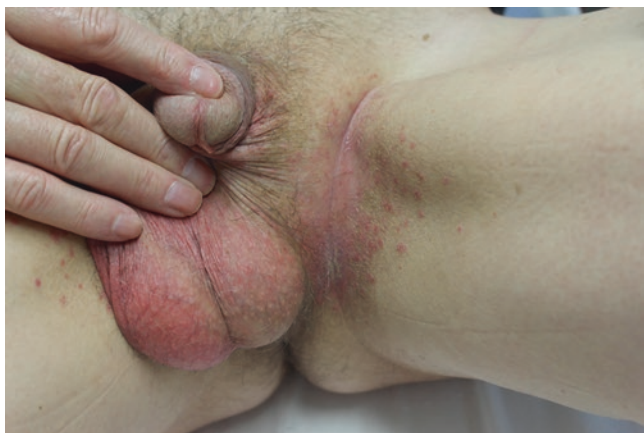

Fig. 12.3 Candidiasis

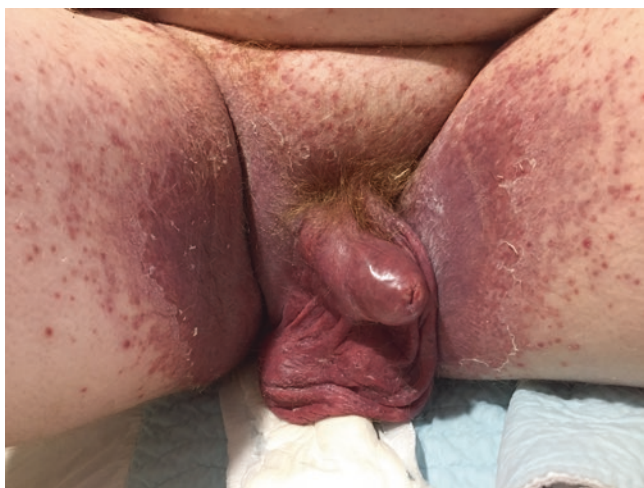

Fig. 12.4 Severe irritant dermatitis with secondary candidiasis

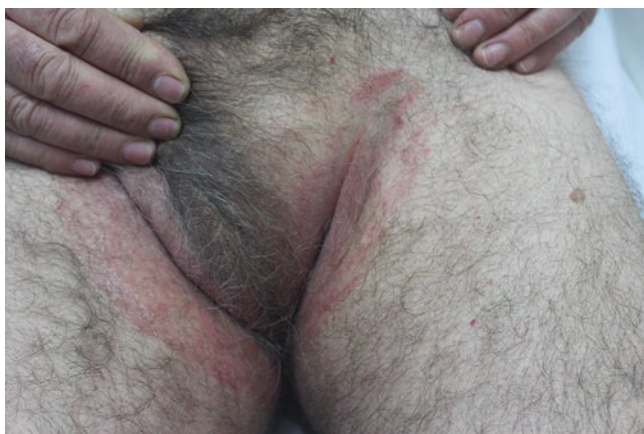

Fig. 12.5 Tinea cruris

12.3 Clinical Features

Intertriginous sites include axillae, submammary region, under a pendulous abdominal “apron,” groins, natal cleft, perianal and perineal regions, beneath the foreskin (preputial recess, balano-preputial recess, or subprepuce) and interdigital spaces. Common symptoms of intertriginous dermatoses include itch, discomfort, irritation or weeping. Redness, fissuring and maceration are common signs of intertriginous dermatoses of the groins (inguino-scrotal region), natal cleft, perineal and perianal regions. Scaling is less apparent or absent in intertriginous sites, whereas lichenification (thickening due to rubbing or scratching) is common. Erosions or bullae may be seen. Sometimes the only complaint is of color change (eg, acanthosis nigricans). Intertriginous dermatoses may become secondarily infected with bacteria (impetiginization), leading to crusting. Secondary infection with candida may produce satellite papules or pustules. Symmetrical distribution is characteristic of most inflammatory intertriginous dermatoses. Intertriginous dermatoses of groins, natal cleft, perineum and perianal regions may be continuous with disease of genitalia (eg, inverse psoriasis) or may spare genital skin (eg, tinea cruris). A full examination for skin disease at other sites is essential, including careful examination of all intertriginous sites. Scaling with an advancing serpiginous (scallop) edge and central clearing of the flat plaque may indicate tinea cruris. Tinea cruris may extend onto the proximal thighs but usually spares the scrotum and penis. Wood’s (UVA) lamp examination of flexures helps exclude erythrasma. Wood’s lamp examination also delineates depigmentation of vitiligo and the extent of hyperpigmented disorders such as acanthosis nigricans. Examination of oral mucosa may reveal lichen planus and examination of appen-

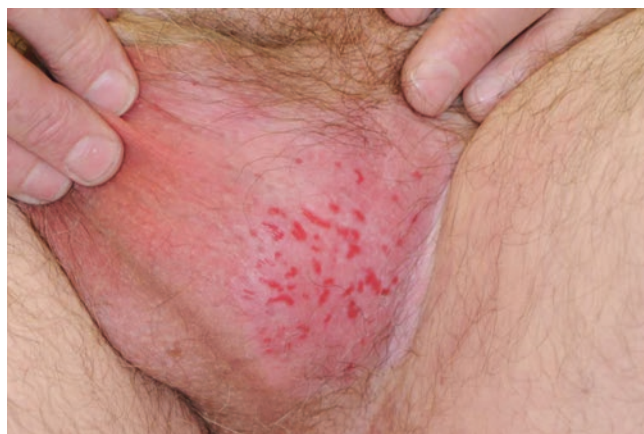

Fig. 12.6 Extramammary Paget’s disease

digeal structures may indicate evidence of lichen planus (hair and nails) or onychomycosis (toenails).

12.4 Diagnosis

Careful clinical examination with selected investigations usually allows an etiologic diagnosis to be made. Skin swabs for microbiology are important if discharge or weeping is occurring. Skin scrapings for fungal microscopy and culture are essential to exclude tinea cruris. A low threshold for skin biopsy is wise for chronic intertriginous eruptions, as clinical appearance is often altered in intertriginous sites. Some inherited diseases (*eg*, Hailey-Hailey disease) have specific histology. It is important not to miss cutaneous intertriginous malignancies such as extra-mammary Paget's disease (*see* Fig. 12.6).

12.5 Treatment

In the primary care setting, a diagnosis of nonspecific "eczema" or "jock itch" of groins is often made leading to empiric treatment with a low-potency (US Category VII) topical corticosteroid combined with an imidazole cream. (This empiric treatment is similar to the management approach for nonspecific balanoposthitis [Chap. 11]). An empiric treatment approach may be successful, but its limitations become apparent when managing patients with more chronic intertriginous dermatoses. Attempting to make an etiologic diagnosis before commencing treatment reduces the likelihood of poor response to empiric treatment.

General treatment measures for intertriginous dermatoses include encouraging the use of a non-soap wash, regular use of a daily moisturiser, minimising skin irritants and avoiding potential allergens found in "over-the-counter" topical preparations. Topical preparations containing perfumes or fra-

grances are more prone to cause allergic contact dermatitis. Recently use of antiseptic baby wipes containing methylisothiazolinone has become popular, leading to an increase in allergic contact dermatitis [1]. Cool soaks are soothing for weeping or crusted intertriginous dermatoses. For more irritated diseases, soaking in a hip (Sitz) bath helps provide relief. Begin treatment with a low-potency (US Category VII) topical corticosteroid cream and cease once the skin appears normal. If there is poor response to a low-potency topical corticosteroid cream, increase to a medium-potency corticosteroid (US Category IV) for short-term use. If an associated candidal infection is present, an imidazole cream combined with a low-potency corticosteroid cream is often effective. Use of an oral antibiotic or oral antifungal may be necessary for significantly infected intertriginous dermatoses. Topical calcineurin inhibitors (pimecrolimus, tacrolimus) are alternatives to topical corticosteroids, but may cause irritation in intertriginous sites. Follow-up is important to assess the response to treatment.

Pearls

- Intertriginous dermatoses of different causes often have similar clinical appearance.
- Take a skin swab from any persistent intertriginous rash, to exclude infection.
- Chronic or resistant intertriginous dermatoses require a skin biopsy.

Reference

1. Boyapati A, Tam M, Tate B, Lee A, Palmer A, Nixon R. Allergic contact dermatitis to methylisothiazolinone: exposure from baby wipes causing hand dermatitis. *Australas J Dermatol*. 2013;54:264–7.

13.1 Definition

Psoriasis is a common, genetically determined chronic inflammatory disease of skin, with symmetrically arranged, red, scaly plaques. Psoriasis is now recognised as a multisystem inflammatory disease.

13.2 Aetiology

Psoriasis is an immunologically driven, multifactorial systemic inflammatory disease with a genetic predisposition. Possible environmental factors include medications, smoking, diet, alcohol, infections and mental stress [1]. The role of the skin microbiome is unclear [2].

13.3 Clinical Features

Chronic plaque psoriasis is the commonest form of psoriasis, resulting in symmetrically distributed, red, scaly plaques involving the scalp, extensor aspects of the elbows and knees and the natal cleft. Inverse or flexural psoriasis involves flexures and intertriginous sites, including the subprepuce (Fig. 13.1). Other clinical forms include guttate psoriasis, pustular psoriasis, palmoplantar psoriasis and erythrodermic psoriasis.

The hallmark cutaneous feature of chronic plaque psoriasis is symmetrical, well-circumscribed, red, scaly plaques over the extensor aspects of elbows and knees, occipital scalp and natal cleft. Patients are most troubled by the appearance of psoriasis, shedding flakes of scale and itch. Genital psoriasis is associated with chronic plaque psoriasis and inverse (flexural) psoriasis but psoriasis may be confined to the genitalia alone. One third of patients with psoriasis report current genital involvement while two thirds of patients with psoriasis experience genital involvement dur-

ing the course of their disease [3, 4]. Genital psoriasis has a very significant negative impact on quality of life and sexual health for many patients [3, 5]. Itch, unsatisfactory cosmetic appearance, pain, dyspareunia, worsening of genital psoriasis after intercourse and decreased frequency of intercourse are complaints of patients with genital psoriasis [3].

Psoriasis may present as scaly, flat papules or a solitary plaque in circumcised men (Fig. 13.2). If uncircumcised,

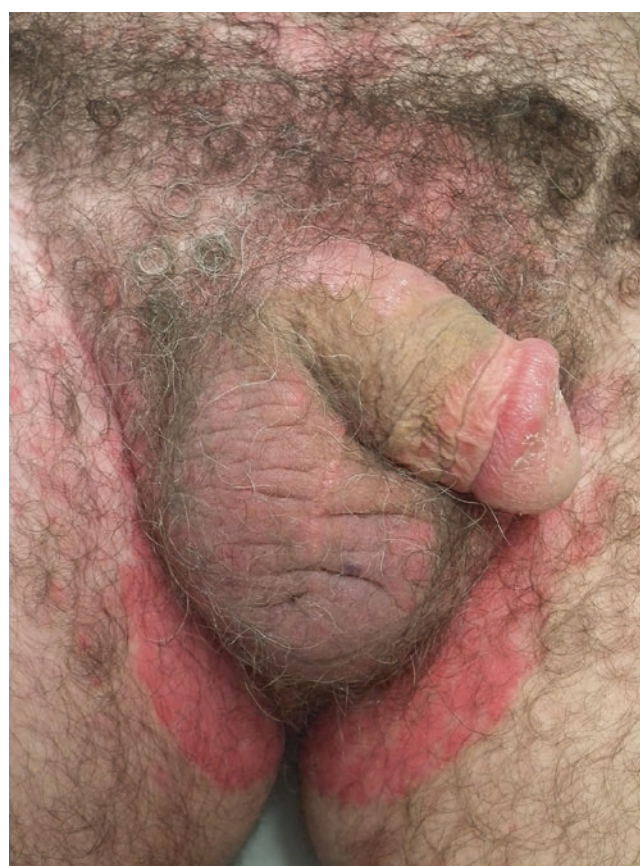

Fig. 13.1 Extensive genital and groin psoriasis

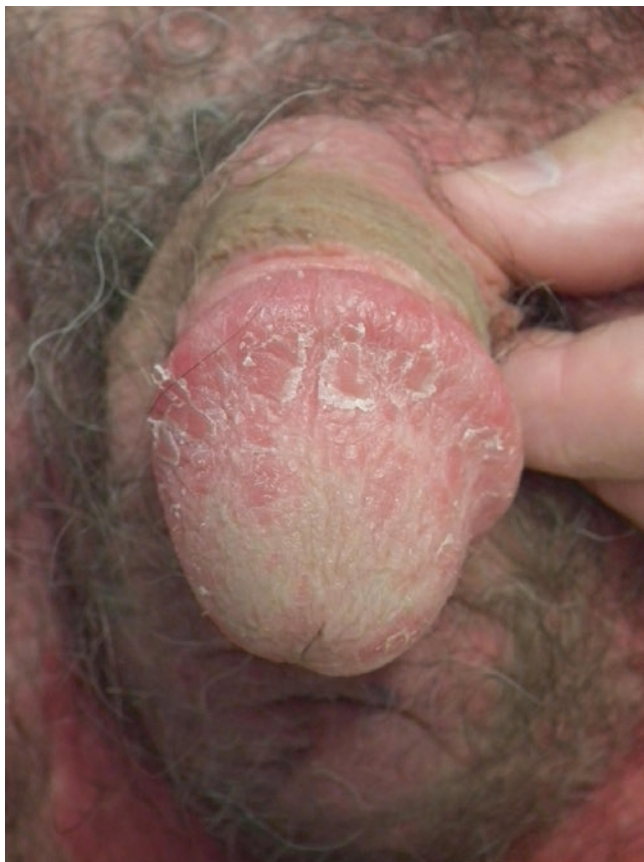

Fig. 13.2 Psoriasis of the glans in a circumcised male

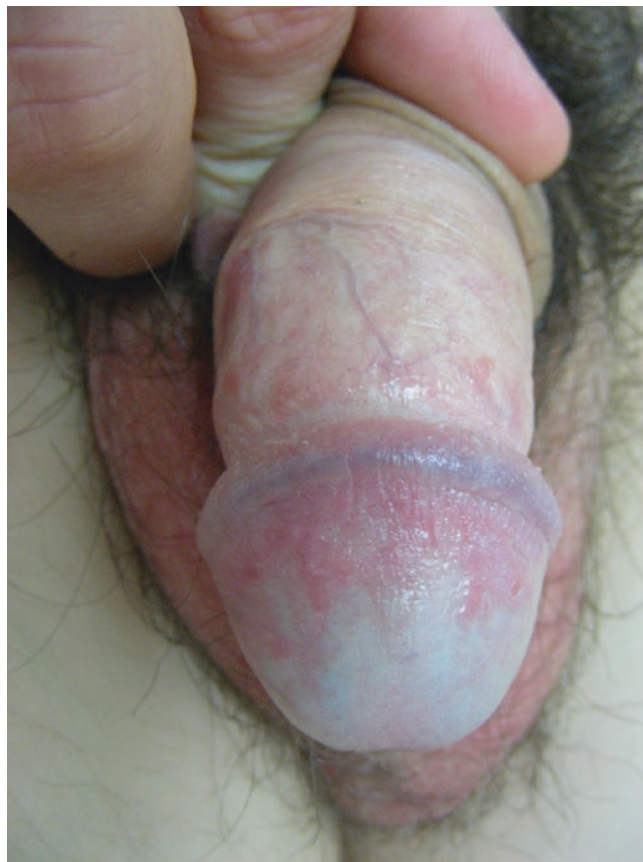

Fig. 13.3 Psoriasis of the glans in an uncircumcised male

psoriasis of the glans may appear as single or multiple red macules (Fig. 13.3). Genital psoriasis may present as balanoposthitis with diffuse redness of the glans and foreskin (Fig. 13.4). Psoriasis of the penile shaft and scrotum usually presents as symmetrical, red, scaly plaques (Fig. 13.5). A sharply well defined, non-scaly patch of erythema of the natal cleft is almost pathognomonic for psoriasis (Fig. 13.6). Scale is absent in the natal cleft (an intertriginous site) but the characteristic red, scaly plaque may be visible at the superior end, overlying the sacrum. Painful fissures may be seen with inverse psoriasis of the groins.

13.4 Diagnosis

Genital psoriasis is diagnosed clinically in setting of chronic widespread, symmetrical plaque psoriasis. Psoriasis of the scalp, conchal fossae, natal cleft and nails (pitting, onycholysis, and onychodystrophy) makes clinical diagnosis easier. Psoriasis confined to the glans of uncircumcised males is more difficult to diagnose. Multiple red macules of genital psoriasis on the glans of an uncircumcised male may be difficult to differentiate from candidiasis, flat genital warts (condyloma acuminata) or bowenoid papulosis. It may be

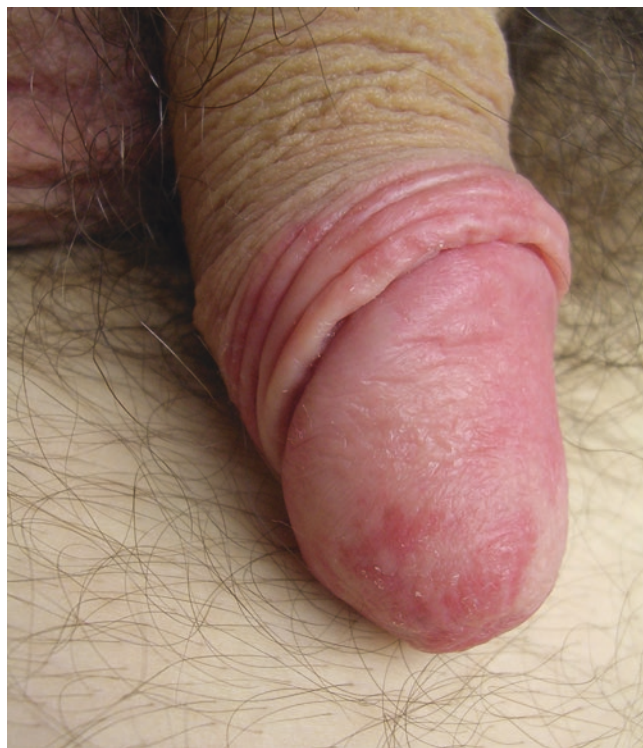

Fig. 13.4 Psoriasis as balanoposthitis

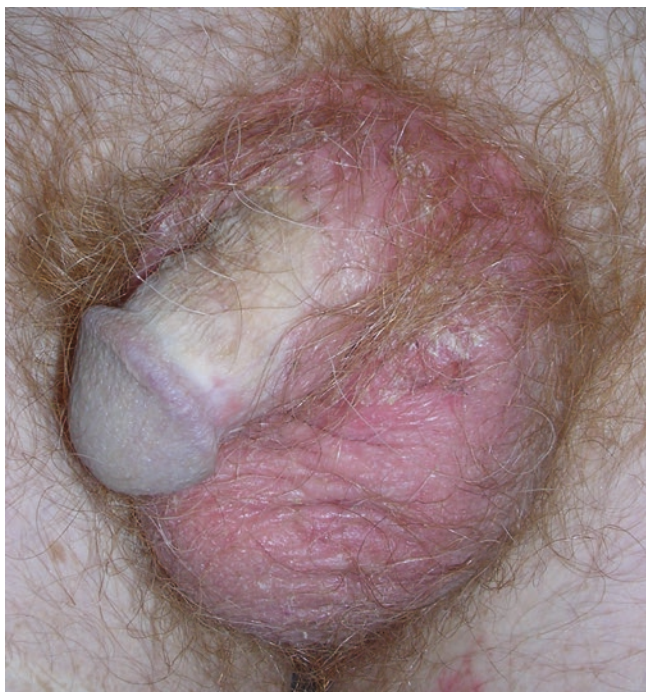

Fig. 13.5 Extensive psoriasis at the base of the penis and scrotum

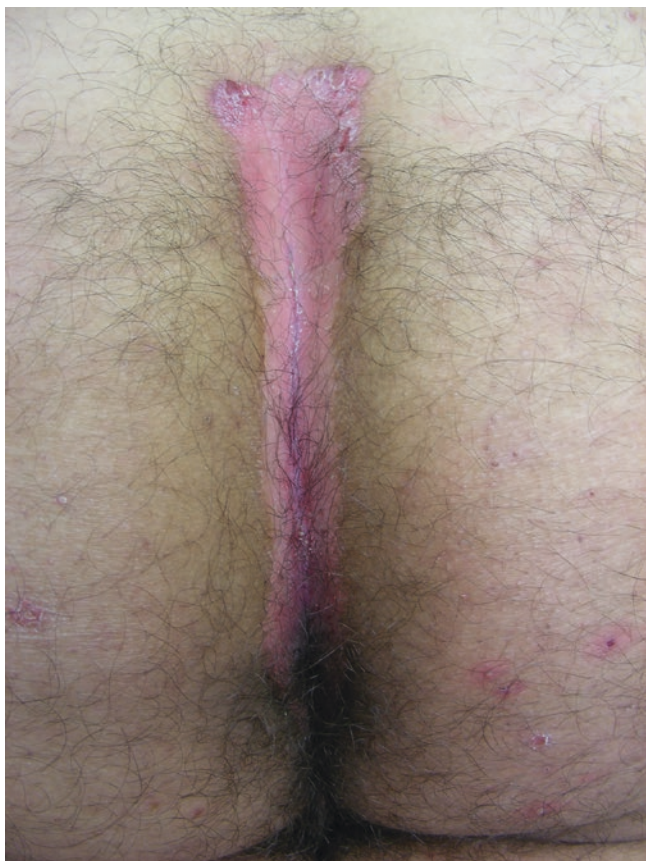

Fig. 13.6 Psoriasis of the natal cleft (intertriginous site). Note scaling superiorly

impossible to differentiate a solitary papule or plaque of psoriasis on the glans from in situ squamous cell carcinoma (SCC) (penile intraepithelial neoplasia) or early invasive SCC. Both in situ SCC (penile intraepithelial neoplasia) and invasive SCC may occur on the glans independent of psoriasis at other sites. The clinical appearance of psoriasis may be further altered by the use of topical treatments. If the diagnosis is uncertain, genital biopsy is important to confirm the diagnosis and exclude in situ squamous cell carcinoma (SCC) or early invasive SCC. If genital biopsy is declined, a practical approach is to cease all topical treatments and review the patient in 6 weeks. If the clinical diagnosis is still uncertain, a biopsy is even more important. If genital biopsy is still declined, a therapeutic trial of a potent topical corticosteroid (US Category I or II) for 6 weeks is a compromise strategy. (This approach is appropriate only if the clinician is confident the patient will attend for review.) If the red papule or plaque still persists after the therapeutic trial with a potent topical corticosteroid preparation, skin biopsy is mandatory.

As psoriasis is a systemic disease, it is important to screen for and exclude associated arthritis, cardiovascular disease, metabolic syndrome (obesity, hypertension, hyperlipidemia, insulin resistance) or mood disorder in the general assessment [6].

13.5 Treatment

Patient education is fundamental for managing a patient with genital psoriasis. Explain to the patient that psoriasis is a genetically determined disease with a chronic, relapsing course. Environmental factors (*eg*, medications, smoking, diet, alcohol, infections, mental stress) are cited as triggers but often no trigger is recognised. Mental distress is usually a consequence of genital psoriasis, rather than stress being the primary cause of psoriasis. As genital psoriasis has a significant negative impact on quality of life and sexual health, enquire about the patient's psychological and sexual well-being [6]. Patients should be aware that the aim of treatment for psoriasis is remission and not cure. Optimism and positive ongoing support are important, as genital psoriasis is often relapsing and any remission may not be sustained.

Attention to general measures should be encouraged, including the use of non-soap wash, minimising irritants and regular use of an emollient (*eg*, soft white paraffin or petrolatum). Emollients are also useful as lubricants for sexual activity. If psoriasis is widespread, systemic treatments (*eg*, methotrexate, acitretin, cyclosporine, biologic or targeted therapies) may clear genital psoriasis. Phototherapy is contraindicated as ultraviolet light is carcinogenic to male genital skin.

Topical corticosteroids are still the mainstay of treatment as they are both effective and well-tolerated. A quicker response is achieved by starting with a moderately potent topical corticosteroid preparation (US Class III–V) applied twice daily for 4 weeks and then reducing to once-daily use on alternate days. Weaning to a mild topical corticosteroid preparation (US Class VII) is wise. Cease use of the topical corticosteroid preparation once psoriasis is cleared. This is a modification of the sequential therapy used for chronic plaque psoriasis [7]. A moderately potent topical corticosteroid (US Class III–V) is used for the “clearance phase,” reducing to a mild corticosteroid (US Class VII) for the “transition phase” [8]. Failure to achieve significant improvement or clearance of genital psoriasis with sequential therapy within 8 weeks necessitates a review of compliance with treatment or re-evaluation of the diagnosis. Poor compliance with treatment is often a result of fear of use of topical corticosteroids by doctors, pharmacists and patients. Overuse of topical corticosteroids for genital psoriasis is uncommon in clinical practice. Instructing patients to use a topical corticosteroid while psoriasis is visible and then to cease use of the topical corticosteroid once psoriasis is clear minimises risk of overuse.

Alternative topical treatments include vitamin D analogues (*eg*, calcipotriol) and topical calcineurin inhibitors (pimecrolimus, tacrolimus). Topical vitamin D analogues are best combined with a mild topical corticosteroid to minimise possible irritation or stinging in the genital or perianal region [9]. A concurrent bacterial or fungal infection may induce the Koebner phenomenon. If co-infection is suspected, adding a topical antibiotic, topical ketoconazole or topical imidazole to the topical corticosteroid may improve the response [9]. Low-strength topical coal tar preparations (*eg*, LPC 3%, salicylic acid 2% in soft white paraffin) with a mild corticosteroid may be useful for difficult perianal psoriasis. Topical retinoids can be an irritant in the genital region so are best avoided.

Pearls

- Psoriasis of the glans may have no scale in uncircumcised men.
- Genital psoriasis often has significant negative impact on quality of life.
- Topical corticosteroids are the most effective treatment for most genital psoriasis.

References

1. Zeng J, Luo S, Huang Y, Lu Q. Critical role of environmental factors in the pathogenesis of psoriasis. *J Dermatol*. 2017;44:863–72.
2. Alexander H, Nestle FO. Pathogenesis and immunotherapy in cutaneous psoriasis: what can rheumatologists learn? *Curr Opin Rheumatol*. 2017;29:71–8.
3. Ryan C, Sadlier M, De Vol E, Patel M, Lloyd AA, Day A, et al. Genital psoriasis is associated with significant impairment in quality of life and sexual functioning. *J Am Acad Dermatol*. 2015;72:978–83.
4. Meeuwis KA, de Hullu JA, de Jager ME, Massuger LF, van de Kerkhof, van Rossum MM. Genital psoriasis: a questionnaire-based survey on a concealed skin disease in the Netherlands. *J Eur Acad Dermatol Venereol*. 2010;24:1425–30.
5. Meeuwis KA, de Hullu JA, van de Nieuwenhof HP, Evers AW, Massuger LF, van de Kerkhof PC, van Rossum MM. Quality of life and sexual health in patients with genital psoriasis. *Br J Dermatol*. 2011;164:1247–55.
6. Takeshita J, Grewal S, Langan SM, Mehta NN, Ogdie A, Van Voorhees AS, Gelfand JM. Psoriasis and comorbid diseases: epidemiology. *J Am Acad Dermatol*. 2017;76:377–90.
7. Koo JY. New developments in topical sequential therapy for psoriasis. *Skin Therapy Lett*. 2005;10(9):1–4.
8. Katz HI, Hien NT, Prawer SE, Scott JC, Grivna EM. Betamethasone dipropionate in optimized vehicle. Intermittent pulse dosing for extended maintenance treatment of psoriasis. *Arch Dermatol*. 1987;123:1308–11.
9. Meeuwis KA, de Hullu JA, Massuger LF, van de Kerkhof PC, van Rossum MM. Genital psoriasis: a systematic literature review on this hidden skin disease. *Acta Derm Venereol*. 2011;91:5–11.

14.1 Definition

Atopic dermatitis (atopic eczema) is a common pruritic, inflammatory skin disease that tends to follow a chronic, relapsing course in children and adults [1].

14.2 Aetiology

Atopic dermatitis is caused by a complex interplay of genetic, immunologic, and environmental factors that result in impaired skin barrier function and dysregulation of the immune system [1]. Patients with atopic dermatitis often have a personal history of other associated atopic diseases (asthma, hay fever, urticaria, and food allergies) as well as a family history of these same atopic diseases.

14.3 Clinical Features

Atopic dermatitis begins in childhood in most patients but may first appear in adulthood. A personal or family history of atopy (inherited tendency to dermatitis, asthma, hay fever, urticaria and food allergies) partly defines atopic dermatitis. Itch, scratching or rubbing are key symptoms. Itch may be intermittent or chronic and may be severe enough to disturb sleep. A tendency to lifelong dryness (xerosis) is common. Neonatal atopic dermatitis tends to involve the face, anterior neck, trunk, and limbs. From infancy to early adulthood, atopic dermatitis presents as red patches or thin plaques with evidence of excoriation, most commonly involving the antecubital and popliteal fossae. More severe atopic dermatitis may be generalised with erythema, xerosis and evidence of scratching (excoriation). Chronic atopic dermatitis exhibits lichenified, thickened plaques with characteristic parallel lines, excoriations and scaling on a background of dry skin. Infectious complications of atopic dermatitis are very significant, including secondary bacterial infections (impetiginisation, cellulitis, septic arthritis,

osteomyelitis, septicaemia) and secondary viral infection, mostly herpes simplex (HSV). Lifelong chronic atopic dermatitis may be complicated by school absence, low self-esteem, anxiety and depression. Chronic genital dermatitis may be the focus and presenting complaint, or part of widespread atopic dermatitis. Chronic genital atopic dermatitis usually involves the scrotum rather than the penis. The perianal region is often also involved.

14.4 Diagnosis

Atopic dermatitis is a clinical diagnosis with no biologic markers to aid diagnosis. A practical definition of atopic dermatitis is itchy skin that begins before 2 years of age with visible flexural dermatitis or a history of involvement of flexures on a background of dry skin. A past history or family history of atopic diseases (dermatitis, asthma, hay fever, urticaria and food allergies) is often seen. In children under 4 years of age, visible dermatitis often involves the cheeks, forehead, and outer limbs rather than flexures. Genital atopic dermatitis usually occurs in a setting of generalised atopic dermatitis or in a patient with a past or family history of atopy so clinical diagnosis is not often difficult (Figs. 14.1 and 14.2). Most ano-genital dermatitis is irritant dermatitis or lichen simplex chronicus. Many of these patients are atopic and may recall a past or family history of atopy.

Investigations are few. Atopic dermatitis may be associated with elevated serum immunoglobulin E (IgE) but elevated serum IgE is not necessary to make a diagnosis. A skin swab is important if atopic dermatitis appears to be secondarily infected with either a bacterium (usually *Staphylococcus aureus*) or a virus (mostly HSV). Taking a nasal swab helps exclude nasal carriage of *Staphylococcus aureus* if atopic dermatitis is recurrently infected. Skin prick testing may be performed to detect immediate-type hypersensitive reactions to specific allergens if considered clinically relevant. Patch testing is necessary if ano-genital atopic dermatitis is complicated by allergic contact dermatitis.

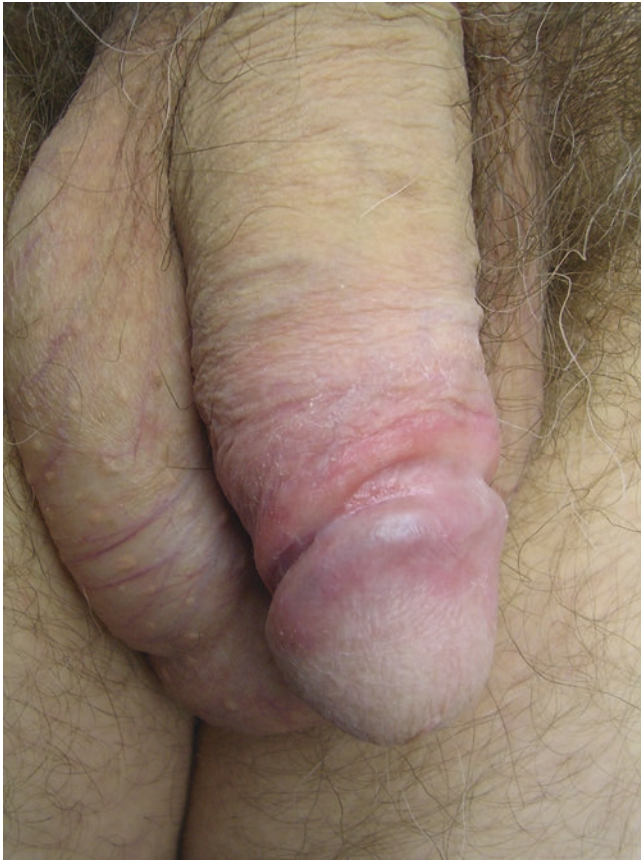

Fig. 14.1 Dermatitis as balanoposthitis in an atopic patient

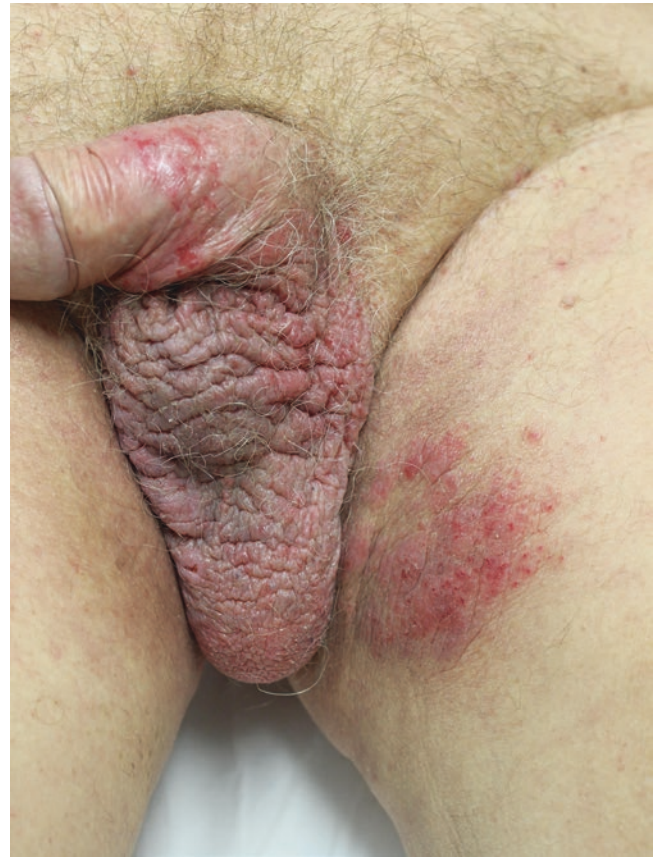

Fig. 14.2 Chronic dermatitis (lichen simplex chronicus) in an atopic patient

14.5 Treatment

It is important to educate the patient about the cause of atopic dermatitis and to outline a plan of management. Explaining to the patient that atopic dermatitis has a genetic basis with an interplay of immune system and environmental factors, is crucial. Patients often blame themselves for their atopic dermatitis, having been told that their atopic dermatitis is caused by stress or dietary allergies. Atopic disease results in great distress, rather than being caused exclusively by anxiety or stress. Food allergies only play a small part in atopic dermatitis in most adults. Patients are helped by the understanding that atopic dermatitis is controlled, rather than cured. (Most atopic patients readily accept that their asthma or hay fever are controlled and not cured). Genital atopic dermatitis may trigger concerns about a possible sexually transmissible infection (STI).

General measures for helping a patient with atopic dermatitis include minimising exposure to skin irritants, use of a non-soap wash and encouraging regular daily use of a moisturiser. Use of an emollient (*eg*, soft white paraffin or white petrolatum) both moisturises genital skin and serves as a

lubricant for sexual activity. Dilute bleach baths (with household hypochlorite solution) may help a patient with recurrently infected atopic dermatitis. Soaking in a cool hip (Sitz) bath may be more practical than use of wet dressings for inflamed or weeping ano-genital dermatitis.

Topical corticosteroids remain the mainstay of treatment for genital atopic dermatitis. Use of a low-potency topical corticosteroid preparation (US Group VII) applied twice daily for 4–6 weeks is usually sufficient to control genital atopic dermatitis (as for irritant dermatitis). If no response is noted within 4–6 weeks, use of a stronger, moderately potent topical corticosteroid preparation (US Group IV–V) for a further 4–6 weeks should be tried. Intermittent use of a lower-potency topical corticosteroid preparation (US Group VII) may be necessary for ongoing control of ano-genital dermatitis. The lower-potency topical corticosteroid preparation may eventually only need to be used as needed.

Topical calcineurin inhibitors (tacrolimus 0.03%, 0.1% ointment; pimecrolimus 1% cream) are alternatives to topical corticosteroids but may cause irritation (stinging, burning) of genital skin. Topical calcineurin inhibitors may be used in a sequential manner with topical corticosteroids.

Remission of atopic dermatitis may be achieved by use of a topical corticosteroid preparation followed by transition to a topical calcineurin inhibitor (preferably tacrolimus 0.03% or 0.1% ointment) to prevent relapse. Low-strength topical coal tar preparations (*eg*, LPC 3%, salicyclic acid 2% in soft white paraffin ointment) combined with a mild topical corticosteroid preparation are useful for perianal dermatitis but should be avoided on genital skin and in the inguinal region because of irritation.

Systemic immunomodulatory agents are indicated when optimal use of topical therapy has failed or when atopic dermatitis has a profoundly negative impact on quality of life (school performance, work, or interpersonal relationships) [2]. A short course of oral prednisone or prednisolone (0.25–0.5 mg/kg per day) for 5–10 days usually helps to regain control of severe atopic dermatitis, allowing maintenance control with standard topical measures. Systemic steroid-sparing agents (azathioprine, methotrexate, cyclosporine, mycophenolate) are used for maintenance systemic therapy for severe, chronic atopic dermatitis. A short period of hospitalisation (with use of wet dressings) may be necessary in desperate situations. Phototherapy is contraindicated for treatment of male gen-

ital atopic dermatitis (as with all genital dermatoses) owing to the known carcinogenic risk of ultraviolet light on scrotal skin. Selected targeted immunotherapy is useful for severe atopic dermatitis that fails to respond to intense systemic therapy.

Pearls

- Many patients with genital irritant dermatitis have an underlying atopic diathesis.
- Topical corticosteroids are treatment of choice for genital dermatitis.

References

1. Eichenfield LF, Tom WL, Chamlin SL, Feldman SR, Hanifin JM, Simpson EL, et al. Guidelines of care for the management of atopic dermatitis: section 1. Diagnosis and assessment of atopic dermatitis. *J Am Acad Dermatol*. 2014;70:338–51.
2. Sidbury R, Davis DM, Cohen DE, Cordoro KM, Berger TG, Bergman JN, et al. Guidelines of care for the management of atopic dermatitis. Part 3: management and treatment with phototherapy and systemic agents. *J Am Acad Dermatol*. 2014;71:327–49.

15.1 Definition

Irritant (contact) dermatitis is a common variant of dermatitis (eczema) triggered by one or more external irritant agents.

15.2 Aetiology

Irritant (contact) dermatitis is more common than allergic contact dermatitis. Endogenous factors predisposing to irritant dermatitis include younger age and history of atopy (genetic predisposition to dermatitis, asthma, hay fever, urticaria, and food allergies). Conversely thinning of skin with aging may make elderly patients more susceptible to irritant dermatitis. Intertriginous and flexural sites are commonly involved. Uncircumcised males are affected more often than circumcised males, as the preputial recess (balano-preputial recess, subprepuce) is an intertriginous site. Scrotal skin is particularly susceptible to irritant dermatitis. Environmental triggers include use of soap, dryness, friction, sweat, humidity and occlusion. Topical preparations (eg, povidone iodine antiseptic skin wash) (Fig. 15.1) and oral medications (eg, oral isotretinoin) (Fig. 15.2) may induce irritant dermatitis. Unlike allergic contact dermatitis, there is no clear induction phase of sensitization to a specific allergen with irritant dermatitis, and no demonstrable elicitation by subsequent exposure to the same allergen on epicutaneous patch testing.

15.3 Clinical Features

Patients with acute irritant dermatitis report itch, redness or burning. There may be a clear history of application of a known irritant to ano-genital skin. Patients may give a past or family history of atopy. Previous irritant dermatitis may be reported. In the acute phase, redness, scaling or weeping

may be evident. Chronic irritant dermatitis results in chronic itch, irritation, stinging, and burning, with variable discomfort and dyspareunia. Red macules, patches, or thin plaques on the glans and the mucosal aspect of the foreskin (balanoposthitis) are cardinal signs of genital chronic irritant dermatitis (Fig. 15.3). Moistness, weeping, or exudate may be evident. Redness is often poorly demarcated (Fig. 15.4),

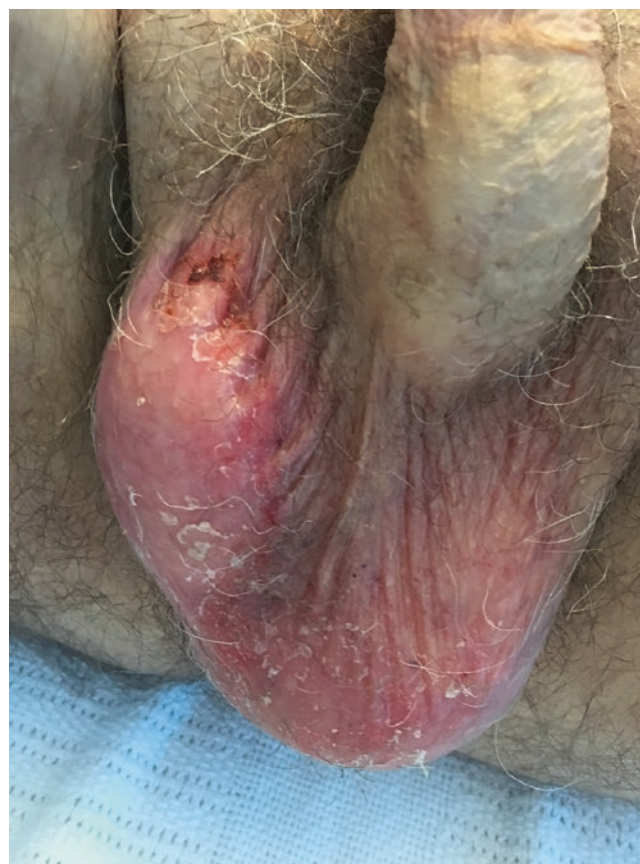

Fig. 15.1 Irritant dermatitis of the scrotum secondary to topical povidone-iodine solution

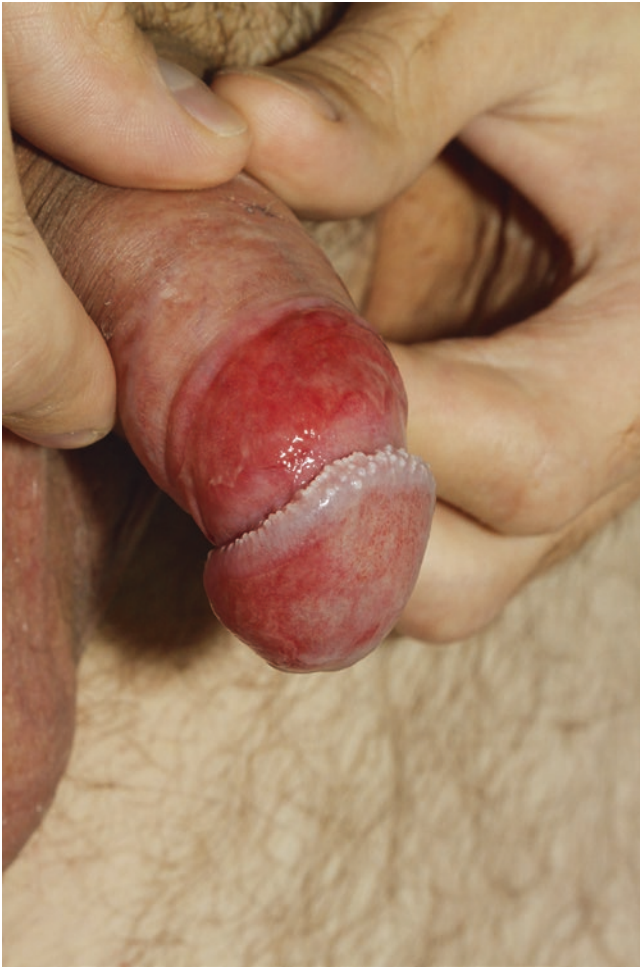

Fig. 15.2 Irritant dermatitis balanoposthitis associated with oral isotretinoin

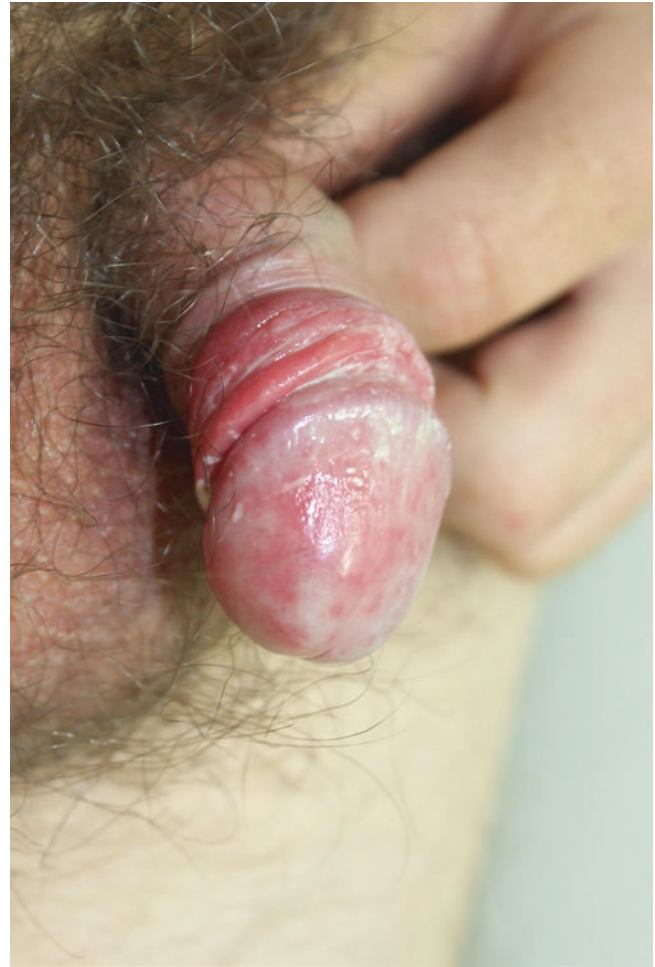

Fig. 15.3 Irritant dermatitis as balanoposthitis

unlike the sharply delineated border of plaque psoriasis. Symmetry of red macules, patches, or thin plaques is characteristic but not absolute. Redness may extend onto the penile shaft, groins and inguino-scrotal region. In chronic irritant dermatitis, red, thick scaly plaques with fissuring may occur on the scrotum. The scrotal skin may develop a cobblestone appearance. Satellite papules on the inner thighs or suprapubic region suggest secondary candidiasis (Fig. 15.5). Irritant dermatitis of the glans and foreskin may be entirely asymptomatic or may result in a profound negative impact on self-esteem and sexuality. Patients with genital irritant dermatitis may fear they have a sexually transmissible infection (STI) or cancer.

15.4 Diagnosis

The diagnosis of genital irritant dermatitis is based primarily on clinical features, probability, and negative skin patch testing (if indicated). Irritant dermatitis is one of commonest

inflammatory male genital skin diseases but is often misdiagnosed as candidiasis or a sexually transmissible infection (STI). A skin swab for microscopy and culture is useful if candidiasis is suspected. Initial screening for an STI may help to reassure an anxious patient, but repeated screening is of little benefit. (Many patients have repeated screening tests in an attempt to confirm a diagnosis of an “STI”). Skin patch testing is indicated if allergic contact dermatitis is suspected and may demonstrate a specific allergen(s). Patch testing in irritant dermatitis is usually negative. Skin biopsy is necessary if in situ or early invasive squamous cell carcinoma (SCC) cannot confidently be excluded.

15.5 Treatment

The most important aspect of management is to explain the diagnosis and reassure an often anxious patient that irritant dermatitis is not an STI or cancer. Recommend ceasing all possible irritants, including “over-the-counter” and

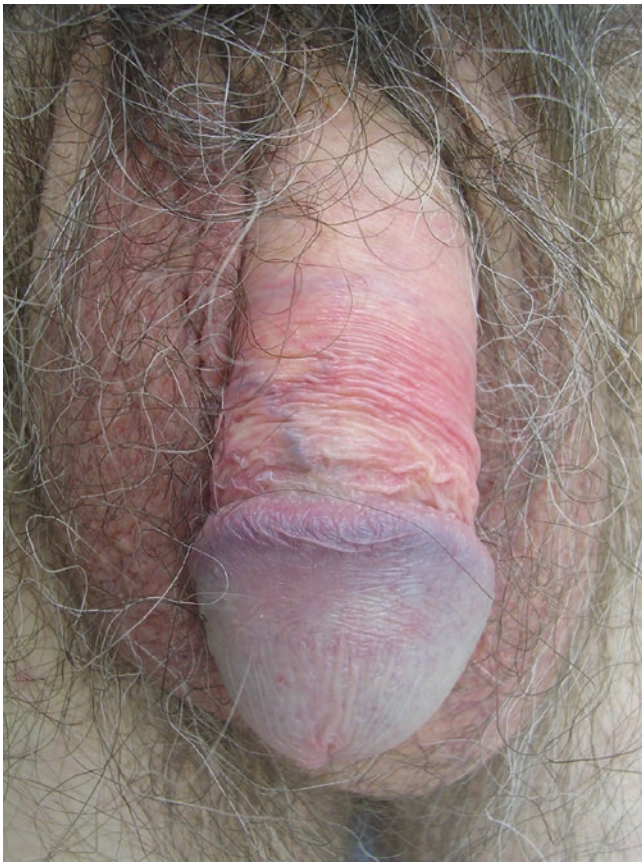

Fig. 15.4 Common presentation of irritant dermatitis as ill-defined erythema

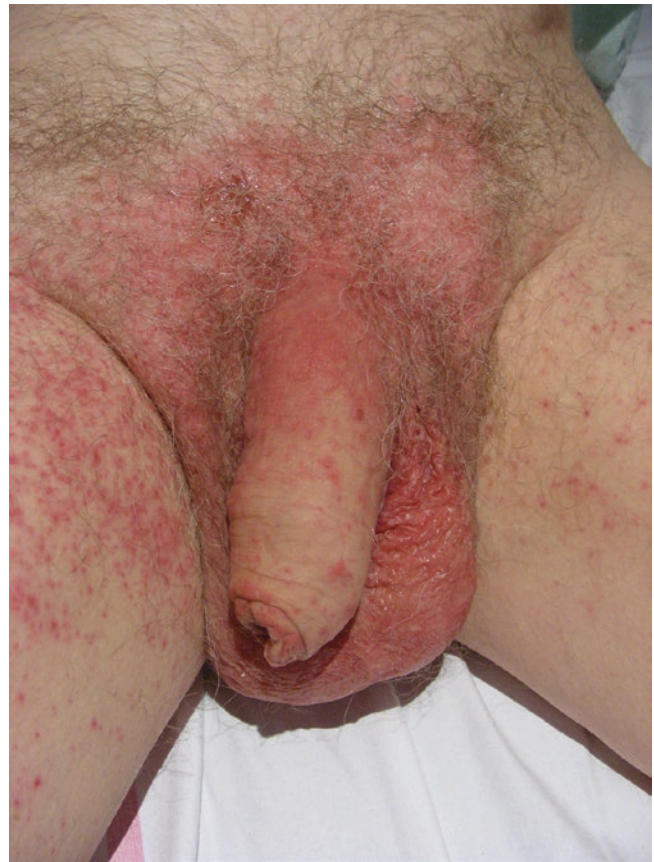

Fig. 15.5 Secondarily infected irritant dermatitis, with extension onto the thighs

prescribed topical treatments. Encourage regular use of a soap substitute and moisturizer, that may also be used as a lubricant for sexual activity. A low-potency topical corticosteroid preparation (US Group VII) applied twice daily for 4–6 weeks is usually adequate to control genital irritant dermatitis. If no response is noted within 4–6 weeks, increase the strength to a moderately potent topical corticosteroid preparation (US Group IV–V) for another 2–4 weeks. Then try reducing to a lower-potency topical corticosteroid (US Group VII), to be used only as needed. A topical imidazole cream may be added if co-existent candidiasis is proven. Topical calcineurin inhibitors are alternatives to topical cor-

ticosteroid preparations but may cause irritation (stinging, burning) on genital skin. Avoid using topical local anesthetic preparations on a long-term basis because of the risk of developing an allergic contact dermatitis.

Pearls

- Irritant dermatitis is the commonest genital dermatosis in uncircumcised males.
- Irritant dermatitis is often misdiagnosed as candidiasis or a sexually transmitted infection (STI).

16.1 Definition

Allergic contact dermatitis is cutaneous inflammation triggered by an external allergen via a delayed (type 4) hypersensitivity immunological reaction.

16.2 Aetiology

Allergic contact dermatitis has two phases: (1) sensitisation or induction phase to a specific allergen and (2) subsequent elicitation of contact dermatitis on re-exposure to the allergen in sufficient concentration. In a sensitised person, elicitation of allergic contact dermatitis develops more quickly on re-exposure to the allergen. Allergic contact dermatitis can be demonstrated clinically by contact patch testing. In contrast, irritant dermatitis (Chap. 15) is cutaneous inflammation triggered by environmental factor(s) but not via a delayed (type 4) hypersensitivity reaction. Cutaneous patch testing should be negative for tested allergens in cases of irritant dermatitis. Allergic contact dermatitis is far less common than irritant dermatitis.

Important host factors for allergic contact dermatitis include genetic susceptibility, atopy (debated), increasing age (associated with accumulation of positive patch test reactions, though these may fade with age) and cultural factors (variation in exposure to known allergens). The anogenital region is commonly affected by allergic contact dermatitis, in part because the anogenital region is exposed to a wide range of allergens. Scrotal skin is particularly susceptible to irritant and allergic dermatitis. Allergens may come in direct contact with the genital skin or may be accidentally transferred by hand. The perianal region may be more susceptible to allergic contact dermatitis than the genitalia [1]. Important allergens associated with ano-genital allergic contact dermatitis include topical medicaments (antibiotics, local anesthetic agents, topical corticosteroids), cosmetics (fragrances), cleansing agents, rubber products,

systemic medicaments and disinfectants [1–3]. Allergic contact dermatitis from condoms may be caused by both rubber and latex [4]. With increasing use of personal hygiene wet wipes applied to the anogenital region, new allergic reactions are being recognised [5]. Methylchloroisothiazolinone and methylisothiazolinone have been reported to be involved in perianal dermatitis resulting from the use of baby wet wipes [6]. Topical preparations such as tea tree oil, which are popularly marketed as natural products, may be associated with allergic contact dermatitis (Fig. 16.1) [7].

16.3 Clinical Features

Allergic contact dermatitis may present as acute dermatitis but progress to chronic dermatitis if exposure to the offending allergen is repeated. Patients with genital allergic contact dermatitis often present early with acute, florid dermatitis. These patients commonly report distress, with intense itch that disturbs sleep. Other symptoms include swelling, pain and weeping, with evidence of redness, weeping exudate, vesiculations, erosions and edema (Fig. 16.2). Patients may recall recent application of a new topical preparation. Some develop more chronic, persistent dermatitis of the scrotum or perianal region. Chronic genital allergic contact dermatitis results in persistent itch with clinical lichenification, excoriations, dryness, and scale (lichen simplex chronicus). Secondary infection of chronic allergic contact dermatitis is not uncommon.

16.4 Diagnosis

Allergic contact dermatitis is diagnosed by careful history-taking and formal patch testing. The gold standard for diagnosis is identification of allergen(s) by patch testing. Clinical judgment is necessary to determine if any identified allergen is relevant for each individual patient with a positive patch

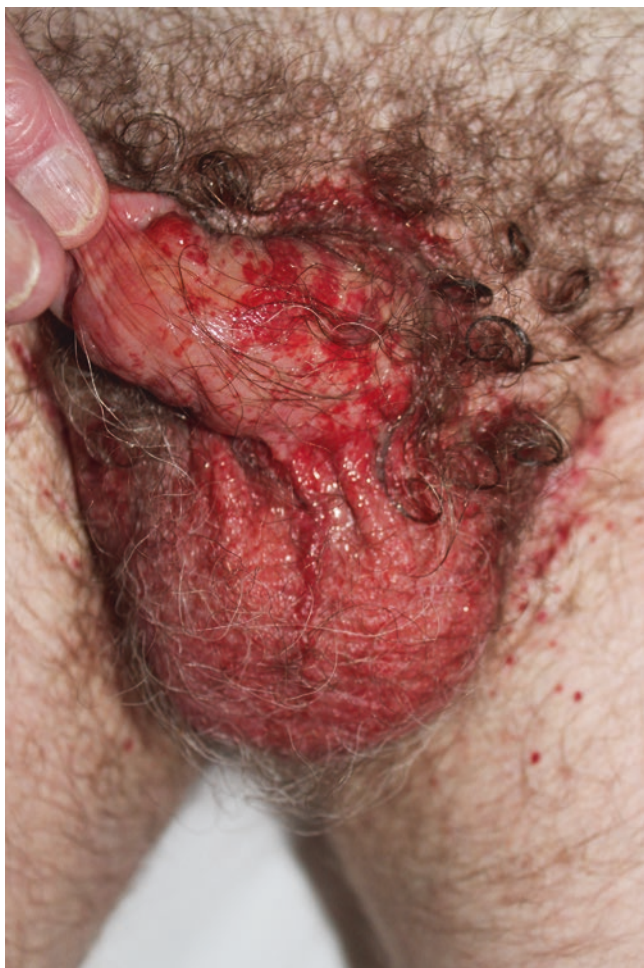

Fig. 16.1 Acute allergic dermatitis due to tea tree oil

test. Any persistent or resistant chronic dermatitis should alert to the possibility of allergic contact dermatitis. Cutaneous patch testing is important to exclude contact allergens as the cause of (or contributing to) persisting chronic dermatitis.

16.5 Treatment

The most important aspect of management is the identification and avoidance of any identified allergen(s). If allergic contact dermatitis is more chronic, symptoms may persist for a variable time after careful avoidance of any identified allergen(s).

General treatment measures are the same as for irritant dermatitis, with use of non-soap wash, regular use of moisturiser for the genital region that also serves as a lubricant for

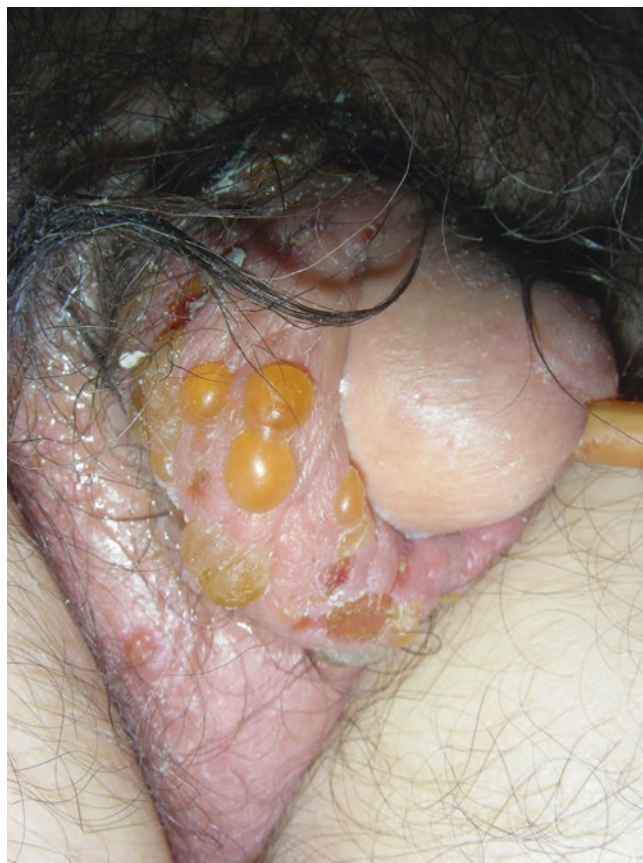

Fig. 16.2 Acute allergic dermatitis due to topical antiseptic

sexual activity (eg, soft white paraffin or petrolatum). Exposure to other irritants that may perpetuate or prolong the allergic contact dermatitis should be minimised or avoided.

Specific management involves the selection of an appropriate topical corticosteroid. If the patient demonstrates a positive patch test result for a topical corticosteroid(s) or a preservative in a topical corticosteroid preparation, the choice will need to be modified. A positive patch test to a specific topical corticosteroid necessitates avoidance of all topical corticosteroids in same corticosteroid group. Start treatment with a moderately potent topical corticosteroid preparation (US Group IV–V) applied twice daily for 4–6 weeks, and then wean to a lower-potency topical corticosteroid (US Group VII). The low-potency topical corticosteroid may eventually only need to be used as needed.

Topical calcineurin inhibitors (pimecrolimus, tacrolimus) are alternatives to topical corticosteroids but can be associated with irritation of genital skin. A topical calcineurin inhibitor may need to be used if the patient demonstrates positive patch test results to multiple topical corticosteroids.

Pearls

- Allergic contact dermatitis is diagnosed by the identification of allergens by cutaneous patch testing.
- Important genital contact allergens include rubber, latex, preservatives, fragrances, topical antibiotics, local anaesthetics, and topical corticosteroids.
- Genital allergic contact dermatitis may be caused by accidental transferral of an allergen by hand.

References

1. Bauer A, Oehme S, Geier J. Contact sensitization in the anal and genital area. *Curr Probl Dermatol*. 2011;40:133–41.
2. Warshaw EM, Furda LM, Maibach HI, Rietschel RL, Fowler JF Jr, Belsito DV, et al. Anogenital dermatitis in patients referred for patch testing: retrospective analysis of cross-sectional data from the North American Contact Dermatitis Group, 1994–2004. *Arch Dermatol*. 2008;144:749–55.
3. Bhate K, Landeck L, Gonzalez E, Neumann K, Schalock PC. Genital contact dermatitis: a retrospective analysis. *Dermatitis*. 2010;21:317–20.
4. Bircher AJ, Hirsbrunner P, Langauer S. Allergic contact dermatitis of the genitals from rubber additives in condoms. *Contact Dermatitis*. 1993;28:125–6.
5. Aschenbeck KA, Warshaw EM. Allergenic ingredients in personal hygiene wet wipes. *Dermatitis*. 2017;28:317–22.
6. González-Pérez R, Sánchez-Martínez L, Piqueres Zubiaurre T, Urtaran Ibarzábal A, Soloeta Arechavala R. Patch testing in patients with perianal eczema. *Actas Dermosifiliogr*. 2014;105:694–8.
7. de Groot AC, Schmidt E. Tea tree oil: contact allergy and chemical composition. *Contact Dermatitis*. 2016;75:129–43.

Lichen Simplex Chronicus, Prurigo Nodularis, Picker's Nodule

17

17.1 Definitions

Lichen simplex chronicus is a morphologic variant of chronic dermatitis characterised by pruritic, scaly plaques. *Prurigo nodularis* (nodular prurigo) is a papulonodular variant of lichen simplex chronicus, and *picker's nodule* is a localised variant of prurigo nodularis.

17.2 Aetiology

The aetiology of lichen simplex chronicus, prurigo nodularis and picker's nodule is uncertain, but a complex interplay of both genetic and environmental factors is important. Lichen simplex chronicus and nodular prurigo are a response to chronic rubbing or scratching, more commonly seen in atopic individuals. The "itch-scratch cycle" is partly driven by emotional factors. Racial factors also may be important as lichenification is reportedly more common in people of Asian ancestry. Prurigo nodularis (nodular prurigo) is more common in women and may be an exaggerated form of lichen simplex chronicus. Prurigo nodularis may be initiated by arthropod bites (insects, scabies), an underlying metabolic disorder or infections (mycobacteria, HIV). Picker's nodule after scabies infestation is synonymous with *post-scabetic nodule*.

17.3 Clinical Features

Lichen simplex chronicus is more common in middle-aged to older patients. Chronic irritation, itch, or rubbing are the main symptoms but secondary changes of weeping, erosions, or ulceration may dominate. Itch is often severe enough to disturb sleep. Characteristic sites are the occipital scalp, pos-

terior neck, forearm, lower leg, dorsum of the foot, and the ano-genital region. Lichen simplex chronicus of the scrotum commonly presents as a pruritic, thickened, hyperkeratotic plaque with multiple parallel lines (lichenification) on the anterior scrotum, or as a papular thickening resulting from chronic itching or rubbing. Either the whole anterior scrotum is involved, or only half of the scrotum (hemi-scrotum). If only half of the scrotum is lichenified, it is more commonly right-sided if the patient is right-handed (Figs. 17.1 and 17.2). Excoriations or secondary infection may be evident (Fig. 17.3). More severe nodular lichen simplex of scrotum has been described with a "cobblestone" or "pineapple skin" appearance [1]. Giant lichenification of Pautrier is an extreme form of lichen simplex chronicus of the scrotum resulting in a fissured, verrucous, and grossly thickened surface (Fig. 17.4). Nodular prurigo and picker's nodule are usually localised to penile shaft or scrotum and may be excoriated (Figs. 17.5 and 17.6).

17.4 Diagnosis

Lichen simplex chronicus is usually diagnosed clinically, but secondary changes of excoriation or secondary infection may make diagnosis more difficult. Multiple pruritic nodules on the penile shaft or scrotum are characteristic of scabies, so careful examination is necessary to exclude scabies. Psoriasis, in situ squamous cell carcinoma (penile intraepithelial neoplasia), and early invasive squamous cell carcinoma (SCC) are important differential diagnoses. A single nodule on the penile shaft or scrotum may be picker's nodule, secondary to scabies, or a squamous cell carcinoma (SCC). Multiple benign scrotal epidermoid (epidermal) cysts may also be excoriated and itchy.

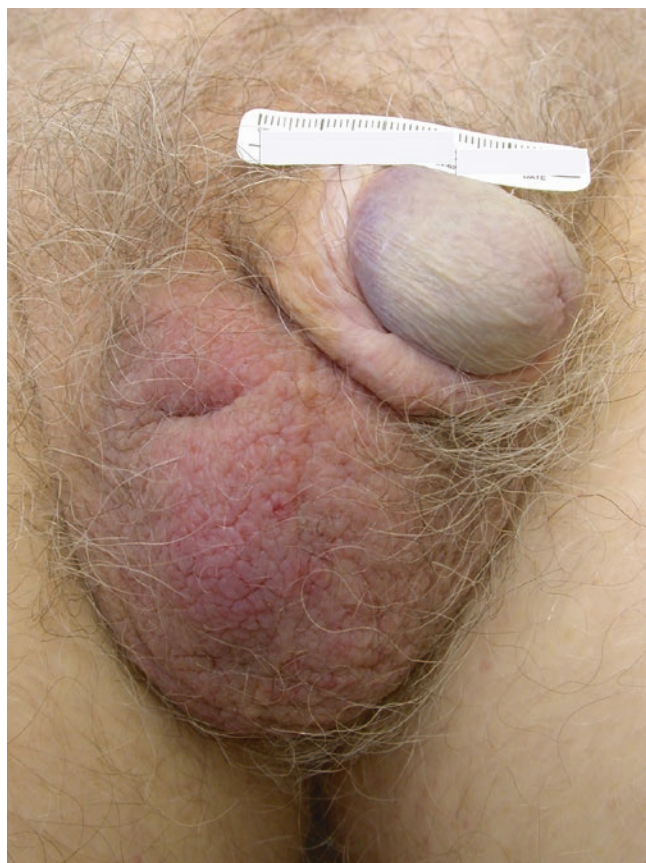

Fig. 17.1 Lichen simplex chronicus on the right side of the scrotum

If the clinical diagnosis is in doubt, a genital skin biopsy may help to differentiate these diseases. Histopathologic features of lichen simplex chronicus include acanthosis, hyperkeratosis, variable spongiosis with a chronic inflammatory dermal infiltrate. Genital lichen simplex chronicus or prurigo nodularis may be associated with an atopic diathesis or features of generalised pruritus. Investigations to exclude underlying pruritic or systemic diseases include complete blood examination, renal function, liver function, thyroid function, fasting blood glucose, serum iron, serum ferritin, serum transferrin, hepatitis B, hepatitis C, HIV, and selected cancer screening, if indicated.

17.5 Treatment

General management principles include explaining the diagnosis and reassurance that there is no sexually transmissible infection (STI) or cancer. Management of scabies or any

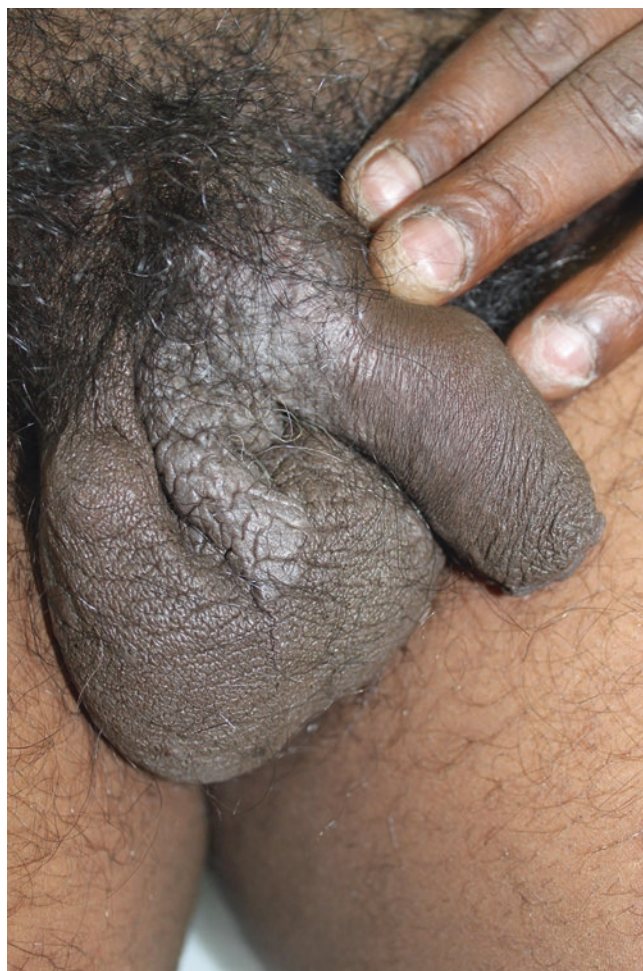

Fig. 17.2 Lichen simplex chronicus affecting the base of the scrotum and penile shaft

underlying systemic disease is important. Encouragement to use a non-soap wash and regular daily use of an emollient are important. Topical corticosteroids are the mainstay of treatment for ano-genital chronic dermatitis. Use of a moderately potent topical corticosteroid preparation (US Group IV–V) applied twice daily for 4–6 weeks is usually adequate, but sometimes a stronger topical corticosteroid may be needed. After 6 weeks, reduce to a lower-potency topical corticosteroid (US Group VII), used only as needed. Topical calcineurin inhibitors (pimecrolimus, tacrolimus) may be used as steroid-sparing agents in the short term. As for perianal psoriasis, a low-strength, topical coal tar-based preparation (*eg*, LPC 3%, salicylic acid 2% in soft white paraffin ointment) is a useful alternative treatment for perianal lichen simplex chronicus, but topical tars should be avoided on penile or

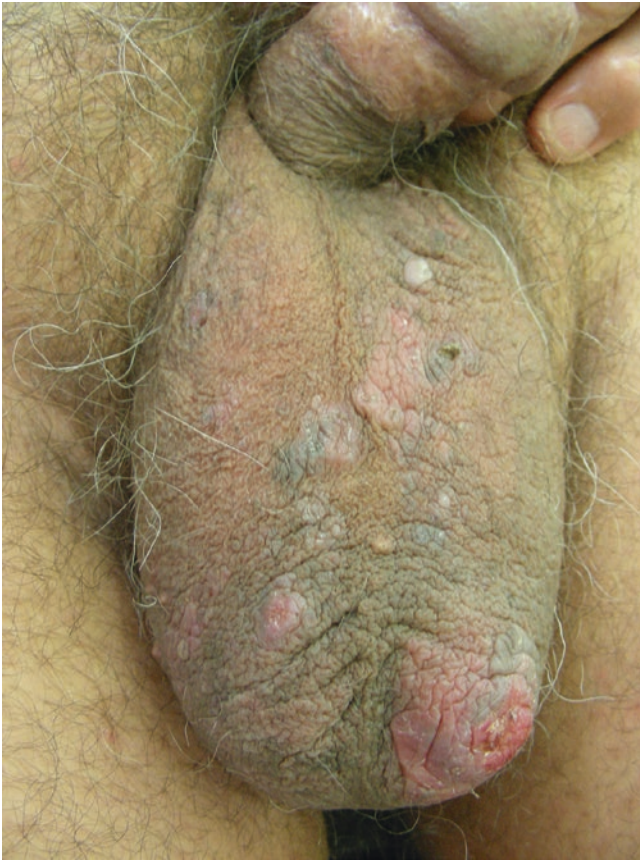

Fig. 17.3 Excoriated lichen simplex chronicus of the scrotum

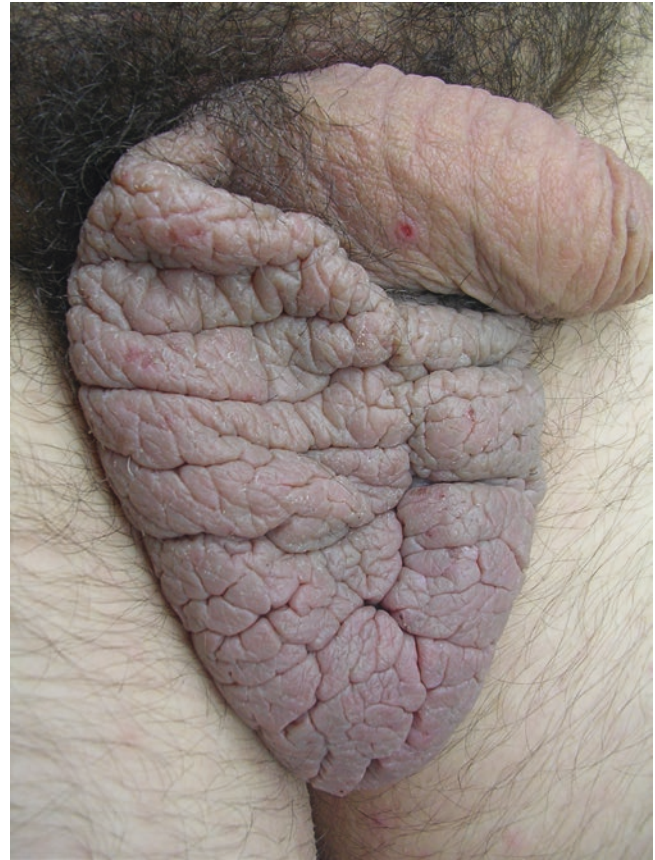

Fig. 17.4 Severe lichen simplex scrotum (giant lichenification of Pautrier)

scrotal skin due to the possible risk of irritation. A short course of oral corticosteroids may help gain control of the chronic “itch-scratch cycle” but should be avoided long-term. Intralesional corticosteroids are effective for lichen simplex, prurigo nodularis and picker’s nodule. Steroid-sparing systemic agents are valuable in managing widespread prurigo nodularis or recalcitrant lichen simplex chronicus. Methotrexate (10–20 mg once weekly) is often effective. Nonsedating antihistamines may be tried to control daytime itch. Low-dose doxepin (10–20 mg in the evening) is useful to control nocturnal pruritus, particularly if it is associated with sleep disturbance. Empiric treatment of scabies with either topical permethrin 5% cream or oral iver-

mectin (200 µg/kg) and repeated 7 days later may be necessary if scabies infestation cannot be confidently excluded. This is particularly important in patients susceptible to scabies infestation (the intellectually impaired, elderly, infirm or institutionalised). Phototherapy is contraindicated for treatment of all male genital dermatoses. Local surgical excision may be considered if recalcitrant localised lichen simplex chronicus or prurigo nodularis fails to respond to medical treatment [1]. Local surgical excision is rarely needed and should only be considered as a last option of treatment. Long-term follow-up and supportive care are important to help patients with distressing, chronic eczematous disorders.

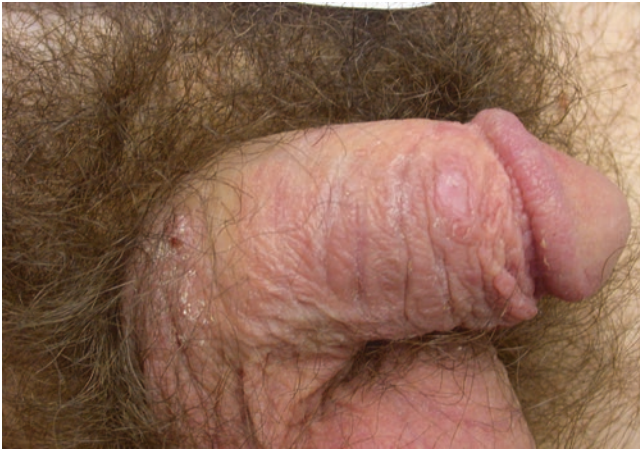


Fig. 17.5 Nodular prurigo and lichen simplex chronicus of the penile shaft

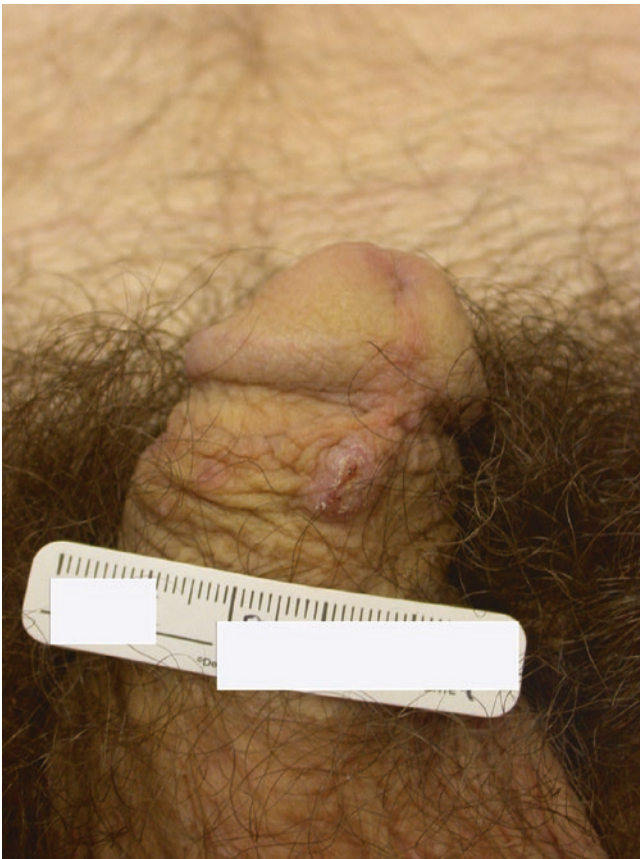

Fig. 17.6 Picker's nodule on the distal shaft of the penis

Pearls

- Important differential diagnoses of lichen simplex chronicus include psoriasis, penile intraepithelial neoplasia and early invasive squamous cell carcinoma.
- Male genital prurigo nodularis and picker's nodule must be differentiated from scabetic nodules and multiple epidermoid cysts.

Reference

1. Porter WM, Bewley A, Dinneen M, Walker CC, Fallowfield M, Francis N, Bunker CB. Nodular lichen simplex of the scrotum treated by surgical excision. *Br J Dermatol.* 2001;144:915–6.

Seborrhoeic Dermatitis and Sebo-psoriasis

18

18.1 Definitions

Seborrhoeic dermatitis is a chronic inflammatory dermatosis involving seborrhoeic sites of the scalp, face, and anterior chest with greasy, adherent scale associated with a yeast organism, *Pityrosporum orbiculare*. *Sebo-psoriasis* is a hybrid or overlap disease showing features of both psoriasis and seborrhoeic dermatitis.

18.2 Aetiology

Seborrhoeic dermatitis is associated with the common yeast *Pityrosporum orbiculare*, also termed *Pityrosporum ovale* or *Malassezia furfur*. A direct causal relationship has not been defined. Seborrhoeic dermatitis occurs most commonly in individuals with greasy skin, chronic neurological disease (eg. Parkinson's disease, multiple sclerosis, paralysis following stroke) and in patients with untreated HIV infection. Adult seborrhoeic dermatitis probably has no relationship to neonatal or infantile seborrhoeic dermatitis.

18.3 Clinical Features

Seborrhoeic dermatitis appears after puberty as an erythematous and scaly dermatitis in seborrhoeic regions of the scalp, postauricular areas, medial eyebrows, glabella, central face, anterior chest ("petaloid" form) and flexures. Seborrhoeic dermatitis occurs most commonly in adulthood as fine scaling of the scalp, referred to as "dandruff." Itch is variable. Shedding of scalp scale ("dandruff") may be socially embarrassing. Seborrhoeic dermatitis confined to the scalp or face is common (Figs. 18.1, 18.2, and 18.3). Patients with more severe and widespread disease may give a history of immobility or chronic neurologic diseases, especially Parkinson's disease, multiple sclerosis or paralysis following stroke. Patients may be known to have HIV infection, but widespread seborrhoeic dermatitis (previously

an AIDS-defining illness) is less commonly seen today because of the treatment of HIV infection with highly effective antiretroviral therapy. Seborrhoeic dermatitis usually improves with ultraviolet light exposure but may flare with emotional stress. The scaly, erythro-squamous eruption of the central face, glabella, medial eyebrows, postauricular region and anterior chest usually has a well-defined margin. Seborrhoeic dermatitis of the scalp is characterised by diffuse, fine scaling with a less well-defined border when compared with psoriasis, which has a sharply defined margin of

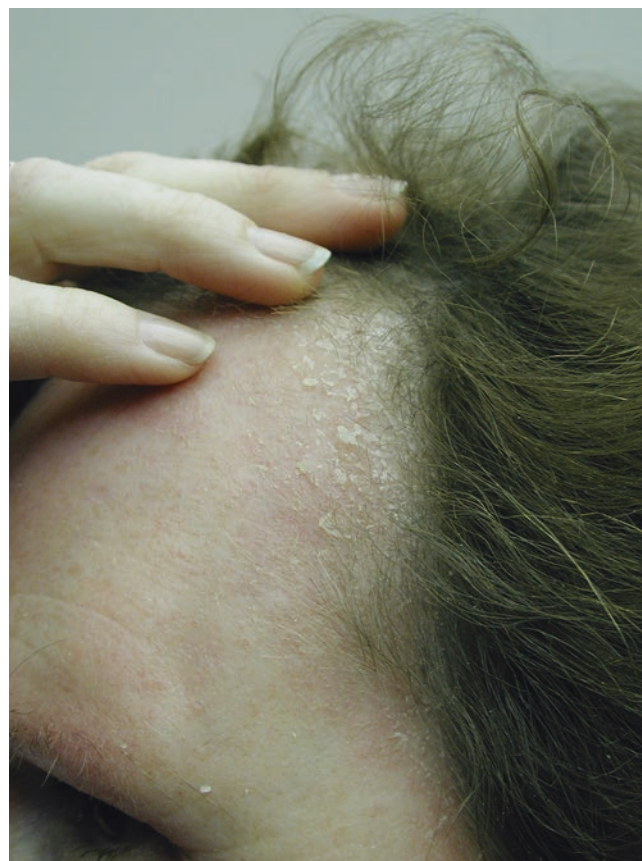

Fig. 18.1 Seborrhoeic dermatitis of the scalp

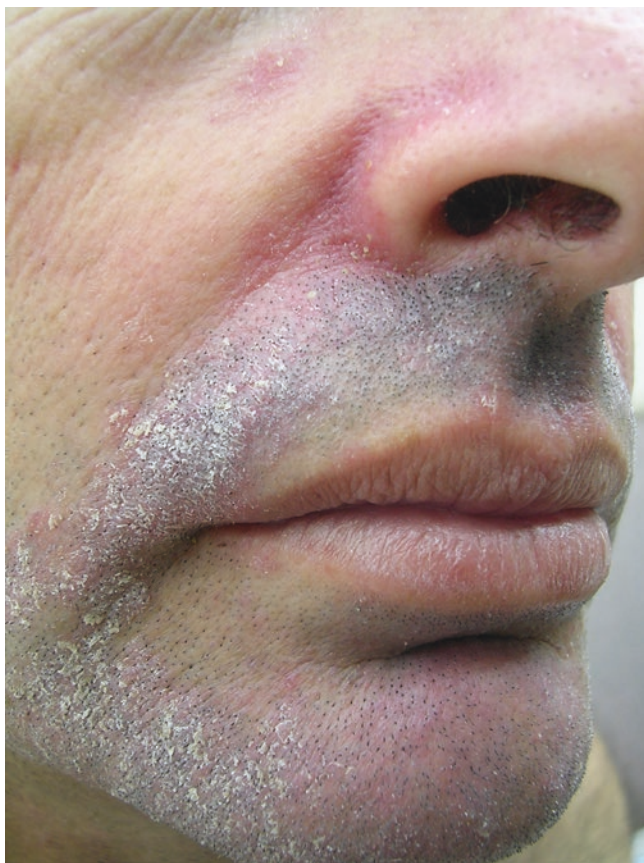

Fig. 18.2 Seborrhoeic dermatitis of the beard area

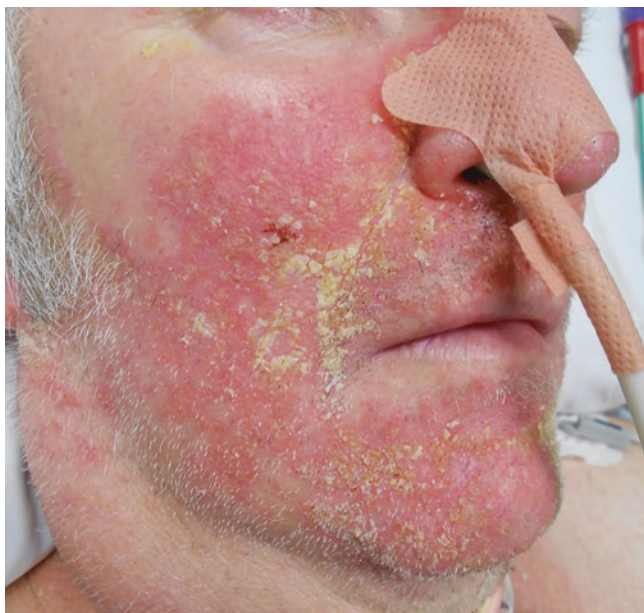

Fig. 18.3 Severe seborrhoeic dermatitis of the central face

red, scaly plaques, mostly on the occipital scalp. Seborrhoeic dermatitis involving eyelid margins results in blepharitis with yellow crusting or destruction of eyelashes. Seborrhoeic dermatitis may occur in flexures and can involve male genitalia [1]. Genital seborrhoeic dermatitis shows pink to red patches or thin plaques involving part or all of the genitalia and may extend onto the groin creases and proximal thighs. Fine scaling is usually evident on the genitalia and proximal thighs but absent in the groins (Fig. 18.4). Inverse psoriasis is a variant of psoriasis occurring in flexural sites, including the inguino-scrotal region. Flexural (or inverse) psoriasis has a sharp border, as seen with psoriasis of the natal or intergluteal cleft, but variable scale (see Chap. 13). Flexural psoriasis may have features overlapping with seborrhoeic dermatitis. The term “sebo-psoriasis” is often used for poorly defined scaliness of the scalp with redness and scaling of the medial eyebrows, medial cheeks, naso-labial, folds and chin, with visible psoriasis at other sites.

18.4 Diagnosis

Seborrhoeic dermatitis and sebo-psoriasis are clinical diagnoses. Seborrhoeic dermatitis in seborrhoeic sites is very common, especially on the scalp (“dandruff”) and central face. Wood’s (UVA) light examination is negative and helps to exclude erythrasma. A skin swab is important to exclude *Candida albicans*, and skin scraping is useful to exclude tinea cruris.

Skin biopsy is occasionally necessary for atypical or resistant disease, to exclude Darier’s disease, Hailey-Hailey disease and extramammary Paget’s disease. If seborrhoeic dermatitis is widespread, HIV infection must be excluded.

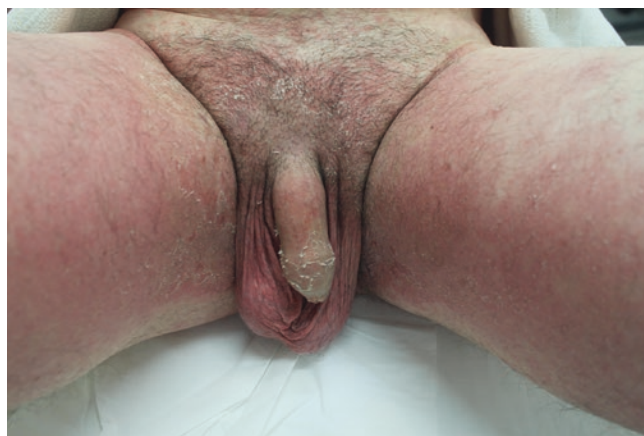

Fig. 18.4 Seborrhoeic dermatitis of genitalia and inner thighs (also involving face and axillae) in immuno-competent adult male

Genital seborrhoeic dermatitis in immunocompetent adults outside the setting of HIV infection or neurological disease is an uncommon disease. It may be difficult to differentiate adult male genital seborrhoeic dermatitis from irritant dermatitis, candidiasis or flexural psoriasis. Genital irritant dermatitis may be secondarily colonised with *Candida albicans*. Differential diagnoses of genital seborrhoeic dermatitis include irritant dermatitis, flexural psoriasis, candidiasis, allergic contact dermatitis, tinea cruris, erythrasma, pityriasis rosea, Darier's disease, Hailey-Hailey disease, cutaneous drug eruption, or (rarely) extramammary Paget's disease.

18.5 Treatment

Scalp seborrhoeic dermatitis is treated with anti-yeast shampoo and a topical corticosteroid lotion to relieve itch. Shampoos include ketoconazole, tar-based shampoos, selenium sulphide, and zinc pyrithione. Facial seborrhoeic dermatitis is best treated with a topical imidazole or ketoconazole cream, combined with a low-potency topical corticosteroid (US Class VII) such as 1% hydrocortisone cream, while simultaneously treating the scalp with an anti-yeast shampoo. Flexural or genital seborrhoeic dermatitis is treated similarly, with a topical imidazole or ketoconazole cream and 1% hydrocortisone cream. Intermittent therapy with a topical imidazole or ketoconazole cream

with 1% hydrocortisone cream may be necessary if disease relapses. For more severe or extensive seborrhoeic dermatitis, treatment with oral fluconazole is necessary. Treatment of sebo-psoriasis is similar to the treatment for seborrhoeic dermatitis, with a low- or medium-potency topical corticosteroid (US Class IV–VI) combined with a topical imidazole or ketoconazole cream. Once sebo-psoriasis improves, treatment may be weaned to 1% hydrocortisone cream, used as needed.

Pearls

- Widespread seborrhoeic dermatitis occurs most commonly with chronic neurological disease or untreated HIV infection.
- Most adult males diagnosed with genital seborrhoeic dermatitis have irritant dermatitis, candidiasis, or flexural psoriasis.

Reference

1. Mallon E, Hawkins D, Dinneen M, Francics N, Fearfield L, Newson R, Bunker C. Circumcision and genital dermatoses. Arch Dermatol. 2000;136:350–4.

19.1 Definition

Lichen sclerosis is a chronic inflammatory skin disease with predilection for ano-genital skin, resulting in thickening (sclerosis) and paradoxical thinning (atrophy) of skin and phimosis in uncircumcised males.

19.2 Aetiology

The cause of male genital lichen sclerosis is not exactly known but lichen sclerosis is probably an autoimmune disease [1]. However, unlike female patients with vulval lichen sclerosis, male patients with genital lichen sclerosis show no increase in other autoimmune diseases [2]. Chronic occluded exposure of susceptible genital epithelium to urine has been proposed as the cause of male genital lichen sclerosis [3] but this theory has been challenged [4]. Lichen sclerosis occurs predominantly in uncircumcised males [5, 6], and infantile circumcision is protective for lichen sclerosis [1]. Lichen sclerosis is associated with phimosis in boys and has been demonstrated by histological examination of the foreskins of most boys circumcised for phimosis [7–9]. Male genital lichen sclerosis is a premalignant disease, but association with squamous cell carcinoma (SCC) is debated. The reported risk of males with genital lichen sclerosis developing penile in situ or invasive SCC varies between 2% and 9% [10–12], less than the estimated risk for women with vulval lichen sclerosis [13]. Lichen sclerosis is detected histologically in 28–55% of males with penile SCC [14–16]. Other reported associations with genital lichen sclerosis in men include hypertension, hyperlipidemia, higher body mass index, and use of tobacco products [17, 18], but the significance of these associations is unclear.

19.3 Clinical Features

Male genital lichen sclerosis has bimodal onset of presentation in young boys and adult men [13], with peak incidence in the fourth decade [1, 10]. Male genital lichen sclerosis has a variable presentation, from asymptomatic whitening or thickening of the glans (Fig. 19.1), the foreskin (Fig. 19.2), or the penile shaft [19] to fragile skin prone to tearing and bleeding. Itch, burning, bruising, erosions, ulceration, blistering, or difficulty in micturition are less common. Male genital lichen sclerosis commonly presents as acquired phimosis in adults. Dyspareunia is a significant symptom, as patients experience discomfort, pain, or splitting of the foreskin with erections and sexual activity, negatively impacting their quality of life [1]. The pale white, sclerotic glans penis often exhibits a violaceous hue, with telangiectases and purpura. A useful clinical sign is partial constriction or “waisting” of the distal penile shaft on retracting the tightened foreskin (Fig. 19.3) [1]. *Balanitis xerotica obliterans* (BXO) is a term used in urology that should be considered synonymous with lichen sclerosis with phimosis in adult males (Figs. 19.4 and 19.5) [6]. Male genital lichen sclerosis may present as diffuse redness of glans and foreskin (balanoposthitis). Perianal involvement is not seen in males with genital lichen sclerosis but may involve the penile urethra leading to meatal or urethral stenosis resulting in difficulty with micturition [5]. Careful examination is necessary to detect early development of in situ or invasive SCC (Fig. 19.6). As diseases reported to be associated with male genital lichen sclerosis, both hypertension and hyperlipidemia should be excluded.

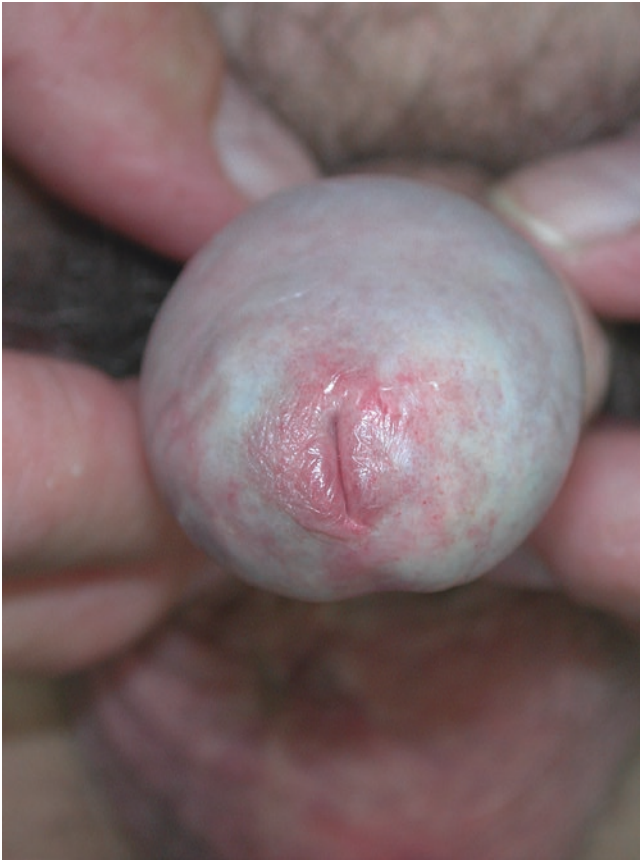

Fig. 19.1 Lichen sclerosus of the glans

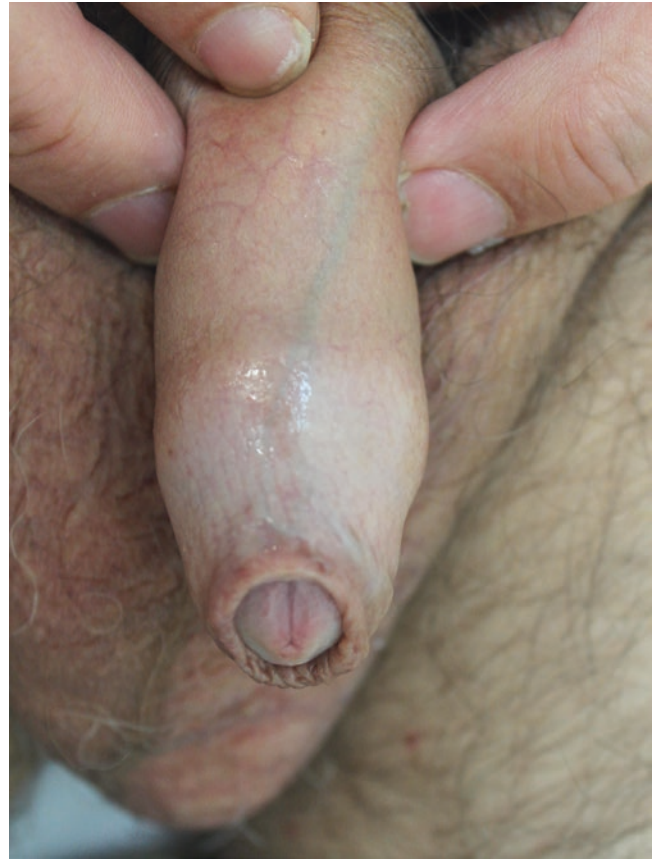

Fig. 19.2 Lichen sclerosus of the foreskin

19.4 Diagnosis

Male genital lichen sclerosus is often diagnosed clinically, but skin biopsy increases diagnostic accuracy. A combined clinicopathologic diagnosis is more accurate and helps management of these patients and their partners. Accurate diagnosis is also important for clinical studies and research. The value of genital skin biopsy has been questioned as up to one third of male patients with genital lichen sclerosus have non-specific histology [1]. The British Association of Dermatologists [13] suggests biopsy only if the diagnosis is unclear, if the condition fails to respond to therapy, or if neoplastic change is suspected. Baseline clinical photography is an alternative to skin biopsy that aids monitoring of lichen sclerosus and response to treatment.

19.5 Treatment

Management is aimed at symptom control, maximising normal function, improving cosmetic appearance and monitoring for malignant transformation. General measures include

avoiding soap, minimising irritant factors and regular use of a moisturiser and lubricant for sexual activity.

There are two opposing views regarding the management of male genital lichen sclerosus. The medical approach involves the use of potent or ultrapotent topical corticosteroids, as lichen sclerosus is an inflammatory disease of both the foreskin and glans. The surgical approach advocates circumcision alone as definitive treatment, focusing primarily on disease of the foreskin. Surgeons tend to see patients with more advanced genital lichen sclerosus with significant phimosis, leading to a bias towards surgical treatment, whereas non-surgical physicians see many patients with earlier disease that is successfully managed without circumcision. Medical treatment should be tried before surgical treatment unless the patient presents with a totally fixed, non-retractile phimosis or there is evidence of malignancy at presentation. Medical treatment with potent topical corticosteroids is currently recommended for management of phimosis in infants and pre-adolescent boys [20, 21]. Treatment with topical corticosteroids relieves symptoms, improves clinical appearance, and often resolves phimosis. Begin with an ultrapotent topical corticosteroid (US Class I)

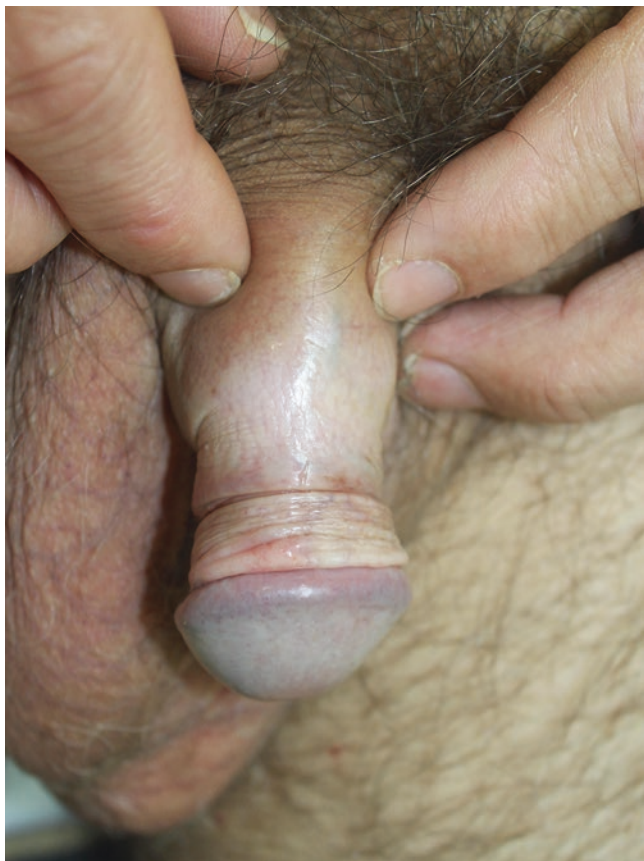

Fig. 19.3 Lichen sclerosus of the foreskin with waisting sign

such as clobetasol propionate 0.05% ointment or cream for 6–12 weeks and then gradually taper the strength of the topical corticosteroid [22]. Once improvement is achieved, wean to a less-potent topical corticosteroid to be used intermittently only if needed. This medical approach is reported to be successful in the short term for 60% of men with genital lichen sclerosus, with long-term success in 50% of patients [1]. Whether early treatment of male genital lichen sclerosus with topical corticosteroids prevents transformation to SCC is unproven.

Other medical treatments include topical tacrolimus [23, 24], but caution is necessary on ano-genital skin because of a possible risk of developing SCC [1, 25]. Topical calcipotriol has limited efficacy for male genital sclerosis [26]. Treatment with laser therapy [27], photodynamic therapy [28] and autologous platelet-rich plasma [29] have all been reported, but none have demonstrated superior efficacy to topical corticosteroids. These treatments are also more expensive and have not demonstrated long-term safety for use in male genital lichen sclerosus.

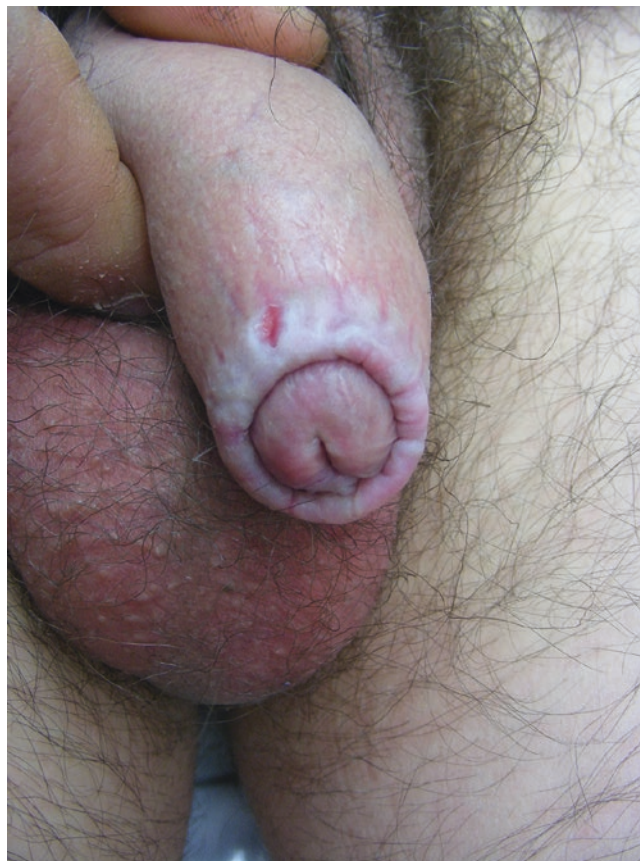

Fig. 19.4 Lichen sclerosus with acquired phimosis

Circumcision is the main surgical option for male genital lichen sclerosus, eliminating the moisture-rich environment under the foreskin, eliminating pooling of urine and allowing full keratinisation of the glans [1, 30]. Treatment with circumcision should be considered for male patients with a tight phimosis associated with voiding difficulty or when medical treatment fails. Circumcision is curative for over 70% of men with genital lichen sclerosus [1], but it may fail to treat lichen sclerosus of the glans and urethra [2]. Circumcision has advantage of facilitating self-detection of malignant change in the penis. Trials are needed for pre-treatment of phimosis with an ultrapotent topical corticosteroid prior to circumcision, that may improve surgical outcomes. Post-operative use of an ultrapotent topical corticosteroid should be considered for lichen sclerosus involving the glans. Other surgical treatments include resurfacing of the glans, dilation or urethroplasty for urethral stenosis and treatment of associated malignancy [10, 30]. Long-term follow-up is essential to assess the response to treatment and detect malignant change.

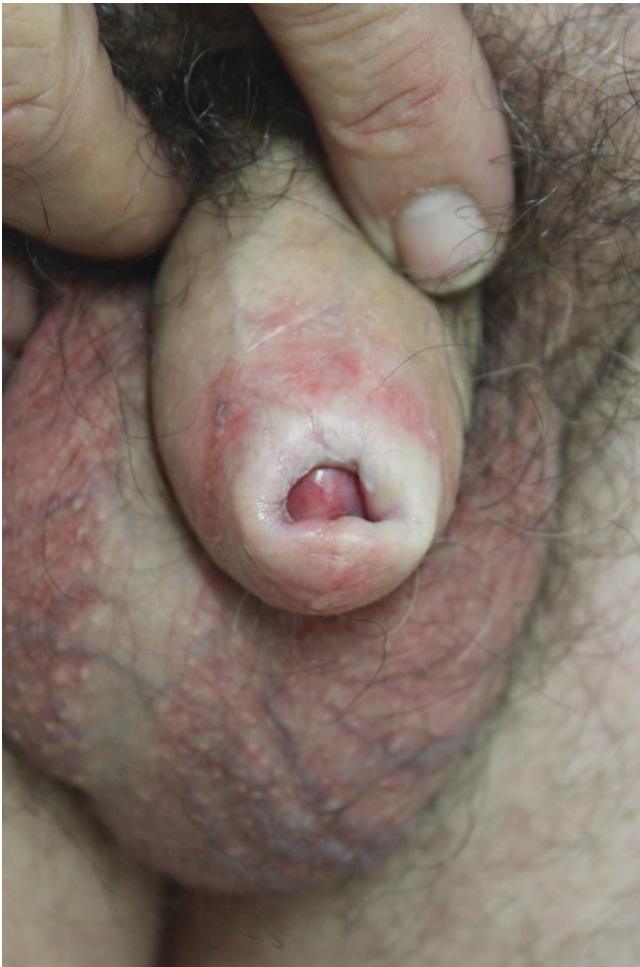

Fig. 19.5 Lichen sclerosis with severe, unretractable phimosis

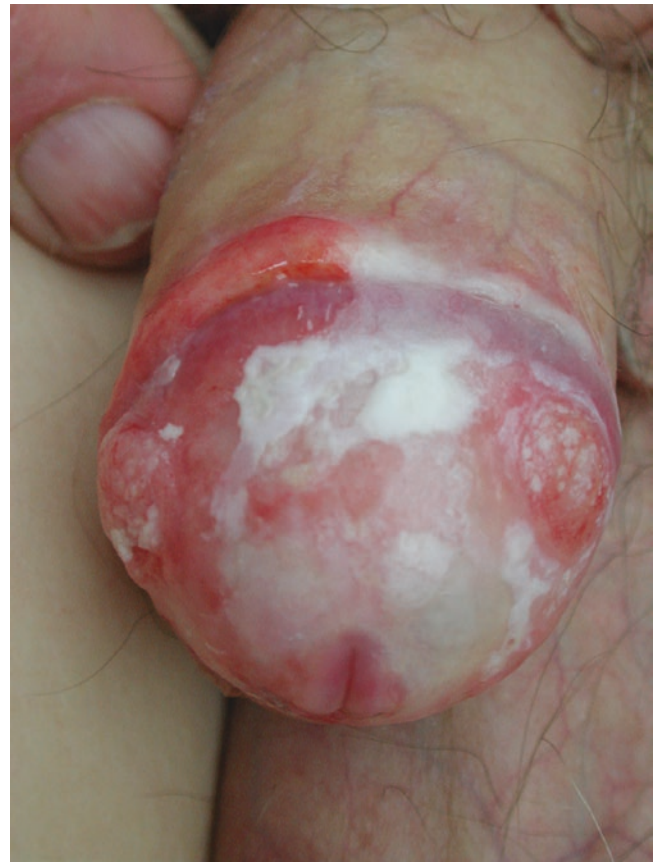

Fig. 19.6 Squamous cell carcinoma arising from lichen sclerosis of the glans

Pearls

- Male genital lichen sclerosis is the commonest cause of acquired phimosis.
- Treat lichen sclerosis with phimosis with a potent topical corticosteroid before circumcision.
- Circumcision is not always curative for male genital lichen sclerosis. Use topical corticosteroid if lichen sclerosis of the glans persists after circumcision.
- Male genital lichen sclerosis is most likely a pre-malignant disease and may cause urinary obstruction.
- Long-term follow-up of genital lichen sclerosis is needed to detect malignant transformation.

References

1. Edmonds EV, Hunt S, Hawkins D, Dinneen M, Francis N, Bunker CB. Clinical parameters in male genital lichen sclerosis: a case series of 329 patients. *J Eur Acad Dermatol Venereol.* 2012;26:730–7.
2. Kantere D, Alvergren G, Gillstedt M, Pujol-Calderon F, Tunbäck P. Clinical features, complications and autoimmunity in male lichen sclerosis. *Acta Derm Venereol.* 2017;97:365–9.
3. Bunker CB. EDF lichen sclerosis guideline. *J Eur Acad Dermatol Venereol.* 2017;31:e97–8.
4. Kirtschig G, Becker K, Günthert A, Jasaitiene D, Cooper SM, Chi CC, et al. Response to letter by Prof. C.B.B. Bunker. *J Eur Acad Dermatol Venereol.* 2017;31:e104–5.
5. Evans DT. Retrospective study of male lichen sclerosis and outcome in Leicester: 1995–9 inclusive: experience of a genitourinary medical clinic. *Sex Transm Infect.* 2000;76:495.

6. Mallon E, Hawkins D, Dinneen M, Francics N, Fearfield L, Newson R, Bunker C. Circumcision and genital dermatoses. *Arch Dermatol*. 2000;136:350–4.
7. Jayakumar S, Antao B, Bevington O, Furness P, Ninan GK. Balanitis xerotica obliterans in children and its incidence under the age of 5 years. *J Pediatr Urol*. 2012;8:272–5.
8. Shankar KR, Rickwood AM. The incidence of phimosis in boys. *BJU Int*. 1999;84:101–2.
9. Kiss A, Király L, Kutasy B, Merksz M. High incidence of balanitis xerotica obliterans in boys with phimosis: prospective 10-year study. *Pediatr Dermatol*. 2005;22:305–8.
10. Depasquale I, Park AJ, Bracka A. The treatment of balanitis xerotica obliterans. *BJU Int*. 2000;86:459–65.
11. Barbagli G, Palminteri E, Mirri F, Guazzoni G, Turini D, Lazzeri M. Penile carcinoma in patients with genital lichen sclerosis: a multicenter survey. *J Urol*. 2006;175:1359–63.
12. Micali G, Nasca MR, Innocenzi D. Lichen sclerosis of the glans is significantly associated with penile carcinoma. *Sex Transm Infect*. 2011;77:226.
13. Neill SM, Lewis FM, Tatnall FM, Cox NH. British Association of Dermatologists' guidelines for the management of lichen sclerosis 2010. *Br J Dermatol*. 2010;163:672–82.
14. Velazquez EF, Al C. Lichen sclerosis in 68 patients with squamous cell carcinoma of the penis: frequent atypias and correlation with special carcinoma variants suggests a precancerous role. *Am J Surg Pathol*. 2003;27:1448–53.
15. Pietrzak P, Hadway P, Corbishley CM, Watkin NA. Is the association between balanitis xerotica obliterans and penile carcinoma underestimated? *BJU Int*. 2006;98:74–6.
16. Powell J, Robson A, Cranston D, Wojnarowska F, Turner R. High incidence of lichen sclerosis in patients with squamous cell carcinoma of the penis. *Br J Dermatol*. 2001;145:85–9.
17. Erickson BA, Elliott SP, Myers JB, Voelzke BB, Smith TG 3rd, McClung CD, et al. Trauma and Urologic Reconstructive Network of Surgeons. Understanding the relationship between chronic systemic disease and lichen sclerosis urethral strictures. *J Urol*. 2016;195:363–8.
18. Doiron PR, Bunker CB. Obesity-related male genital lichen sclerosis. *J Eur Acad Dermatol Venereol*. 2017;31:876–9.
19. Riddell L, Edwards A, Sherrard J. Clinical features of lichen sclerosis in men attending a department of genitourinary medicine. *Sex Transm Infect*. 2000;76:311–3.
20. Moreno G, Corbalán J, Peñaloza B, Pantoja T. Topical corticosteroids for treating phimosis in boys. *Cochrane Database Syst Rev*. 2014;9:CD008973.
21. Kuehhas FE, Miernik A, Sevcenco S, Tosev G, Weibl P, Schoenthaler M, Lassmann J. Predictive power of objectivation of phimosis grade on outcomes of topical 0.1% betamethasone treatment of phimosis. *Urology*. 2012;80:412–6.
22. Dahlman-Ghozlan K, Hedblad MA, von Krogh G. Penile lichen sclerosis et atrophicus treated with clobetasol dipropionate 0.05% cream: A retrospective clinical and histopathologic study. *J Am Acad Dermatol*. 1999;40:451–7.
23. Henge UR, Krause W, Hofmann H, Stadler R, Gross G, Meurer M, et al. Multicentre, phase II trial on the safety and efficacy of topical tacrolimus ointment for the treatment of lichen sclerosis. *Br J Dermatol*. 2006;155:1021–8.
24. Böhm M, Frieling U, Luger TA, Bonsmann G. Successful treatment of anogenital lichen sclerosis with topical tacrolimus. *Arch Dermatol*. 2003;139:922–4.
25. Fischer G, Bradford J. Topical immunosuppressants, genital lichen sclerosis and the risk of squamous cell carcinoma: a case report. *J Reprod Med*. 2007;52:329–31.
26. Gupta S, Saraswat A, Kumar B. Treatment of genital lichen sclerosis with topical calcipotriol. *Int J STD AIDS*. 2005;16:772–4.
27. Windahl T. Is carbon dioxide laser treatment of lichen sclerosis effective in the long run? *Scand J Urol Nephrol*. 2006;40:208–11.
28. Alexiades-Armenakas M. Laser-mediated photodynamic therapy. *Clin Dermatol*. 2006;24:16–25.
29. Casabona F, Gambelli I, Casabona F, Santi P, Santori G, Baldelli I. Autologous platelet-rich plasma (PRP) in chronic penile lichen sclerosis: the impact on tissue repair and patient quality of life. *Int Urol Nephrol*. 2017;49:573–80.
30. Clouston D, Hall A, Lawrentschuk N. Penile lichen sclerosis (balanitis xerotica obliterans). *BJU Int*. 2011;108(Suppl 2):14–9.

20.1 Definition

Lichen planus is an inflammatory dermatosis that presents clinically as multiple, polygonal, pruritic, violaceous papules. Lichen planus may involve hair, nails, oral mucosa, and genital skin or mucosa.

20.2 Aetiology

The pathophysiology of lichen planus is not fully understood but it is thought to be a T-cell-mediated disorder with increased Th-1 expression and T-cell reactivity against basement membrane zone antigens [1].

20.3 Clinical Features

Genital lichen planus may be part of widespread lichen planus, or lichen planus may be confined to genital skin. The glans, foreskin and penile shaft may be involved in genital lichen planus. Genital lichen planus may be asymptomatic or itchy, weeping and irritated, especially erosive lichen planus. As with most genital dermatoses, the appearance of genital lichen planus is a common concern, leading to concern about a possible sexually transmissible infection (STI) or cancer. Erosive lichen planus occasionally may be very painful [2]. The four commonest clinical presentations are a solitary hyperkeratotic plaque (Fig. 20.1), the annular form (Fig. 20.2), the lace pattern (Wickham's striae) (Fig. 20.3) and erosive lichen planus, if uncircumcised (Figs. 20.4 and 20.5). The annular form occurs mostly on the glans and scrotum [3]. The erosive form occurs in uncircumcised males, involving the glans, coronal sulcus, and foreskin of the preputial recess. Less common variants include a bullous form [4]. Gingival involvement may occur as part of peno-gingival lichen planus, analogous to vulvo-vaginal-gingival syndrome in women [5].

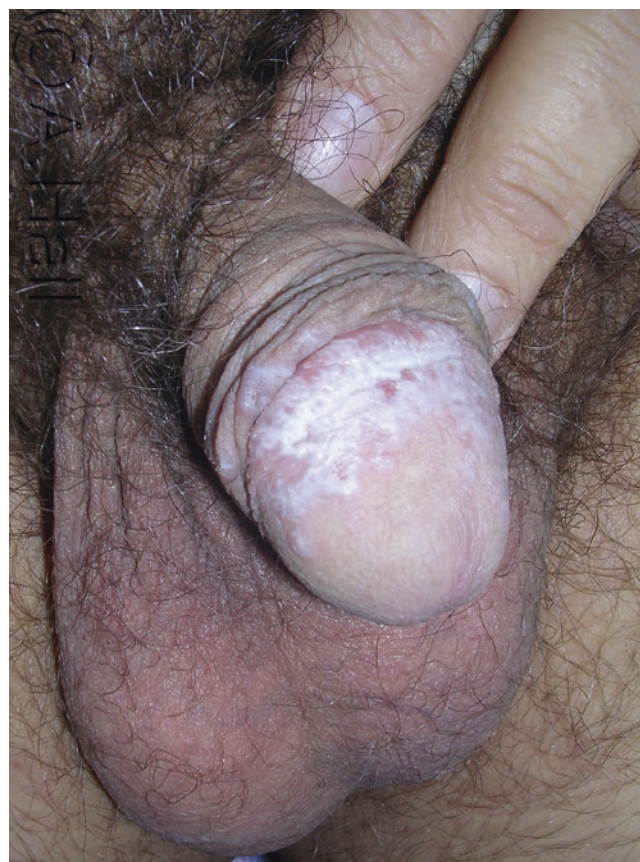

Fig. 20.1 Hyperkeratotic plaque of lichen planus on the glans

20.4 Diagnosis

Diagnosis of genital lichen planus is mostly clinical. Diagnosis is easier if genital lesions are part of widespread cutaneous lichen planus. Lichen planus may have clinical features similar to those of lichen sclerosus but lichen sclerosus is usually confined to the ano-genital region. Dermoscopy may help clinical assessment [6]. Histological confirmation of the clinical diagnosis is important, but loss of the epidermis

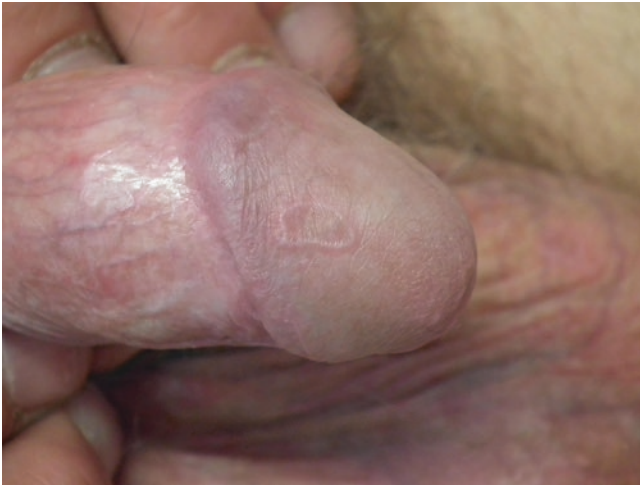

Fig. 20.2 Annular lichen planus of the glans

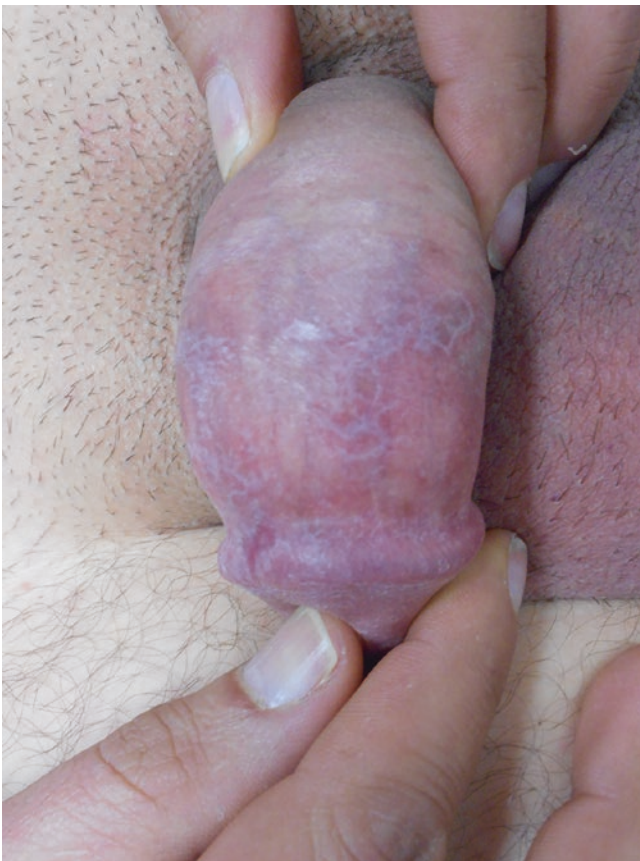

Fig. 20.3 Lace-pattern lichen planus

in erosive lichen planus makes histological interpretation more difficult.

Differential diagnoses include irritant dermatitis, allergic contact dermatitis, psoriasis, fixed drug eruption, plasma cell (Zoon's) balanitis and in situ or early invasive squamous cell carcinoma (SCC). Biopsy of genital lichen

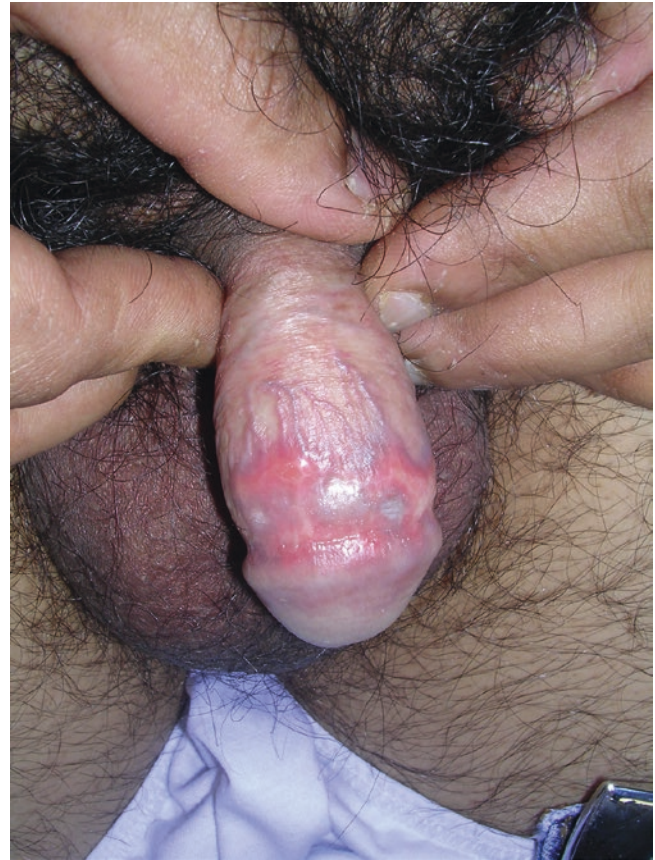

Fig. 20.4 Erosive lichen planus

planus is important to exclude these diseases, particularly in situ SCC. Post-inflammatory hyperpigmentation secondary to genital lichen planus may cause confusion with other pigmented lesions, particularly genital melanotic macules and melanoma [7]. All atypical pigmented genital lesions need a biopsy to exclude melanoma. Patients with genital lichen planus should be screened for underlying hepatitis B and hepatitis C.

20.5 Treatment

Management of male genital lichen planus may be challenging. Sometimes the goal must be control rather than cure [1]. The treatment of choice for all variants of genital lichen planus is an ultrapotent topical corticosteroid. Topical corticosteroids are usually effective in producing partial or complete remission. Alternative topical treatments include calcineurin inhibitors (tacrolimus, pimecrolimus) [8]. A resistant solitary hyperkeratotic plaque of lichen planus usually responds to intralesional corticosteroid. Other options for persistent or resistant genital lichen planus include oral corticosteroids, methotrexate, mycophenolate [9], oral acitretin [2], and cir-

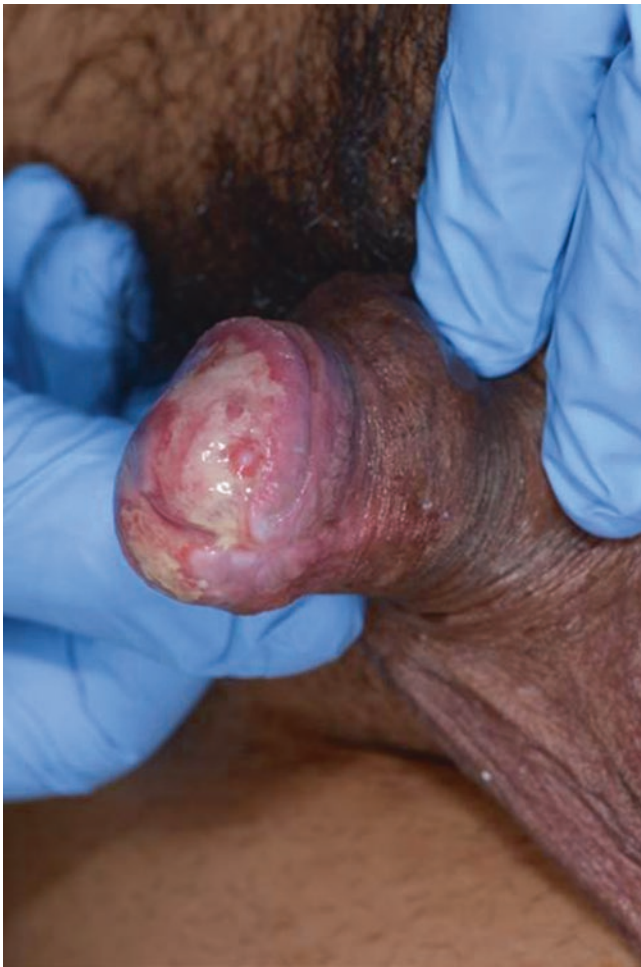

Fig. 20.5 Severe erosive lichen planus

cumcision [10]. Squamous cell carcinoma (SCC), which is associated with chronic cutaneous lichen planus and erosive oral lichen planus, has been reported with genital lichen planus [11, 12]. Whether the association of genital lichen planus with SCC is causal or coincidental is unclear. Regular self-examination to detect penile SCC should be encouraged.

Pearls

- Genital lichen planus may present as a hyperkeratotic plaque, annular lesion(s), lace pattern (Wickham's striae) or as erosive balanoposthitis.
- Management of genital lichen planus is often challenging. Control rather than cure may be the goal.

References

1. Zendell K. Genital lichen planus: update on diagnosis and treatment. *Semin Cutan Med Surg.* 2015;34:182–6.
2. Poon F, De Cruz R, Hall A. Acitretin in erosive penile lichen planus. *Australas J Dermatol.* 2017;58:87–90.
3. Reich HL, Nguyen JT, James WD. Annular lichen planus: a case series of 20 patients. *J Am Acad Dermatol.* 2004;50:595–9.
4. Karthikeyan K, Jeevankumar B, Thappa DM. Bullous lichen planus of the glans penis. *Dermatol Online J.* 2003;9(5):31.
5. Petrucci M, De Benedittis M, Pastore L, Grassi FR, Serpico R. Peno-gingival lichen planus. *J Periodontol.* 2005;76:2293–8.
6. Papageorgiou C, Apalla Z, Lazaridou E, Sotiriou E, Vakirlis E, Ioannides D, Lallas A. Atypical case of lichen planus recognized by dermoscopy. *Dermatol Pract Concept.* 2016;6:39–42.
7. Isbary G, Dyall-Smith D, Coras-Stepanek B, Stolz W. Penile lentigo (genital mucosal macule) following annular lichen planus: a possible association? *Australas J Dermatol.* 2014;55:159–61.
8. Lonsdale-Eccles AA, Velangi S. Topical pimecrolimus in the treatment of genital lichen planus: a prospective case series. *Br J Dermatol.* 2005;152:390–4.
9. Deen K, McMeniman E. Mycophenolate mofetil in erosive genital lichen planus: a case and review of the literature. *J Dermatol.* 2015;42:311–4.
10. Porter WM, Dinneen M, Hawkins DA, Bunker CB. Erosive penile lichen planus responding to circumcision. *J Eur Acad Dermatol Venereol.* 2001;15:266–8.
11. Leal-Khoury S, Hruza GJ. Squamous cell carcinoma developing within lichen planus of the penis. Treatment with Mohs micrographic surgery. *J Dermatol Surg Oncol.* 1994;20:272–6.
12. Bain L, Geronemus R. The association of lichen planus of the penis with squamous cell carcinoma in situ and with verrucous squamous carcinoma. *J Dermatol Surg Oncol.* 1989;15:413–7.

21.1 Definition

Plasma cell balanitis (Zoon's balanitis, balanitis circumscripta plasmacellularis) is a relatively common genital dermatosis of uncircumcised older males characterised by a solitary or mirrored moist, orange-red plaque of the glans and foreskin, with an increase in the number of plasma cells on histology.

21.2 Aetiology

The aetiology is disputed but plasma cell balanitis is thought to arise from mild trauma or irritation of the moist environment of the preputial recess (subprepuce), perhaps a result of the “dysfunctional foreskin” secondary to some unrecognised process [1, 2]. Plasma cell balanitis is probably not a premalignant disease [2].

21.3 Clinical Features

Plasma cell balanitis occurs in uncircumcised, middle-aged to elderly men as a well-defined smooth, shiny, red to orange plaque on the dorsal glans penis (Fig. 21.1). Tan brown spots (“cayenne pepper”) may be seen within the smooth plaque. A mirrored or “kissing” lesion may occur on the mucosal surface of the foreskin (Figs. 21.2 and 21.3) [3]. Plasma cell balanitis is usually asymptomatic and may be detected incidentally by nursing or medical personnel. Symptoms of burning, itch, discharge or bleeding may be reported [3]. Although plasma cell balanitis occurs almost exclusively in uncircumcised men, it has been reported in a circumcised

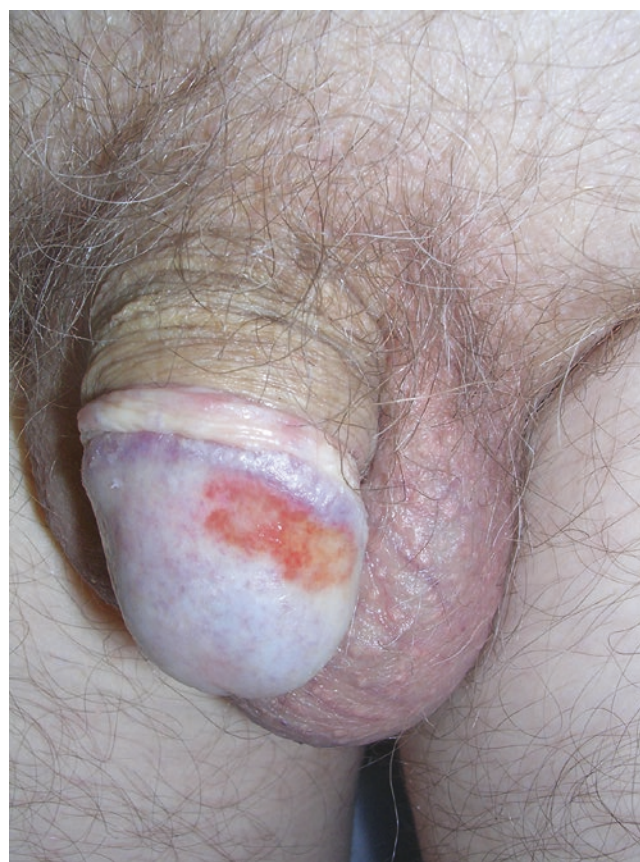

Fig. 21.1 Orange-red moist plaque of plasma cell (Zoon's) balanitis

man [4]. Full clinical examination is important to exclude evidence of psoriasis or lichen planus. Plasma cell balanitis tends to run a chronic course.

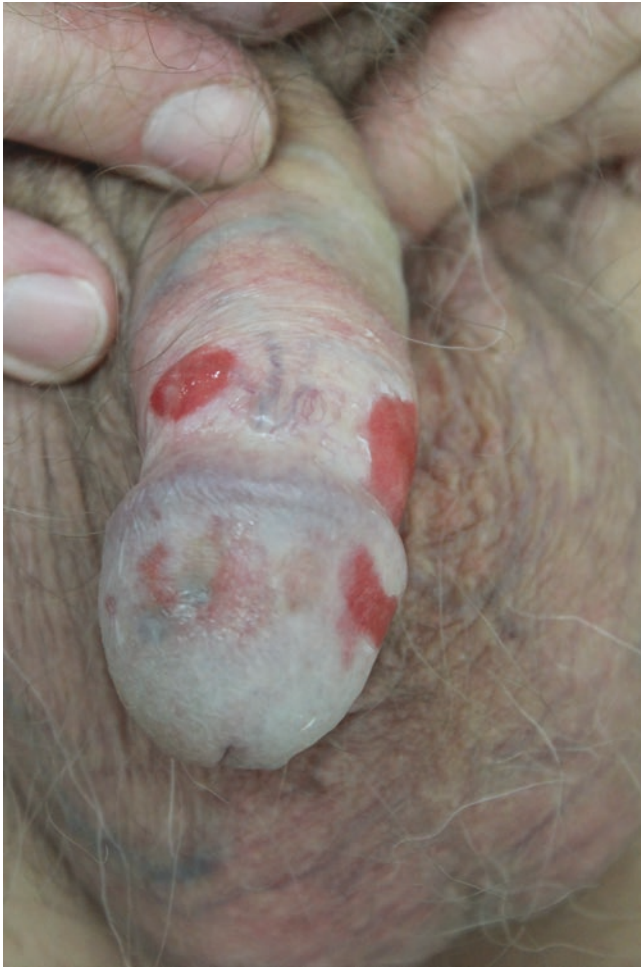

Fig. 21.2 Multiple moist plaques of plasma cell balanitis on the glans and foreskin

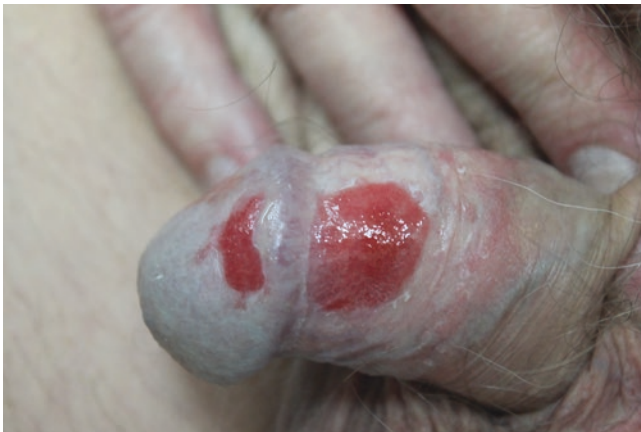

Fig. 21.3 Mirrored or "kissing" lesions of plasma cell balanitis

21.4 Diagnosis

Though many clinicians diagnose plasma cell balanitis based on clinical features, diagnosis is not always easy. Proposed criteria for a clinical diagnosis of plasma cell balanitis [3] require that three of five criteria are met:

- A shiny red patch on the glans, prepuce, or both (Fig. 21.4)
- Lesions present for at least 3 months
- Absence of lesions elsewhere suggestive of lichen planus or psoriasis
- Poor response to topical therapies over 3 months
- Absence of concurrent infection.

Skin biopsy is important, even though histological features may not be diagnostic. Genital skin biopsy helps to exclude lichen sclerosus, lichen planus, and in situ squamous cell carcinoma (SCC). Histological features of plasma cell balanitis include thinning of the epidermis,

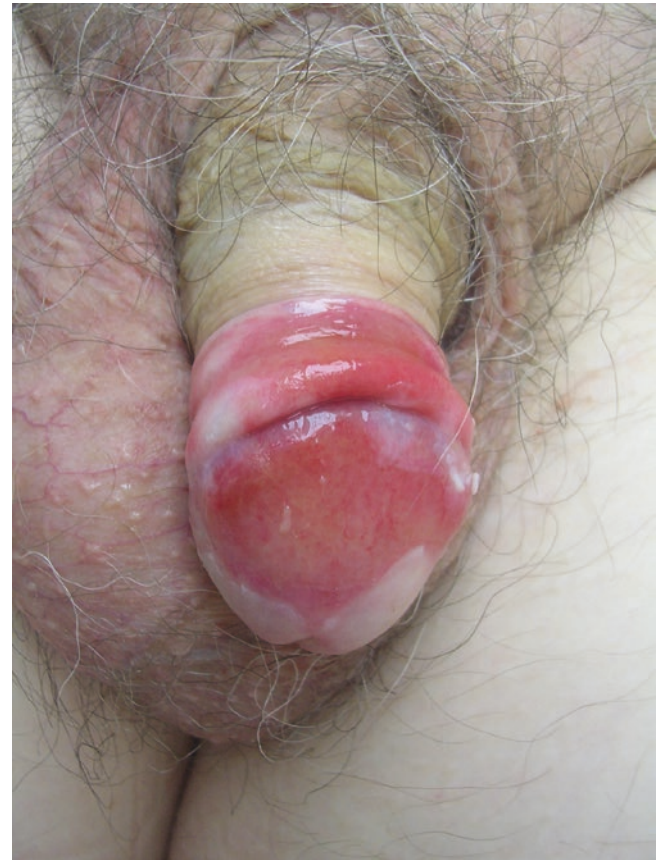

Fig. 21.4 Extensive plasma cell balanitis as balanoposthitis

loss of rete ridges, dense dermal infiltrate composed predominantly of plasma cells, an absent granular layer and a horny layer with sparse dyskeratosis [3, 5]. The histologic presence of plasma cells was part of the original description but the number of plasma cells is variable [1, 5, 6]. Proposed criteria for a histologic diagnosis of plasma cell balanitis [3] require that three of five features are present:

- Spongiosis
- Diamond-shaped or lozenge-shaped basal layer keratinocytes (“lozenge keratinocyte”)
- Dense inflammatory cell infiltrate, in which plasma cells make up at least 50% of the cellular infiltrate
- Vascular proliferation
- Vertically orientated dermal vessels

Differential diagnoses include irritant dermatitis, psoriasis, lichen planus, fixed drug eruption, and in situ SCC.

21.5 Treatment

Circumcision is often considered the “treatment of choice” for plasma cell balanitis [3, 7, 8], but circumcision focuses on the disease while ignoring the patient. Recommending circumcision as the definitive treatment of choice is based on the assumption that plasma cell balanitis is a surgical disease. Usually other treatment options are not offered to the patient. Many older men with plasma cell balanitis are unperturbed by a red to orange plaque on their glans once they are assured that the plaque is benign and not cancer. These men may be ambivalent about circumcision. Increasing age, illness and infirmity are factors weighing against circumcision. Symptomatic treatment may be more appropriate for many of these patients. Clinical improvement can usually be achieved by use of a potent topical corticosteroid [9]. Alternative treatments include topical fusidic acid [10], topical tacrolimus [11] or laser treatment [8]. Combining a topical antibiotic with a potent topical corticosteroid usually results in quicker and more complete resolution. As plasma cell balanitis tends to run a chronic course, treatment with a topical antibiotic combined with a topical corticosteroid may

need to be repeated with each relapse. Circumcision is best reserved for patients who fail topical medical treatment or who request a permanent solution.

Pearls

- Plasma cell (Zoon’s) balanitis may be a reaction pattern rather than a true disease.
- Symptomatic treatment of plasma cell balanitis may be preferable to circumcision for elderly patients.
- Circumcision is not necessarily the treatment of choice for all patients with plasma cell balanitis.

References

1. Weyers W, Ende Y, Schalla W, Diaz-Cascajo C. Balanitis of Zoon: a clinicopathologic study of 45 cases. *Am J Dermatopathol*. 2002;24:459–67.
2. Porter WM, Bunker CB. The dysfunctional foreskin. *Int J STD AIDS*. 2001;12:216–20.
3. Kumar B, Narang T, Dass Radotra B, Gupta S. Plasma cell balanitis: clinicopathologic study of 112 cases and treatment modalities. *J Cutan Med Surg*. 2006;10:11–5.
4. Toker SC, Baskan EB, Tunalı S, Yilmaz M, Karadogan SK. Zoon’s balanitis in a circumcised man. *J Am Acad Dermatol*. 2007;57(2 Suppl):S6–7.
5. Bunker CB, Neill SM. The genital, perianal and umbilical regions. In: Burns T, Breathnach S, Cox N, Griffiths C, editors. *Rook’s textbook of dermatology*, vol. 68. 7th ed. Hoboken: Wiley-Blackwell; 2008. p. 18.
6. Erdogan BS, Demirkan N, Aktan S, Ergin S, Evliyaoglu D. A focus on differential diagnosis of lichen planus and plasma cell balanitis. *J Eur Acad Dermatol Venereol*. 2006;20:746–8.
7. Kumar B, Sharma R, Rajagopalan M, Radotra BD. Plasma cell balanitis: clinical and histopathological features--response to circumcision. *Genitourin Med*. 1995;71:32–4.
8. Retamar RA, Kien MC, Chouela EN. Zoon’s balanitis: presentation of 15 patients, five treated with a carbon dioxide laser. *Int J Dermatol*. 2003;42:305–7.
9. Tang A, David N, Horton LW. Plasma cell balanitis of Zoon: response to Trimovate cream. *Int J STD AIDS*. 2001;12:75–8.
10. Petersen CS, Thomsen K. Fusidic acid cream in the treatment of plasma cell balanitis. *J Am Acad Dermatol*. 1992;27:633–4.
11. Moreno-Arias GA, Camps-Fresneda A, Llaberia C, Palou-Almerich J. Plasma cell balanitis treated with tacrolimus 0.1%. *Br J Dermatol*. 2005;153:1204–6.

22.1 Definition

Candidiasis is inflammation of the anogenital skin produced by yeasts of the genus *Candida*, mostly *Candida albicans*.

22.2 Aetiology

Both host and microbe factors are important in anogenital candidiasis. *Candida albicans* is a yeast organism that colonises normal genital skin and may become an opportunistic pathogen. While *Candida* species can produce a wide range of human disease in susceptible hosts, candidiasis is mostly a mucocutaneous disease. *Candida albicans* has been isolated from the glans penis of asymptomatic males [1] and from the vagina of asymptomatic women. Important host factors in genital candidiasis include being uncircumcised (presence of foreskin), other genital skin disease (phimosis, dermatitis, lichen sclerosus), obesity, increasing age, poorly controlled diabetes mellitus, the presence of a urinary catheter, use of oral antibiotics, local immunosuppression with topical corticosteroids, HIV infection, and systemic immunosuppression [2]. Sexual transmission has been overemphasised [3].

22.3 Clinical Features

Candidiasis usually presents as balanoposthitis in uncircumcised men. Candidiasis only rarely occurs as balanitis in circumcised, immunocompetent men. Itch, soreness, irritation and subpreputial discharge are common symptoms [4]. Itch and soreness may occur only after intercourse or may be aggravated by intercourse, particularly in partners of women with recurrent vulvovaginal candidiasis. Both redness of glans and foreskin (balanoposthitis) or redness of the glans penis only if circumcised (balanitis) are common presentations of male genital candidiasis (Figs. 22.1 and 22.2). Vesicles and white plaques may be seen on the glans with edema or

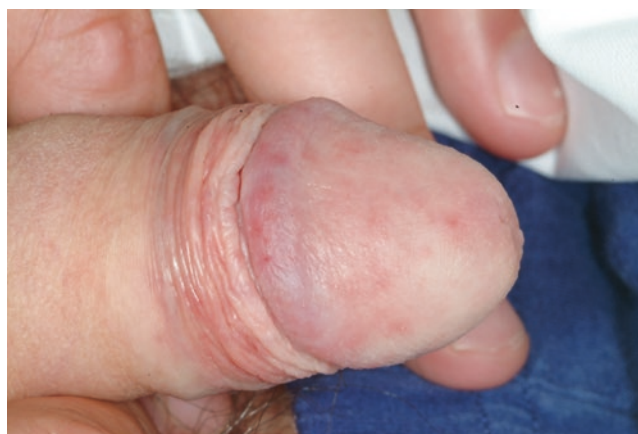

Fig. 22.1 Candidal balanoposthitis

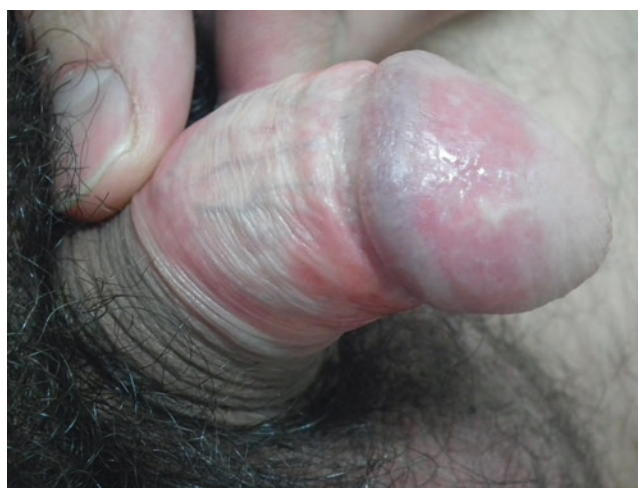

Fig. 22.2 Candidal balanoposthitis

scaliness of the foreskin. More extensive disease involves the entire genitalia, groins and proximal inner thighs (Figs. 22.3 and 22.4). Well-demarcated, thin, erythematous plaques bor-



Fig. 22.3 Candidal intertrigo of the groins and scrotum

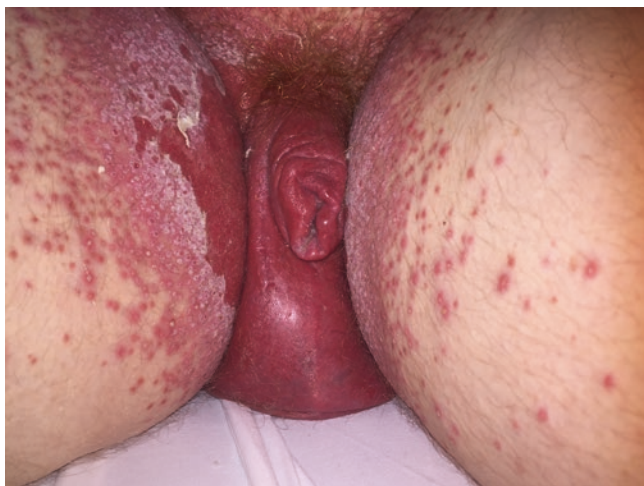

Fig. 22.4 Severe candidal infection affecting the entire genitalia, groins, and inner thighs of an obese diabetic man

dered with characteristic peripheral macules and papules (“satellite lesions”) may be seen.

22.4 Diagnosis

Identification of yeast from a skin swab for microscopy (identification of hyphae, pseudohyphae or budding yeast cells) or culture is necessary to confirm the diagnosis. Often balanitis or balanoposthitis is assumed to be candidiasis but *Candida* is identified in only one third of these patients [5]. Important differential diagnoses include irritant dermatitis (more common than candidal balanitis or balanoposthitis), psoriasis, lichen sclerosus, lichen planus, plasma cell balani-

tis and in situ squamous cell carcinoma (SCC). If the clinical diagnosis is uncertain, genital skin biopsy should be considered. Histological examination of the biopsy specimen should include a stain for fungi (periodic acid–Schiff [PAS] stain) to demonstrate yeast cells, hyphae, or pseudohyphae in the stratum corneum.

22.5 Treatment

It is important to identify host risk factors and treat any underlying disease, including poorly controlled diabetes mellitus. Dilute white-vinegar soaks may be used to provide symptomatic relief. Cool hip (Sitz) baths with saline or dilute white vinegar are soothing for more extensive involvement of groins and inguino-scrotal folds, particularly if there is crusting or weeping.

Both topical imidazole and oral azole treatment are effective for male genital candidiasis. For milder disease, a topical imidazole cream such as miconazole, clotrimazole, or ketoconazole applied twice daily for 7–10 days is usually sufficient. Combining a low-potency topical corticosteroid cream (eg, 1% hydrocortisone) with the topical imidazole cream is more effective. Use of a low-potency topical corticosteroid reduces inflammation and may help to treat any underlying genital dermatosis (eg, irritant dermatitis). Topical nystatin and gentian violet are used less commonly for male genital candidiasis, being superseded by topical imidazoles. Oral fluconazole (a triazole drug) is increasingly being used for male genital candidiasis, particularly for diabetic or catheterized patients. Usually fluconazole 100 mg once-weekly for 2–4 weeks is adequate. Female sex partners with vulvovaginal candidiasis need to be treated with an imidazole vaginal cream or suppository for 6–7 nights. A single 150-mg dose of oral fluconazole is often adequate for vulvovaginal candidiasis. For more severe or resistant male genital candidiasis, a higher dose of oral fluconazole for a longer duration may be necessary, such as 100 to 200 mg once or twice weekly for 2–6 weeks. Immunosuppressed patients may need an even higher dose of fluconazole (400 mg once daily) for up to 6 weeks.

Pearls

- Male genital candidiasis usually presents as balanoposthitis in uncircumcised men. It is rarely seen in circumcised men.
- Balanoposthitis is commonly assumed to be candidiasis but is usually irritant dermatitis instead.

References

1. Lisboa C, Santos A, Dias C, Azevedo F, Pina-Vaz C, Rodrigues A. Candida balanitis: risk factors. *J Eur Acad Dermatol Venereol*. 2010;24:820–6.
2. Fernandes MS, Bhat RM. Spectrum of mucocutaneous manifestations in human immunodeficiency virus-infected patients and its correlation with CD4 lymphocyte count. *Int J STD AIDS*. 2015;26:414–9.
3. Lisboa C, Costa AR, Ricardo E, Santos A, Azevedo F, Pina-Vaz C, Rodrigues AG. Genital candidosis in heterosexual couples. *J Eur Acad Dermatol Venereol*. 2011;25:145–51.
4. Working Group of the British Society for Medical Mycology. Management of genital candidiasis. *BMJ*. 1995;310:1241–4.
5. Dockerty WG, Sonnex C. Candidal balanoposthitis: a study of diagnostic methods. *Genitourin Med*. 1995;71:407–9.

23.1 Definition

Tinea or *dermatophytosis* is a superficial infection of skin with dermatophytic fungi. *Tinea cruris* is a dermatophyte infection of the inguinal region or groin, which may extend onto the proximal medial thighs.

23.2 Aetiology

Dermatophytic fungi grow on dead epidermal cells (stratum corneum) of fully keratinised skin, so they produce only superficial infection in immunocompetent patients. Dermatophytic fungal infections are very common and widespread throughout the world. Mucosal surfaces are usually spared but rarely may be involved. The commonest dermatophytic fungi (dermatophytes) causing *tinea cruris* are *Trichophyton rubrum*, *Epidermophyton floccosum* and *Trichophyton mentagrophytes*. *Trichophyton tonsurans* is seen in tropical climates. Friction, sweating, diabetes mellitus, obesity and hot, humid climates are all predisposing factors. The most important factor is autologous transmission of tinea infection of the feet (*tinea pedis*) or toenails (*tinea unguium*) to the groin (*tinea cruris*). Tinea infection of the feet or toenails is usually acquired from wet surfaces harbouring the dermatophytic fungus, that is then spread to groins by hand, clothing or towels. Tinea cruris is far more common in men than in women. Nearly all fungal species can cause mycotic infection of male genitalia in immunocompromised patients [1].

23.3 Clinical Features

Tinea cruris is mostly a disease of adult males. Dermatophytic fungi commonly infect men regardless of body type, but tinea is more common in obese or diabetic adult males. Tinea

cruris often results in itch, irritation and scaling but may be asymptomatic. Itch and irritation may worsen with increased sweating (eg, exercise) or humidity. Symmetrical red, flat, scaly plaques with a well-defined annular or serpiginous border extending from groins with central clearing are characteristic (Figs. 23.1 and 23.2). Tinea cruris often extends onto proximal medial thighs but usually spares the scrotum and penile shaft (Fig. 23.3); true tinea of the glans penis or penile

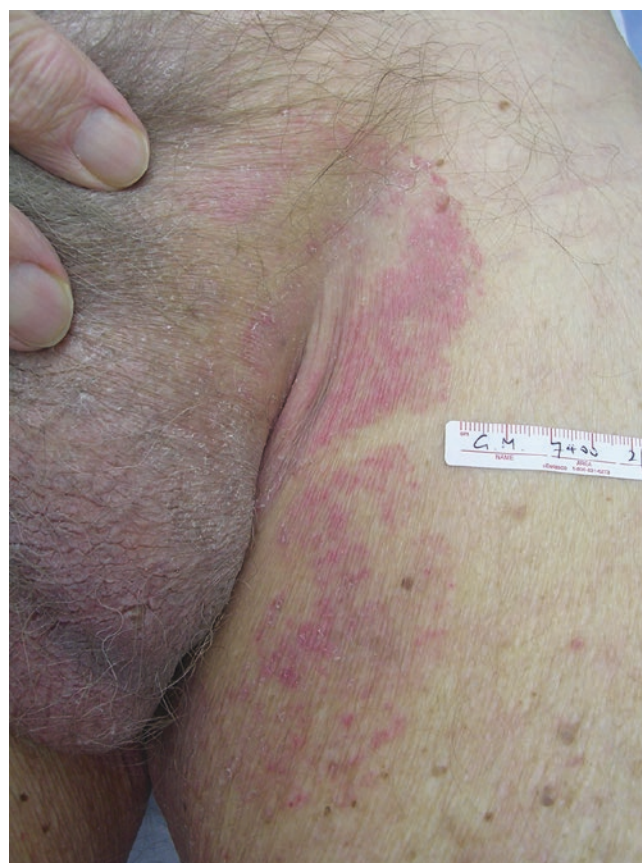

Fig. 23.1 Tinea cruris sparing the scrotum

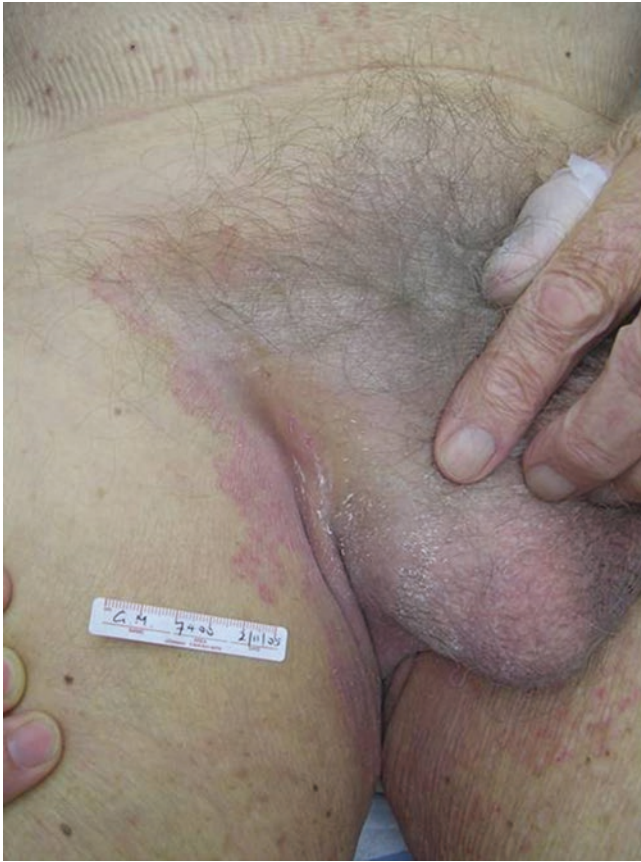

Fig. 23.2 Tinea cruris sparing the scrotum

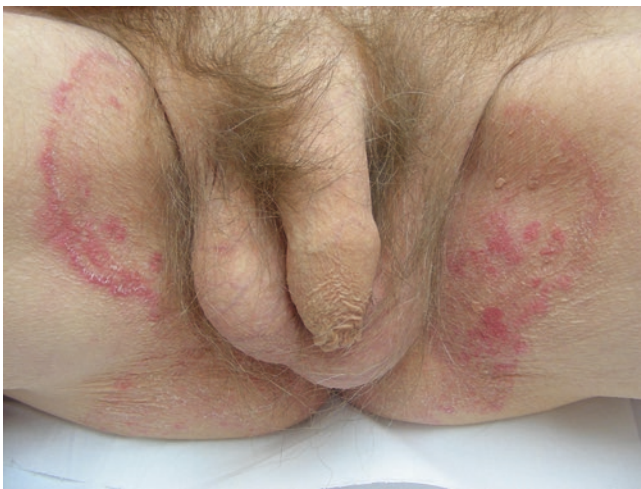

Fig. 23.3 Tinea cruris extending onto inner thighs but sparing the genitalia

shaft is extremely rare [1]. More extensive tinea cruris may extend to buttocks or be quite widespread on the trunk (tinea corporis). The clinical sign of erythema is often lost in “skin of color” adult males but hyperpigmentation is more appar-

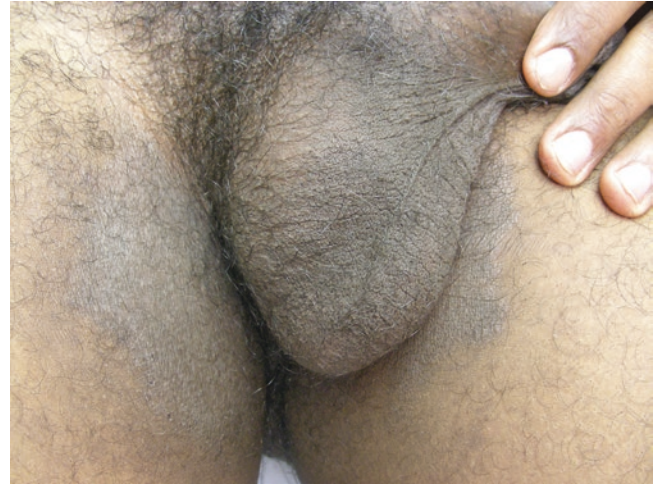

Fig. 23.4 Tinea cruris sparing the scrotum of an adult male (Fitzpatrick skin phototype 4)

ent (Fig. 23.4). The clinical appearance of tinea cruris may be altered by prior treatment with either a topical corticosteroid (tinea incognito) or a topical antifungal preparation. Sometimes the clinical appearance is dominated by secondary bacterial infection (impetiginisation). Tinea cruris is often associated with tinea of the feet (tinea pedis) or toenails (tinea unguium, onychomycosis), so careful examination of the feet and toenails is important.

23.4 Diagnosis

Confirmation of clinical diagnosis is by skin scraping for microscopy and culture. Bedside microscopic examination of skin scrapings is made easier with application of 10% or 20% potassium hydroxide (KOH) solution and identification of branching hyphae. Clinical examination of the groins (and axillae) with the Wood’s lamp helps to exclude erythrasma. Skin biopsy is important if other flexural sites are involved, if tinea cruris is persistent or resistant, or rarer possibilities cannot be confidently excluded. Staining of the histological specimen with special stains such as periodic acid–Schiff (PAS) stain is necessary to identify dermatophytes. Nail clippings for microscopy and culture are important if there is suspicion of fungal infection (tinea unguium, onychomycosis). Exclusion of diabetes mellitus by blood glucose is important if suspected.

Common differential diagnoses include irritant dermatitis (“jock itch,” “intertrigo”), flexural psoriasis, candidiasis and erythrasma. Rarer differential diagnoses include extramammary Paget’s disease, acanthosis nigricans, Hailey-Hailey disease or flexural Darier’s disease.

23.5 Treatment

General measures include attempting to keep groins dry after showering or swimming. Wearing of less irritating or occlusive underwear may be beneficial. Early treatment of tinea pedis and tinea unguium is very important to prevent the spread of tinea to groins. Topical treatment with an imidazole cream (*eg*, clotrimazole 1%) or topical allylamine (*eg*, terbinafine 1% cream) may be adequate for tinea cruris, but combination with a systemic antifungal agent results in a greater cure rate. Appropriate systemic antifungal agents include oral griseofulvin (500 mg daily for 4–6 weeks) or oral terbinafine (250 mg daily for 2–4 weeks). Oral itraconazole or fluconazole are alternative systemic antifungal treatments.

Pearls

- Tinea of groins (tinea cruris) usually spares scrotum and penis
- If tinea cruris, exclude tinea of feet or toenails
- Differentiate tinea cruris from irritant dermatitis, flexural psoriasis, candidiasis and erythrasma.

Reference

1. Mayser P. Mycotic infections of the penis. *Andrologia*. 1999;31(Suppl 1):13–6.

24.1 Definition

Herpes genitalis is infection of the genital skin with herpes simplex virus (HSV), usually HSV-2 virus.

24.2 Aetiology

Herpes simplex virus (HSV) is a double-stranded DNA virus of the alpha herpes group. Herpes simplex virus type 1 (HSV-1) mainly involves the oral region, while herpes simplex virus type 2 (HSV-2) predominantly involves the genital region, but both HSV-1 and HSV-2 can cause genital infection. Transmission is via close body contact. Genital herpes infection is an important sexually transmissible infection (STI) worldwide. Transmission of HSV to newborns may occur during birth from infected mothers. Most primary genital infections are asymptomatic. Following primary infection, HSV invades and replicates in the nervous system. Following a variable latency period, HSV reactivates at the site of primary infection. Most infections with HSV-2 start after commencement of sexual activity and increase with age and number of sexual partners. Prior infection with HSV-1 attenuates the severity of symptoms of genital infection with HSV-2. Triggers to reactivation are not always recognised. Immunosuppressed patients experience more frequent episodes and more severe infections. Rarely, HSV can disseminate in immunosuppressed patients with a solid organ transplant or HIV infection. Genital erosions or ulceration caused by herpes genitalia are important portals for transmission of HIV.

24.3 Clinical Features

While most primary genital infections are asymptomatic, male patients with herpes genitalis may complain of quite severe pain, dysuria or urethral discharge. The first clinical episode of herpes genitalis usually presents as acute red pap-

ules, vesicles or erosions on the glans, foreskin or penile shaft (Figs. 24.1, 24.2, 24.3, 24.4, and 24.5). A sensation of burning or stinging may precede appearance of papulo-vesicles or erosions. Some patients present with secondary crusting of erosions. HSV is the commonest cause of genital ulceration in developed countries [1]. Painful vesiculation

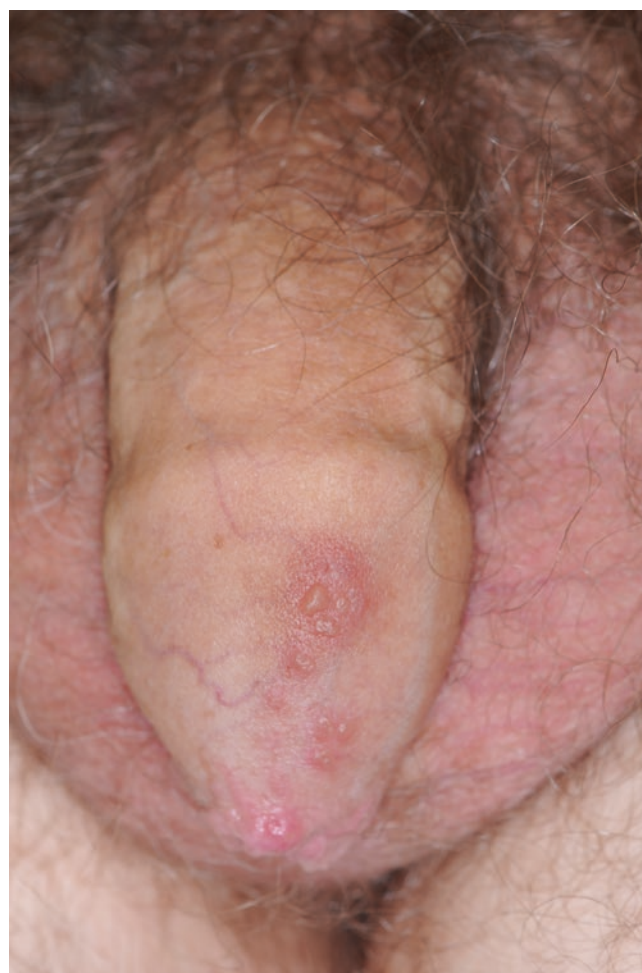

Fig. 24.1 Acute clustered vesicles on an erythematous base of genital herpes

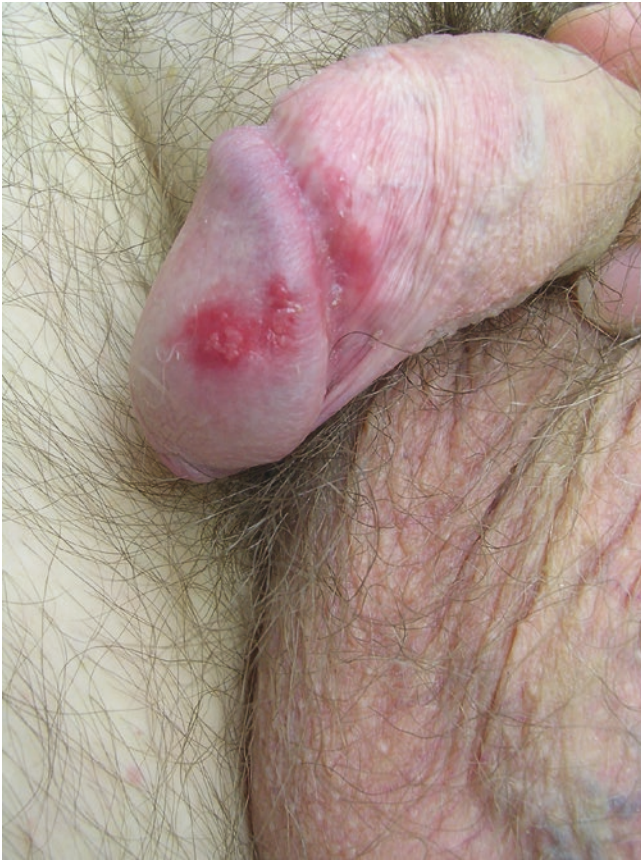

Fig. 24.2 Clustered vesicles of genital herpes on the glans

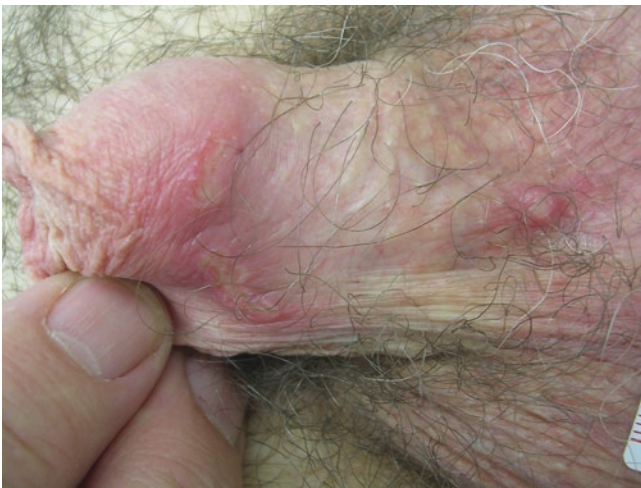

Fig. 24.3 Erosions after vesicles have ruptured

and erosions may be more extensive and associated with dysuria, inguinal lymphadenopathy or systemic symptoms (fever, myalgias, or photophobia).

Confusion arises with first clinical episode of genital herpes. While primary genital HSV infections may be quite severe, most primary HSV infections are asymptomatic. The first clinical episode of genital herpes is usually reactivation

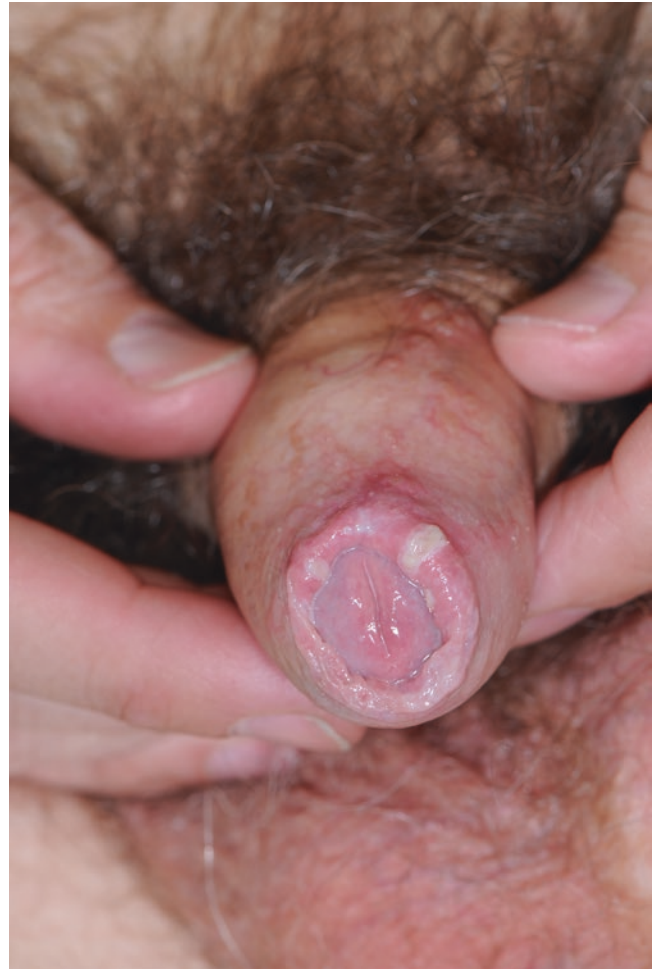

Fig. 24.4 Herpetic erosions as balanoposthitis

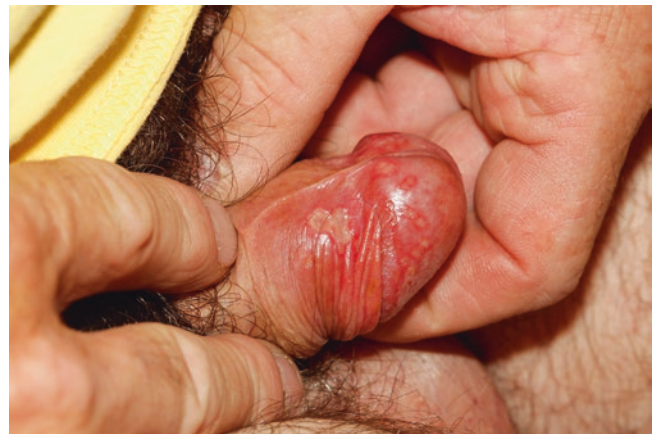

Fig. 24.5 Erosions of glans and mucosal aspect of the foreskin (Courtesy of Dr. E. Tan)

of HSV, not a primary infection [1]. The first clinical episode (reactivation) and recurrent episodes of genital herpes are often more localised than the primary infection, with asymmetric distribution, shorter duration and an absence of systemic symptoms. Resolution of each episode of genital

herpes usually occurs within 10–14 days in immunocompetent patients. Immunosuppressed patients have more severe lesions (plaques, nodules, ulcers) that are more persistent. Recurrent episodes are common in the first 12 months after primary infection. The frequency of recurrent episodes wanes after the first 12 months, but many patients continue to experience episodes of genital herpes over many years.

24.4 Diagnosis

Confirmation of clinical diagnosis is important for management. A skin swab should be taken from vesicle fluid or the base of an erosion for HSV polymerase chain reaction (PCR) testing. Viral culture was previously the gold standard for HSV detection but is rarely performed today in clinical practice. PCR testing is practical and useful for the diagnosis of genital herpes [2], with high sensitivity and specificity [3]. A skin biopsy from a vesicle or ulcer may be useful if viral DNA testing is not possible. Histology does not routinely distinguish between HSV-1, HSV-2, or varicella zoster virus (VZV). Type-specific serology can distinguish between HSV-1 and HSV-2 but cannot distinguish a primary infection from recurrent infection or differentiate oral from genital HSV infection [3]. Type-specific serology is not routinely used for management of genital HSV infections [4] but may be clinically useful if a patient wants to know if they are at risk of acquiring HSV from a partner with a prior history of genital herpes.

Important differential diagnoses of genital ulceration include both infectious (eg, syphilis, chancroid) and non-infectious causes (eg, aphthae, Behçet's disease). Genital herpes may have atypical presentations in immunosuppressed patients (eg, persisting plaque). Screening for other sexually transmissible diseases is important, particularly syphilis, hepatitis B, hepatitis C, chlamydia, and HIV.

24.5 Treatment

Management of a patient with genital herpes includes issues of making an accurate diagnosis, questions of the source of infection, symptomatic treatment and antiviral therapy for

both acute and recurrent episodes. Guilt, distress and disruption of existing relationships often accompany episodes of genital herpes. Sexual activity should be avoided during flares of herpes genitalis, but asymptomatic shedding is common. Use of condoms should be discussed. A hip (Sitz) bath with saline or dilute white vinegar, oral analgesics, and short-term use of a topical local anesthetic cream or gel help to provide symptomatic relief.

Specific antiviral therapy with either acyclovir or the longer-acting prodrugs valaciclovir and famciclovir reduces the severity and duration of each episode but does not eradicate HSV [3]. Options of treatment for the first clinical episode include aciclovir (400 mg three times daily for 5–10 days), valaciclovir (500 mg twice daily for 5–10 days) or famciclovir (250 mg three times daily for 5–10 days). Recurrent outbreaks of herpes are best treated with intermittent antiviral therapy. Long-term suppressive therapy is beneficial if recurrent episodes are frequent, especially if episodes of genital herpes occur more than six times per year.

Pearls

- Herpes genitalis is the commonest cause of genital ulceration.
- The first clinical episode of herpes genitalis is usually a reactivation and not the primary infection
- Guilt, distress and disruption of relationships often accompany genital herpes.

References

1. Brown TJ, Yen-Moore A, Tyring SK. An overview of sexually transmitted diseases. Part 1. *J Am Acad Dermatol*. 1999;41:511–29.
2. Strick LB, Wald A. Diagnostics for herpes simplex virus: is PCR the new gold standard? *Mol Diagn Ther*. 2006;10:17–28.
3. Sen P, Barton SE. Genital herpes and its management. *BMJ*. 2007;334:1048–52.
4. Goldman BD. Herpes serology for dermatologists. *Arch Dermatol*. 2000;136:1158–61.

25.1 Definition

Genital warts (condyloma acuminata) are a common, sexually transmissible viral infection of ano-genital skin caused by certain types of the human papillomavirus (HPV).

25.2 Aetiology

Human papillomaviruses (HPV) are double-stranded DNA viruses. Over 100 types of HPV exist but only about one third infect genital skin. HPV type 6 (HPV-6) and HPV type 11 (HPV-11) are both “low-risk” HPV strains associated with ano-genital warts. “High-risk” HPV strains including HPV type 16 (HPV-16) and HPV type 18 (HPV-18) are not commonly associated with ano-genital warts but are associated with penile intraepithelial neoplasia (Bowenoid papulosis, in situ squamous cell carcinoma [SCC], erythroplasia of Queyrat) and squamous cell carcinoma (SCC) of the penis. Host factors for ano-genital warts include early onset of sexual activity, multiple sex partners, unprotected intercourse (not using condoms), and immunosuppression, including untreated HIV infection.

25.3 Clinical Features

Genital warts are mostly asymptomatic, slightly scaly (verrucous) papules detected on self-examination. They vary from a solitary papule (Fig. 25.1) to multiple papules (Fig. 25.2). Genital warts may be flat, smooth, have a rough texture (verrucous) or appear cauliflower-like. Genital warts are often skin-coloured but pigmented papules may occur in patients with darker skin (Fig. 25.3). They are usually few in number (1–10 papules) (Fig. 25.4), but they may present as a florid collection of verrucous papules, plaques or nodules (Fig. 25.5). Genital warts may be detected only when a sex-

ual partner reports an HPV infection. Commonest sites are the glans penis, foreskin or penile shaft. Genital warts may occur in the urethral meatus (Fig. 25.6) or in suprapubic and perianal regions. The nodules or plaques of genital warts tend to be larger and more widely distributed in patients who are immunosuppressed or have untreated HIV infection.

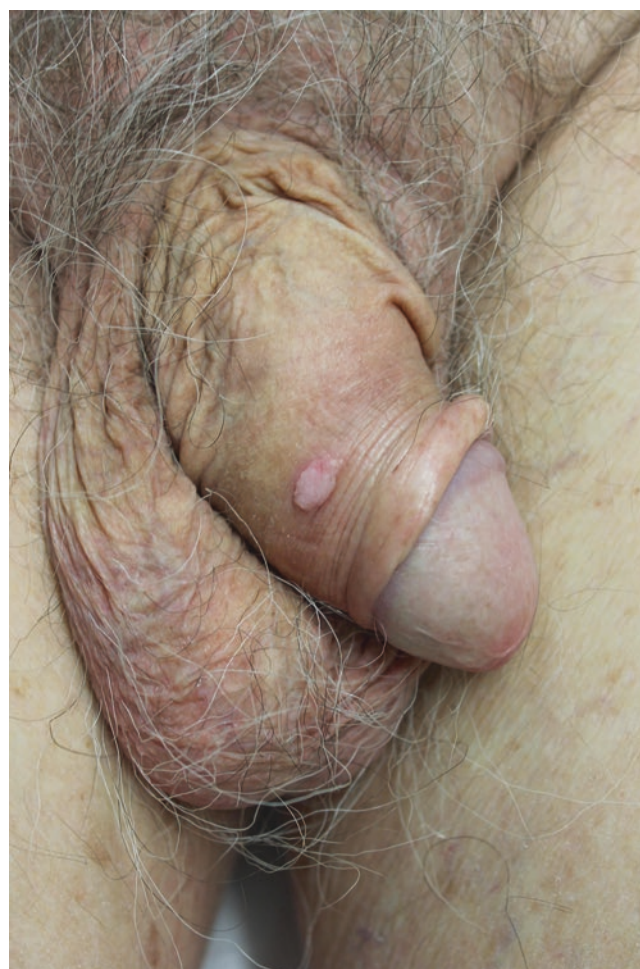


Fig. 25.1 Solitary genital wart

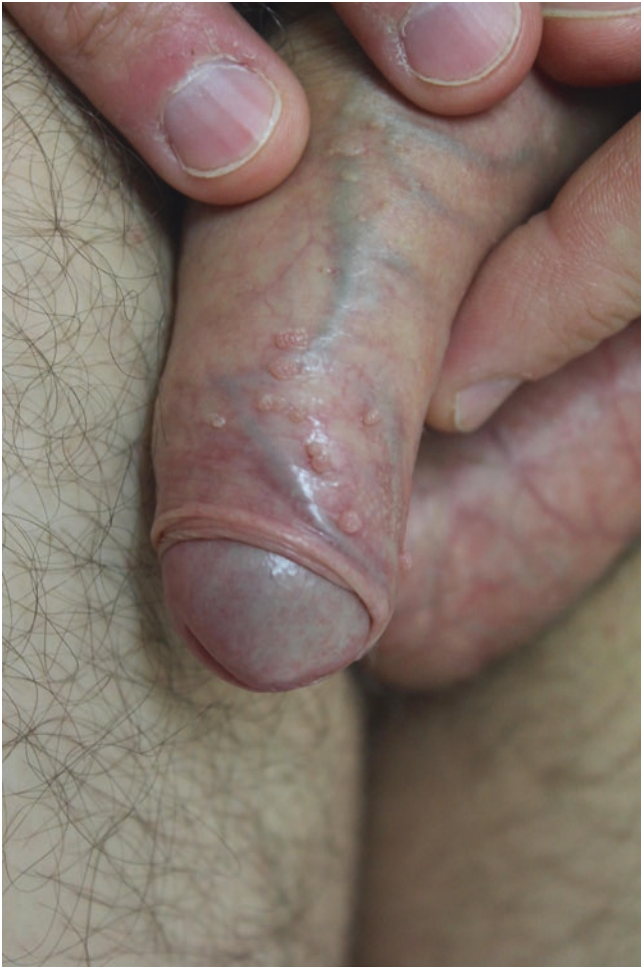

Fig. 25.2 Multiple small genital warts on the mucosal aspect of the foreskin

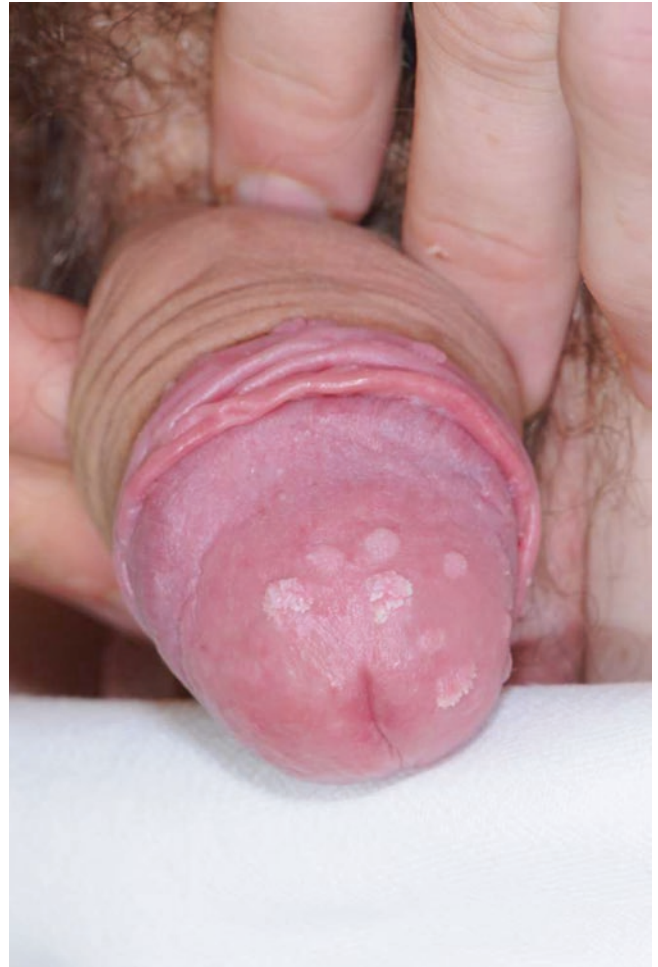

Fig. 25.4 Multiple genital warts on the glans

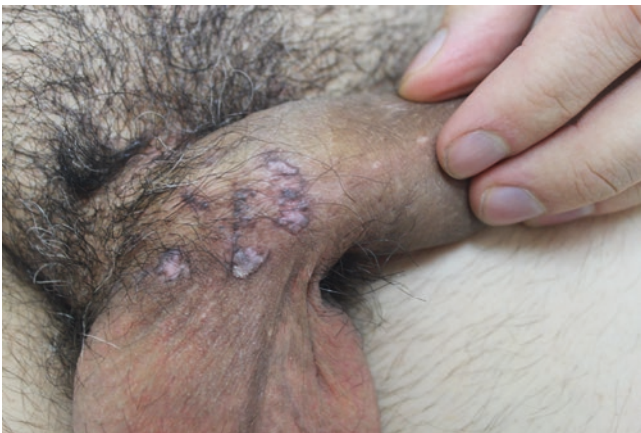

Fig. 25.3 Pigmented genital warts on the penile shaft

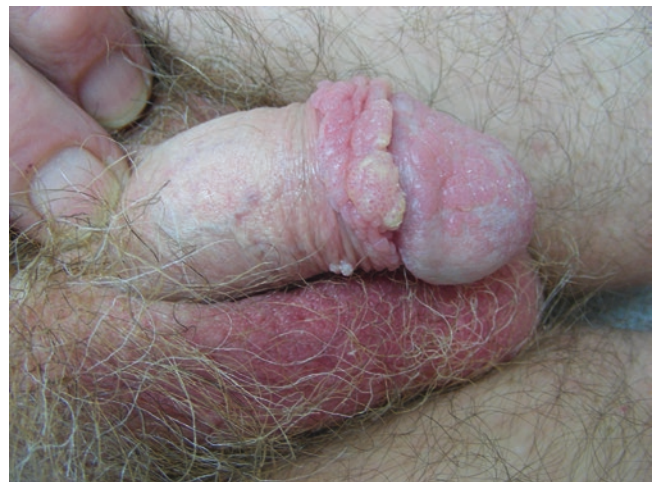

Fig. 25.5 Multiple genital warts on the glans and foreskin

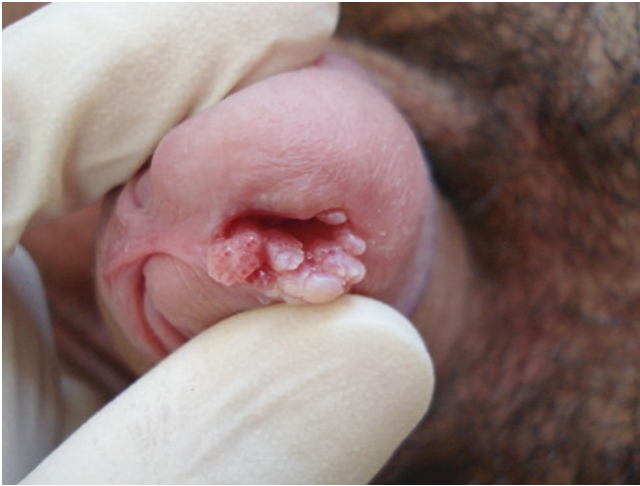

Fig. 25.6 Cluster genital warts at the urethral meatus

25.4 Diagnosis

Diagnosis of genital warts is usually clinical but genital biopsy is important if the lesions are atypical or if the diagnosis is uncertain. Seborrhoeic keratoses, bowenoid papulosis, and in situ squamous cell carcinoma (penile intra-epithelial neoplasia) need to be differentiated from genital warts. Multiple non-pigmented seborrhoeic keratoses, molluscum contagiosum, and pearly penile papules have all been wrongly diagnosed and treated as genital warts. Condylomata lata (secondary syphilis), non-melanoma skin cancers, and melanoma are important differential diagnoses not to be missed.

25.5 Treatment

Management of patients with genital warts may be straightforward or complicated and challenging. Genital warts may result in great distress and require multiple treatment sessions that can be uncomfortable. Infections with HPV are a major health and economic burden worldwide. General measures include screening for other sexually transmissible diseases. Female partners of infected male patients should be encouraged to have a Papanicolaou (Pap) smear or newer HPV DNA testing of cervical cells.

Specific treatment is aimed at eliminating both the clinical genital warts and the subclinical HPV infection with as little pain and scarring as possible. Choice of treatment is based on experience, efficacy, availability and cost. Physician-delivered treatments include cryotherapy, electrocautery, curettage under local anaesthesia and laser destruction. For cryotherapy treatment, liquid nitrogen is applied for 5–15 seconds with two to three repeat cycles, depending on the patient's tolerance to pain. Alternative treatments include topical podophyllin and snip

excision of pedunculated genital warts. Treatments that the patient can apply himself include topical podophyllotoxin and topical imiquimod. Topical podophyllotoxin cream, gel, or solution is applied to genital warts twice daily on 3 consecutive days per week for up to 4 weeks. Topical imiquimod 5% cream is applied to genital warts once daily three times per week for up to 16 weeks. Topical imiquimod 3.75% cream is used once daily for 8 weeks. Use of topical imiquimod is more difficult for uncircumcised patients. Adverse reactions include a marked inflammatory response and a generalised flu-like illness that may require cessation of treatment. Other patient administered treatments include topical trichloroacetic acid, topical sinecatechins ointment (green tea leaf extract), topical retinoids and topical 5-fluorouracil. Warts on the ventral frenulum (underneath the foreskin) or urethral meatal warts are more difficult to treat. Most genital warts respond to repeated cryotherapy in the office combined with self-administered topical imiquimod at home. This process may need to be repeated every few weeks. Patience, persistence, positivity with a supportive approach is more likely to result in a positive outcome for the patient. Patients with genital warts resistant to cryotherapy with self-administered topical therapy may need to be treated with curettage or diathermy under local anaesthesia. Patients with extensive and profuse ano-genital warts often need curettage or cautery under general anaesthesia. Men who have sex with men (MSM) and are HIV-positive with perianal warts require examination of the anal canal to exclude anal intraepithelial neoplasia (AIN) or invasive squamous cell carcinoma (SCC) [1].

Prevention of HPV infection is possible with HPV vaccination. Vaccination is indicated for all young adolescent men and women and any person at risk of HPV-related anal cancer.

Pearls

- Genital warts usually respond to repeated cryotherapy with self-administered topical treatments. Patience, persistence, positivity, and a multimodality approach are needed to treat genital warts.
- Acquisition and transmission of HPV infection is reduced by HPV vaccination prior to sexual exposure.

Reference

1. Schlecht HP, Fugelso DK, Murphy RK, Wagner KT, Doweiko JP, Proper J, et al. Frequency of occult high-grade squamous intraepithelial neoplasia and invasive cancer within anal condylomata in men who have sex with men. *Clin Infect Dis*. 2010;51:107–10.

26.1 Definition

Molluscum contagiosum is a common, benign viral skin infection resulting in small, umbilicated papules.

26.2 Aetiology

Molluscum contagiosum virus is a DNA pox virus infecting humans. The incubation period is generally 2–7 weeks, but a longer incubation period may occur. Four types of molluscum contagiosum virus have been identified, with type 1 the cause of most typical molluscum contagiosum cutaneous papules, whereas type 2 causes most infections in HIV patients. Transmission is probably by direct skin contact or water in bathing or swimming pools. Most infections with molluscum contagiosum occur in immunocompetent children by non-sexual transmission. Childhood infection with molluscum contagiosum acquired non-sexually is common worldwide. Molluscum contagiosum infections of the anogenital region, lower abdomen, and buttocks are acquired mostly by sexual transmission in immunocompetent adults. Autoinoculation with pubic shaving may further spread molluscum. Adult infection with molluscum contagiosum is becoming more common with the rise in HIV infection, with more adults receiving organ transplants and more patients on immunosuppressive treatment for various diseases.

26.3 Clinical Features

The characteristic lesion of molluscum contagiosum is an asymptomatic, non-tender, small (2–3 mm), skin-coloured papule with a central depression (umbilication). Most molluscum contagiosum infection in childhood (acquired non-sexually) results in clusters of varying numbers of small umbilicated papules on the face, trunk or limbs. Anogenital molluscum contagiosum may be seen in children but is usually not sexually acquired. Genital molluscum contagiosum

in adult males mostly involves the penile shaft (Figs. 26.1, 26.2, and 26.3) but may extend onto the inner thighs, consistent with sexual transmission. In immunosuppressed adults, the clinical appearance of molluscum contagiosum is more variable, with larger and more numerous papules,

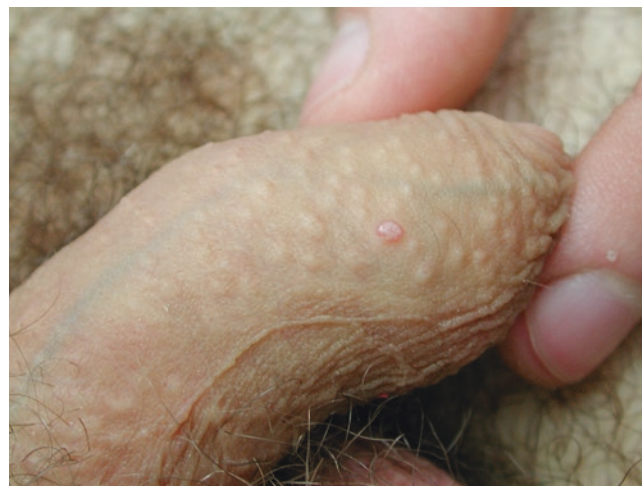

Fig. 26.1 Solitary molluscum contagiosum on the penile shaft

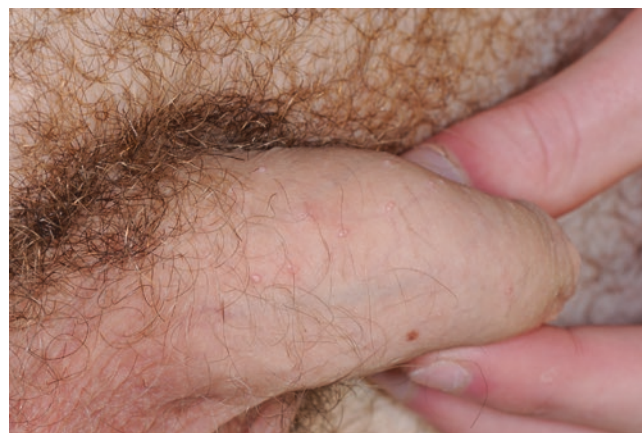

Fig. 26.2 Multiple molluscum contagiosum on the penile shaft

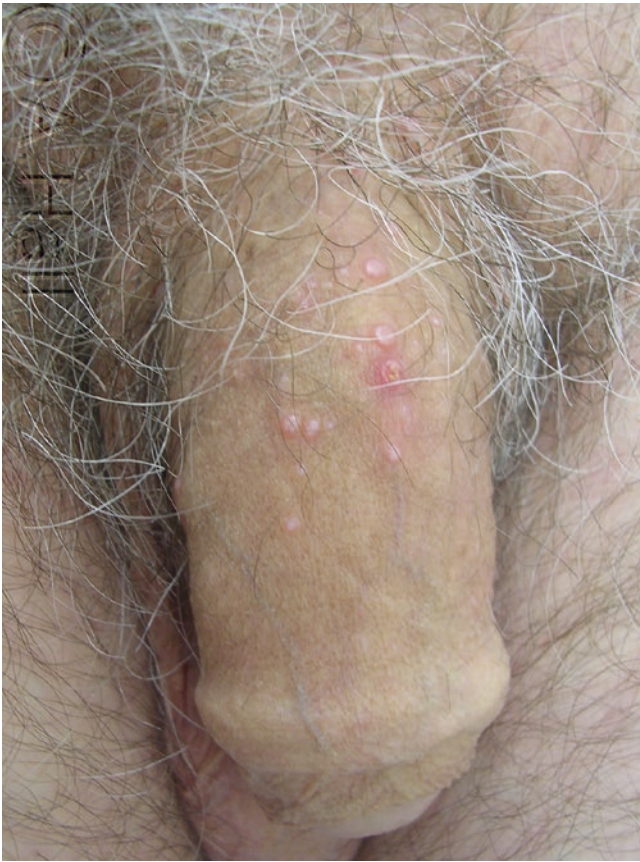

Fig. 26.3 Multiple molluscum contagiosum on the penile shaft

nodules or plaques extending beyond the genital region. Larger molluscum contagiosum papules or nodules on the face should raise the possibility of underlying HIV infection. Molluscum contagiosum may leave residual depressed scarring after healing, as occasionally seen in children.

26.4 Diagnosis

Diagnosis of genital molluscum contagiosum is usually clinical if the lesions are typical. Dermoscopy may help the clinical diagnosis. Atypical lesions need biopsy for histological confirmation, particularly if the patient is immunosuppressed. Curette biopsy with a sharp, disposable curette is the most useful biopsy technique (and is also curative, with minimal scarring). Exclusion of other sexually transmissible infections (STIs) is important. Differential diagnoses of genital molluscum contagiosum include genital warts, pearly penile papules, ectopic sebaceous glands and lichen planus. In immunosuppressed patients, it is important to exclude

atypical or opportunistic viral, bacterial, fungal, and mycobacterial infections.

26.5 Treatment

Most molluscum contagiosum in children is self-limiting, but parents often bring infected children for medical care. Adults with genital molluscum contagiosum often want treatment because of embarrassment and awareness that molluscum contagiosum is a sexually transmissible infection (STI). Molluscum contagiosum may be more persistent in immunosuppressed adults. General treatment measures include an explanation of the mode of transmission and the risks and benefits of treatment options, with advice on prevention of future sexually transmissible infections (STIs). Because response of genital molluscum contagiosum to treatment varies, many medical treatment options have been suggested, including topical salicylic acid, topical lactic acid, topical imiquimod, topical cantharidin and topical tretinoin. Repeated treatment may be necessary. Surgical treatments include curettage, cryotherapy and laser treatment. Cryotherapy is the least invasive surgical treatment but curettage under local anaesthesia is quick, provides tissue for diagnostic confirmation and is usually therapeutic. Curettage under local anaesthesia is probably the preferred treatment option for genital molluscum contagiosum in adult males.

Pearls

- Most genital molluscum contagiosum infection in adults is acquired by sexual transmission.
- Curettage under local anaesthesia is best option for treating adult genital molluscum contagiosum.
- If molluscum contagiosum occurs on the face, consider underlying HIV infection.

Suggested Reading

- Brown M, Paulson C, Henry SL. Treatment for anogenital molluscum contagiosum. *Am Fam Physician*. 2009;80(8):864.
- Fernando I, Pritchard J, Edwards SK, Grover D. UK national guideline for the management of genital molluscum in adults, 2014 Clinical Effectiveness Group, British Association for Sexual Health and HIV. *Int J STD AIDS*. 2015;26(10):687–95.
- Nguyen HP, Tyring SK. An update on the clinical management of cutaneous molluscum contagiosum. *Skin Therapy Lett*. 2014;19(2):5–8.

Impetigo and Superficial Pyogenic Bacterial Infections

27

27.1 Definition

Impetigo is superficial bacterial infection of the skin, mostly due to pyogenic bacteria.

27.2 Aetiology

Impetigo is commonly caused by *Staphylococcus aureus* and occasionally group A beta-hemolytic streptococci (*Streptococcus pyogenes*). Primary impetigo of genital skin is uncommon, but secondary infection of primary genital dermatoses is more frequently seen. Secondary infection with *Staphylococcus aureus* (*S. aureus*) or *Streptococcus pyogenes* (*S. ptogenes*) is referred to as *impetiginisation*. *S. aureus* may be carried in the nasal antrum but also colonises the perineum and other moist intertriginous sites. *S. aureus* and *S. pyogenes* infect both normal skin and damaged or diseased skin. Predisposing factors include excoriations (any pruritic skin disease), abrasions, trauma, atopic dermatitis, scabies, diabetes mellitus, surgical insults, immunosuppression (patients with organ transplants, HIV infection, or those undergoing chemotherapy), and certain medications (systemic corticosteroids, oral retinoids). Primary impetigo and secondary impetiginisation of any pruritic skin disease (scabies, dermatitis, tinea) are very common in tropical regions and the developing world. Skin infection with *S. aureus* or *S. pyogenes* is a major cause of morbidity worldwide, including cellulitis, septic arthritis, osteomyelitis, septicaemia, scarlet fever, post-streptococcal glomerulonephritis, rheumatic fever, bacterial endocarditis, guttate psoriasis, and death.

27.3 Clinical Features

History-taking may confirm a past history of atopic dermatitis, scabies, diabetes mellitus, HIV infection, organ transplant, current treatment with an oral retinoid or systemic

corticosteroid or immunosuppression associated with chemotherapy. Determine if other family members have possible scabies infestation. Non-bullous impetigo begins as weepy, irritable or itchy red papules, plaques or erosions with a characteristic “honey crust” exudate (Fig. 27.1). Thin plaques may extend and develop an annular configuration similar to tinea corporis. Pustules and bullae predominate in bullous impetigo. These progress to flat plaques with a dried crust after rupture of the pustules or bullae. The face and limbs are most often involved with impetigo, but genital, groin and perineal regions may be involved (Fig. 27.2). *Ecthyma* is a deep, localised form of staphylococcal or streptococcal infection that leaves a sharply defined, necrotic ulcer.

General examination helps to determine the general health of a patient. Fever and lymphadenitis may accompany impetigo. Careful examination to exclude underlying scabies, dermatitis, tinea or other underlying skin disease is important.

27.4 Diagnosis

It is important to attempt to confirm the diagnosis of impetigo with a skin swab for microscopy and culture, as sensitivity of the bacteria to antibiotics helps direct therapy. However a skin swab positive for a bacterial infection does not differentiate impetigo from secondary impetiginisation of an underlying skin disease. Skin scrapings for scabies may be necessary, and a skin biopsy may help to define any underlying disease. Nasal swabs are important if impetigo is secondary to *Staphylococcus aureus*, to exclude nasal carriage of *Staphylococcus aureus*. If the patient is febrile or unwell, blood cultures are important to exclude bacteraemia and septicaemia. Differential diagnoses include tinea corporis, herpes simplex, herpes zoster, candidiasis, impetiginised eczema, inverse psoriasis, pemphigus vulgaris, pemphigus foliaceus, and linear IgA disease.

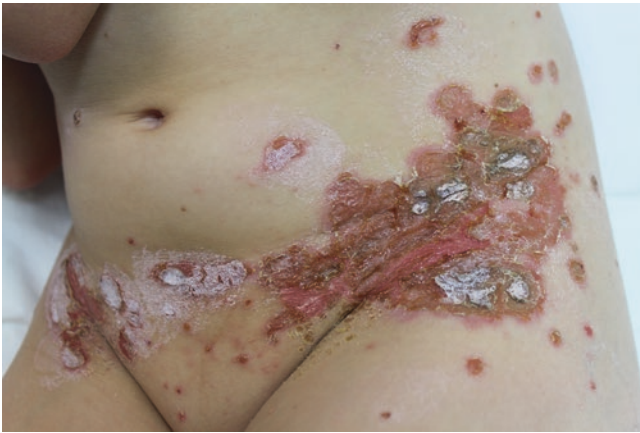

Fig. 27.1 Impetigo of the groin and pubic region in a child

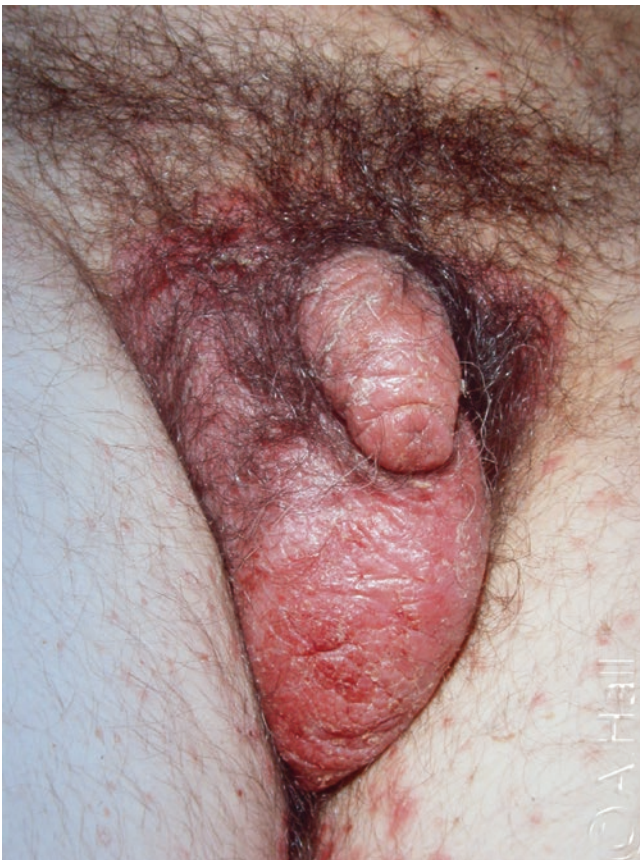

Fig. 27.2 Impetigo of the penis and scrotum

27.5 Treatment

General treatment measures include excluding staphylococcal or streptococcal infection in other family members and partners, isolation of the patient from susceptible people, and emphasis on meticulous hand washing. Moist soaks and hip (Sitz) baths with dilute white vinegar are soothing and help to remove any crust. Removing crust is essential for systemic antibiotics to be more effective. Dilute bleach baths with sodium hypochlorite or showering with chlorhexidine may help to clear pathogenic bacteria. Use of a topical nasal antibiotic (such as mupirocin ointment) is important if nasal carriage of *S. aureus* is proven. Topical mupirocin or fusidic acid may be adequate to treat local infections with staphylococci or streptococci but a systemic antibiotic with coverage against these bacteria is usually necessary. Community-acquired *S. aureus* infection is usually methicillin-sensitive, but community-acquired methicillin resistance (MRSA) is becoming more common.

Pearls

- Impetigo is caused by pyogenic bacteria and is associated with significant morbidity worldwide.
- Removal of crusts is soothing and is important for antibiotic therapy to be maximally effective.

Suggested Reading

Hartman-Adams H, Banvard C, Juckett G. Impetigo: diagnosis and treatment. *Am Fam Physician*. 2014;90(4):229–35.
Pereira LB. Impetigo: review. *An Bras Dermatol*. 2014;89(2):293–9.

28.1 Definition

Fournier's gangrene is a polymicrobial infection causing a localised form of necrotising fasciitis of genital, perineal, and perianal regions.

28.2 Aetiology

Fournier's gangrene is caused by a mixture of facultative and anaerobic bacteria, including Group A beta-hemolytic streptococci (*Streptococcus pyogenes*), enterococci, anaerobic streptococci and staphylococci, *Bacteroides*, *Escherichia coli*, and other enterobacteria. Most patients with Fournier's gangrene are men, but Fournier's gangrene has been reported in women and children. Patients with Fournier's gangrene are often immunocompromised as a result of underlying disease or in association with a surgical procedure. Fournier's gangrene is seen in debilitated patients with poor nutrition, drug addiction or alcoholism, diabetes mellitus, HIV infection and patients undergoing radiotherapy or chemotherapy. Local predisposing diseases allowing entry of facultative and anaerobic bacteria include ischiorectal abscesses, perineal fistulae, diverticular disease, colorectal cancer, penile trauma and pressure ulcers. Surgical procedures predisposing to Fournier's gangrene include urologic surgery, colorectal surgery, urinary instrumentation, and genital piercing.

28.3 Clinical Features

Male patients with Fournier's gangrene are usually between 50 and 60 years of age. The onset is insidious, with erythema and edema of the scrotum. Symptoms include redness, pain, and swelling and discharge of the scrotum or

perineum (Fig. 28.1). There is a rapid progression from redness to purple-black discoloration of the scrotum secondary to frank necrosis. Patients report tenderness and increasing scrotal pain, with general discomfort. Infection spreads superficially from the skin to deeper subcutaneous tissues and fascia, involving penile shaft, perineum, and abdominal wall but usually spares the glans and testes. Fever, tachycardia, systemic upset, and red to purple-black discoloration of the scrotum are major clinical signs. Other scrotal signs include tenderness, crepitus, discharge, and edema.

28.4 Diagnosis

Fournier's gangrene is a rare disease. As the diagnosis is primarily clinical, a high index of suspicion is crucial. Helpful investigations include skin swabs, complete blood count, C-reactive protein, renal function tests and blood cultures. Imaging (plain radiography, ultrasonography, CT, and MRI scans) help to detect air in soft tissue spaces (subcutaneous emphysema) and determine the extent of disease. The differential diagnosis is broad and includes genital trauma, herpes simplex virus (HSV) infection, varicella-zoster virus (VZV) infection, cellulitis, ecthyma, pyoderma gangrenosum, gonorrhoea, polyarteritis nodosa, vascular occlusion syndromes, warfarin necrosis, strangulated hernia, and torsion of testis.

28.5 Treatment

The mortality rate of Fournier's gangrene is 20–30%. Urgent treatment with hemodynamic support, broad-spectrum antibiotic coverage and prompt wide surgical debridement of necrotic tissue is lifesaving. Plastic surgical reconstruction

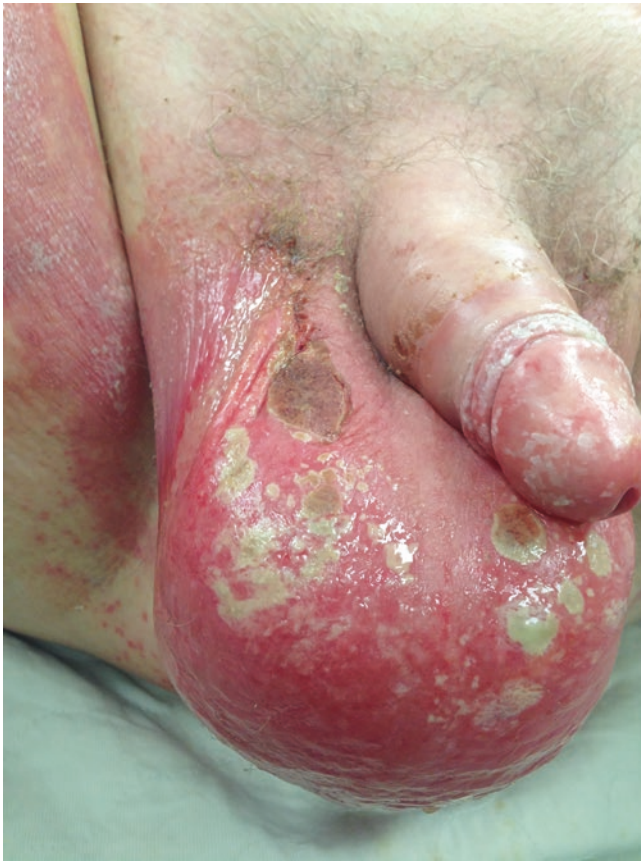

Fig. 28.1 Fournier's gangrene of the scrotum with multiple areas of superficial ulceration covered with purulent slough and focal area of deeper necrotic ulceration with darker red crust. (Photo courtesy of Nathan Lawrentschuk, Uro-Oncologist and Urologist, University of Melbourne, Australia)

of the surgical defect is important for rehabilitation. Additional suggested treatments include topical honey, hyperbaric oxygen, vacuum-assisted closure, and high-dose corticosteroid treatment but these treatments all lack scientific support [1].

Pearls

- Insidious painful scrotal swelling with dark red or purple-black discoloration is suggestive of Fournier's gangrene.
- Fournier's gangrene is a medical emergency with a high mortality rate. Admit the patient to hospital STAT.
- Control of sepsis and debridement of compromised tissue are essential in the management of Fournier's gangrene.

Reference

1. Singh A, Ahmed K, Aydin A, Khan MS, Dasgupta P. Fournier's gangrene. A clinical review. Arch Ital Urol Androl. 2016;88:157–64.

29.1 Definition

Erythrasma is a benign intertriginous eruption associated with *Corynebacterium minutissimum*.

29.2 Aetiology

Corynebacterium minutissimum is a gram-positive rod commensal bacterium that can proliferate in flexures to produce clinical erythrasma, suggesting that warmth and moisture are important. Erythrasma is associated with diabetes mellitus [1], hyperhidrosis, obesity and immunosuppression. In immunocompromised patients, *Corynebacterium minutissimum* may become invasive, resulting in more widespread erythrasma.

29.3 Clinical Features

Clinical signs of erythrasma may be quite subtle in healthy adults, appearing as symmetrical, slightly scaly, red-brown thin plaques in the axillae and groins (Figs. 29.1 and 29.2). Flexural thin, scaly plaques may be well-demarcated and finely wrinkled (“cigarette paper”) with no central clearing. Erythrasma is usually asymptomatic but may be itchy. Under Wood’s lamp examination, erythrasma demonstrates a brilliant coral-pink fluorescence (Fig. 29.3). Other intertriginous sites may be involved, including submammary, intergluteal, and interdigital regions. Pitted keratolysis and trichomycosis axillaris (both associated with *Corynebacterium minutissimum*) have been associated with erythrasma.

29.4 Diagnosis

Clinical diagnosis is aided with Wood’s (UVA) lamp examination. The characteristic coral-pink fluorescence with Wood’s lamp is almost pathognomonic for erythrasma.

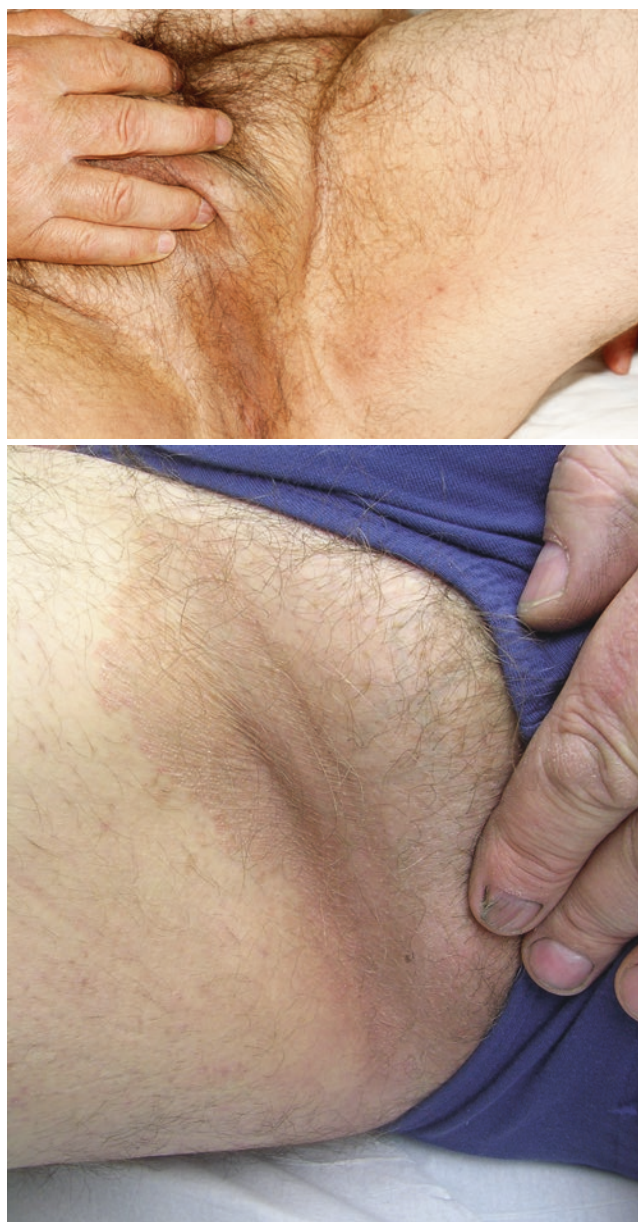

Fig. 29.1 Erythrasma of the groin. (Courtesy of Eugene Tan)

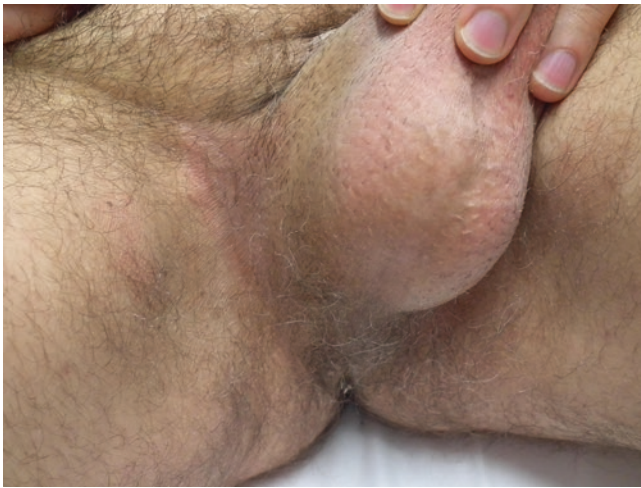

Fig. 29.2 Erythrasma of the groin

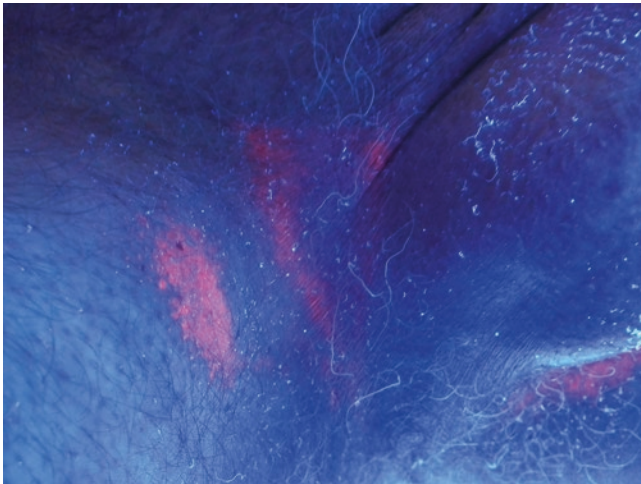


Fig. 29.3 Erythrasma of the groin under a Wood's lamp

Skin scrapings to exclude associated tinea infection are important. It is important to exclude diabetes mellitus if erythrasma is recurrent. Differential diagnoses include tinea, irritant dermatitis (“intertrigo”), candidiasis, seborrhoeic dermatitis and inverse psoriasis.

29.5 Treatment

General measures include avoidance of skin irritants and reduction of excessive sweating. Treatment with topical clindamycin, topical fusidic acid, topical erythromycin or topical mupirocin is usually effective [2, 3]. Topical imidazole creams are alternative treatments. Systemic treatments include oral erythromycin (500 mg twice daily for 14 days) or single-dose clarithromycin [4]. Use of amoxicillin-clavulanic acid or cefaclor may be necessary because of increasing resistance to erythromycin and clarithromycin. Photodynamic therapy has also been described but is not recommended due to discomfort, pain and greater cost.

Pearls

- Examine all scaly, red-brown intertriginous eruptions with a Wood's (UVA) lamp.
- Coral-pink fluorescence under a Wood's lamp is almost pathognomonic for erythrasma.

References

1. Holdiness MR. Management of cutaneous erythrasma. *Drugs*. 2002;62:1131–41.
2. Hamann K, Thorn P. Systemic or local treatment of erythrasma? A comparison between erythromycin tablets and Fucidin cream in general practice. *Scand J Prim Health Care*. 1991;9:35–9.
3. Greywal T, Cohen PR. Erythrasma: a report of nine men successfully managed with mupirocin 2% ointment monotherapy. *Dermatol Online J*. 2017;23:pii:13030/qt9zh116s1.
4. Wharton JR, Wilson PL, Kincannon JM. Erythrasma treated with single-dose clarithromycin. *Arch Dermatol*. 1998;134:671–2.

30.1 Definition

Syphilis is a sexually transmissible infection caused by *Treponema pallidum*, with protean manifestations involving many organs.

30.2 Aetiology

Treponema pallidum is a human motile spiral bacterium (spirochete) that is transmitted by sexual contact or by placental transmission from mother to foetus. Rarely, syphilis can be transmitted by blood transfusion. Unprotected sexual activity is the most common mode of transmission. Syphilis is increasing in developed countries, with most new cases reported in men who have sex with men (MSM). Syphilis is associated with HIV infection, as genital ulceration is a risk factor for transmission of HIV. A painless ulcer or chancre (Fig. 30.1) is the most common feature of primary syphilis. Co-infection with HIV worsens the prognosis for syphilis by AIDS-associated immunosuppression.

Four stages of syphilis are recognised: *Primary syphilis* is the initial infection, followed by *secondary syphilis*, when *Treponema pallidum* proliferates and spreads through the body. Secondary syphilis is followed by the asymptomatic *latent stage*, detectable only by persistent positive serology. If syphilis is untreated, some patients develop *tertiary syphilis* years later. Tertiary syphilis mainly affects the cardiovascular and central nervous systems, but gummatous lesions of tertiary syphilis may affect many organs, including skin. Tertiary syphilis is probably a non-infectious stage.

30.3 Clinical Features

Syphilis has been called “the great imitator” or “the great pretender” because of its many varied presentations and its ability to mimic many other diseases [1]. Men who have sex

with men (MSM) with multiple sex partners and who practice unprotected sexual intercourse are at highest risk of infection.

Primary syphilis is characterised by a painless, indurated papule or plaque that erodes into an ulcer (chancre). These painless ulcers are usually solitary but may be multiple. Chancres occur at ano-genital or oral sites of initial infection. Careful examination is necessary to detect occult chancres under the foreskin, in the oral cavity, or in the rectum. Chancres usually heal within 4–8 weeks. Chancres may be associated with regional lymphadenopathy. Rarely, primary syphilis may present as balanitis in uncircumcised men [2].

In secondary syphilis, the skin and mucous membranes are most affected [3]. The exanthem of secondary syphilis may be subtle or may be a florid, diffuse, nonpruritic macular, papular, or pustular truncal eruption (“roseola syphilitica”). The color of lesions of secondary syphilis varies from red or brown to hyperpigmented lesions in “skin of color” patients. Macules or papules of the palms or soles are highly suggestive of secondary syphilis and may last up to 12 months (Fig. 30.2). Eroded oral mucous membrane and lingual plaques (“mucous patches”) are usually painless. Systemic symptoms of secondary syphilis include malaise, fever, arthralgias, lymphadenopathy, and neck stiffness. Milder systemic symptoms may go unnoticed. Patchy, non-scarring, “moth-eaten” or diffuse alopecia may be prominent. Condylomata lata are papules, plaques or nodules of the anogenital region that may be confused with condyloma acuminata (genital warts). Atypical presentations of secondary syphilis are common. Co-infection with HIV may modify the appearance of secondary syphilis. Deep, ulcerating lesions of malignant secondary syphilis (“leus maligna”) may be seen in patients co-infected with HIV [4].

Cutaneous gummatous lesions of tertiary syphilis are usually asymptomatic, nonspecific fibrotic papules, plaques, or nodules with hyperpigmented borders, which may ulcerate.

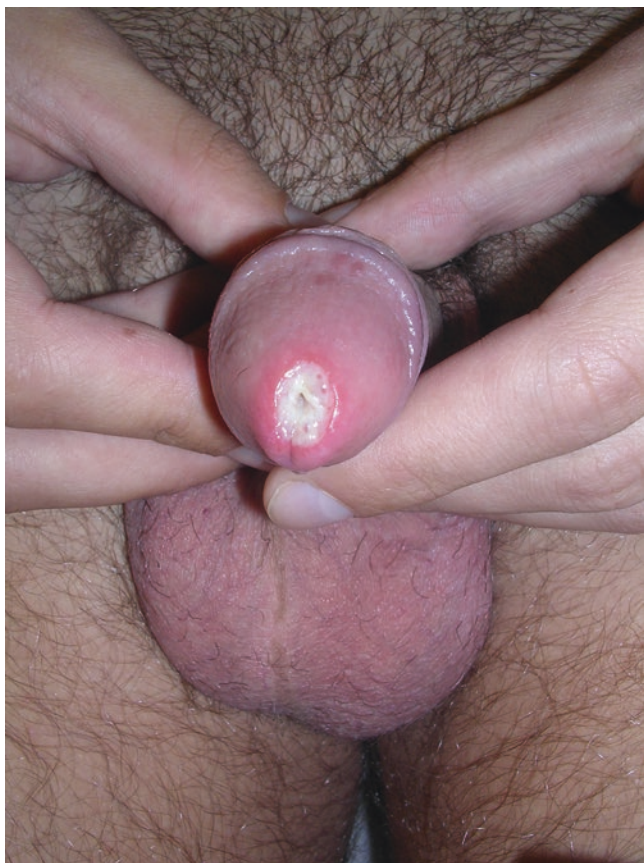

Fig. 30.1 Chancre of primary syphilis

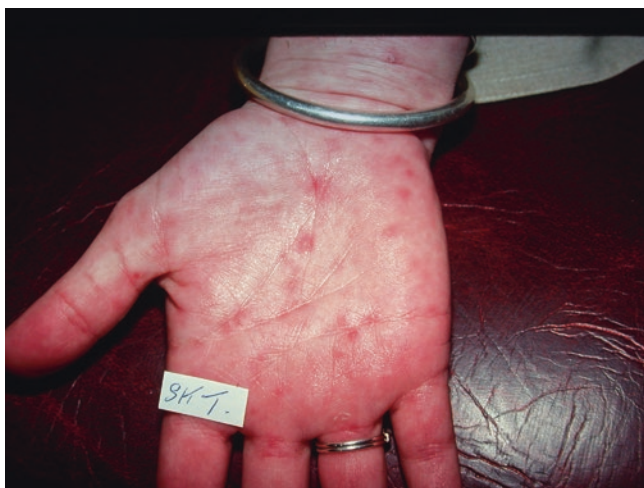

Fig. 30.2 Red macules and papules on palm in secondary syphilis

30.4 Diagnosis

Diagnosis of syphilis is based on clinical suspicion with histology and serological testing. The “great imitator” has varied and atypical presentations. Syphilis should enter the

differential diagnosis for any person at high risk of infection, including MSM and patients who practice unprotected sexual activity, have multiple sex partners, previous HIV infection or have had previous sexually transmissible infections (STIs). It is important to perform a biopsy of any suspicious ano-genital ulcer, papule, nodule or plaque. Histologic features are variable but include granulomas, a plasma cell infiltrate and obliterative endarteritis. *Treponema pallidum* can be detected by immunohistochemical staining in primary and secondary syphilis. Gummas show necrotising granulomas with a plasma cell infiltrate. Syphilis serology includes both non-treponemal screening tests and specific treponemal tests. Non-treponemal screening tests include Venereal Disease Research Laboratory (VDRL) and rapid plasma reagin (RPR). Specific treponemal tests include the fluorescent treponemal antibody absorbed (FTA-ABS) test and the *Treponema pallidum* particle agglutination assay (TPPA). Rapid diagnostic tests (RDTs) using test strips that provide results within 10–15 min are becoming more widespread. Cerebrospinal fluid (CSF) testing is necessary if neurological involvement is suspected. Patients with proven syphilis should be tested for other sexually transmissible infections (STIs), including HIV. Partner notification and testing is important (but often a partner is not identified). Reporting of syphilis to health authorities is mandatory in most countries.

30.5 Treatment

Early treatment is essential to try to halt progression from primary and secondary stages to tertiary syphilis. *Treponema pallidum* has remained sensitive to penicillin, so penicillin is still the drug of choice. Long-acting benzathine penicillin G (2.4 million units intramuscularly) is effective for primary, secondary and early latent syphilis. Doxycycline (100 mg orally twice daily for 14 days), ceftriaxone (1 g intramuscularly daily for 10–14 days) or azithromycin (2 g orally as a single dose) are alternative treatments. Penicillin resistance has not yet become an issue but resistance to azithromycin has been reported. Longer treatment periods are necessary for latent and tertiary syphilis. Long-term follow-up with repeat serological testing is important.

Strategies to prevent transmission of syphilis include encouragement of safe sexual practices involving condom use and avoidance of intravenous drug use with needle sharing. The role of adult circumcision in preventing the transmission of sexually transmissible infections is controversial. No vaccine is currently available.

Pearls

- Syphilis is “the great imitator,” so great awareness of atypical presentations is important.
- Carefully inspect under the foreskin and in the oral cavity and perianal region for occult chancres.
- When macules or papules are detected on palms or soles, consider secondary syphilis.
- Syphilis enhances the spread of HIV, and AIDS worsens the prognosis for syphilis.

References

1. Shockman S, Buescher LS, Stone SP. Syphilis in the United States. *Clin Dermatol*. 2014;32:213–8.
2. Babu CS, Vitharana S, Higgins SP. Primary syphilis presenting as balanitis. *Int J STD AIDS*. 2007;18:497–8.
3. Brown TJ, Yen-Moore A, Tyring SK. An overview of sexually transmitted diseases. Part 1. *J Am Acad Dermatol*. 1999;41:511–29.
4. Prasad PV, Paari T, Chokkalingam K, Vijaybushanam V. Malignant syphilis (leus maligna) in a HIV infected patient. *Indian J Dermatol Venereol Leprol*. 2001;67:192–4.

31.1 Definition

Scabies is a pruritic skin disease caused by infestation of the ectoparasite *Sarcoptes scabiei*.

31.2 Aetiology

Scabies is caused by infestation with the human mite *Sarcoptes scabiei*. The female mite burrows into skin to lay her eggs and deposits faeces. After an incubation period of 2–6 weeks, a pruritic papulonodular eruption develops, representing a hypersensitivity reaction. Scabies is transmitted by direct human-to-human contact, as *Sarcoptes scabiei* infestation is confined to its human host. Most infestations are acquired non-sexually from close contact with an infected person, usually a family member. Scabies can also be transmitted sexually from an infected partner. *Sarcoptes scabiei* can survive away from a human host for a few days, so transmission by fomites (bedding, clothes, footwear) is possible. People most at risk of infestation are children, institutionalised patients in nursing homes, patients in hospital, prisoners and socio-economically disadvantaged communities. People living in tropical or subtropical regions and remote indigenous communities (eg, aboriginal communities of northern Australia) are particularly susceptible. Crusted or Norwegian scabies occurs in people with suppressed awareness of itch (eg, mental impairment, Down syndrome, dementia), patients unable to scratch (eg, paralysis) and immunosuppressed patients (eg, HIV infection). Most patients with common scabies are infected with fewer than 20 mites. Individuals with crusted (Norwegian) scabies carry large numbers of mites that are easily shed. Patients with crusted scabies may not be itchy. They are often the source case of local outbreaks. Human scabies infestation is a worldwide problem with an enormous impact on public health. Scabies has an enormous negative impact on the health of indigenous communities such as aboriginal people of northern Australia. Chronic

scabies infestation is a major cause of morbidity from secondary streptococcal skin infection [1].

31.3 Clinical Features

An infected person may recall contact with another infected person. Common scabies usually presents as a generalised pruritic eruption or impetiginised dermatitis. Itching is often severe enough to disturb sleep. Pruritic papules or nodules of the penis or scrotum are almost pathognomonic for scabies (Figs. 31.1, 31.2, and 31.3). Careful clinical examination may reveal serpiginous scabetic burrows overlying digital web spaces of hands, the sides of fingers, or volar aspects of wrists (Figs. 31.4 and 31.5). Less common sites include axillae, waist, areolae, palms and soles of children and the backs of elderly patients. Widespread papules, papulovesicles, or nodules are often excoriated, secondary to scratching. Non-healing sores, representing secondarily infected lesions (pyoderma) may dominate the clinical presentation. Patients with crusted scabies are often elderly, mentally impaired, physically unable to scratch, or immunocompromised. Hyperkeratotic, scaly plaques of palms and soles are characteristic of crusted scabies. Crusted scabies may present as very scaly, hyperkeratotic plaques on scalp, trunk or limbs (resembling chronic plaque psoriasis or sebo-psoriasis) or as a widespread, erythrosquamous disorder (Fig. 31.6). Itch may be absent in crusted scabies.

31.4 Diagnosis

Patients with scabies infestation rarely present with pruritic genital papules or nodules; they usually have generalised pruritus or an impetiginised eruption. Diagnosis is based on clinical identification of scabetic burrows or microscopic identification of mites, ova, or faeces in skin scrapings with microscopy (Fig. 31.7). Dermoscopy may help to identify the scabies mite as a black dot at one end of a burrow. Identification of a scabetic burrow is aided by

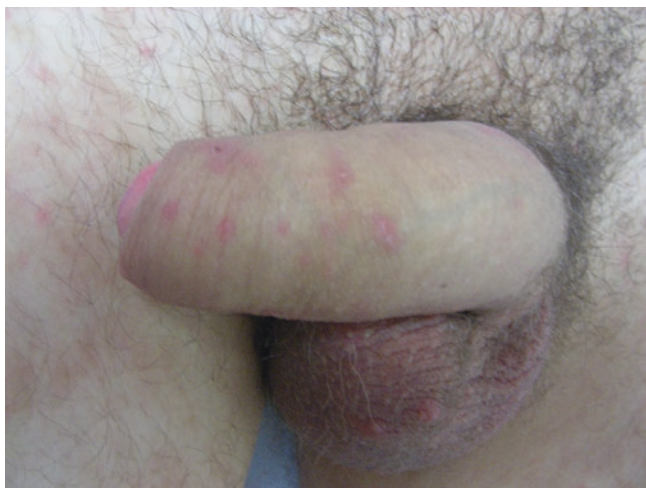

Fig. 31.1 Scattered scabies papules on the penile shaft

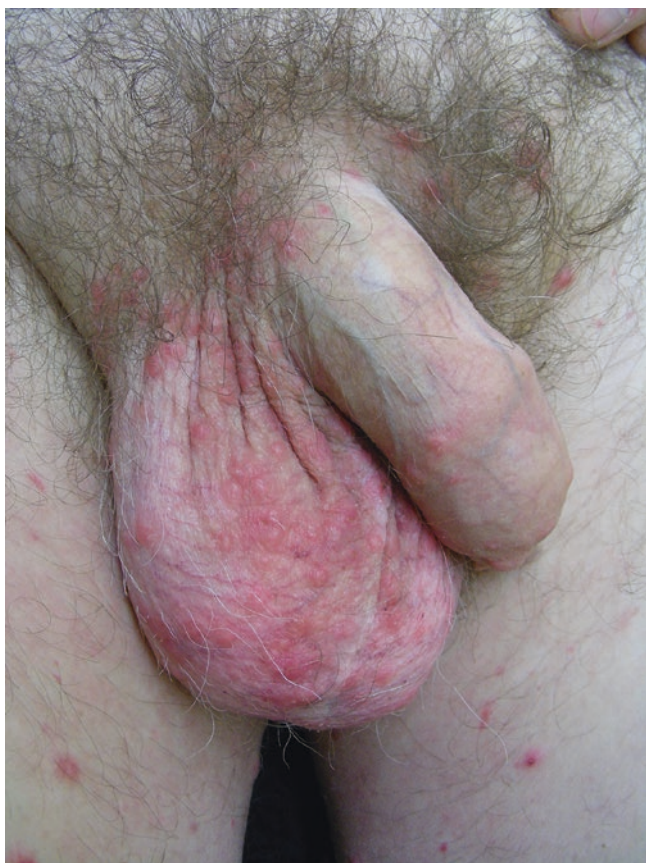

Fig. 31.2 Extensive scabies papules on the scrotum and penile shaft

drawing with a washable marker pen over a burrow site. Excess ink is wiped off with an alcohol swab. The burrow is then more readily visible, highlighted by black ink. The presence of multiple pruritic papules or nodules on the penis or scrotum is almost pathognomonic for scabies. The diagnosis of scabies may be challenging, however, as identification of staphylococci or streptococci from impe-

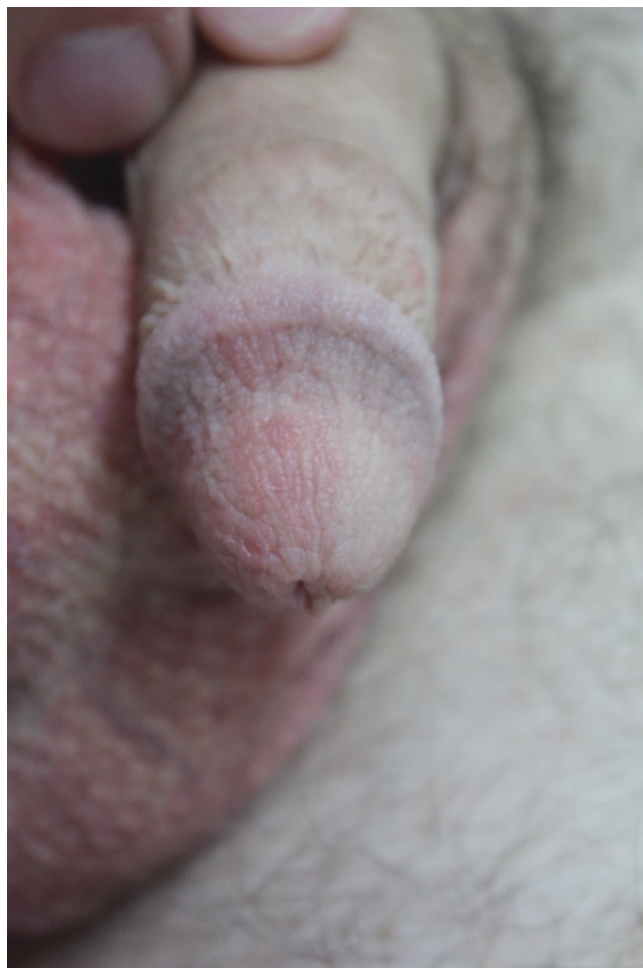


Fig. 31.3 Scabies of the glans penis

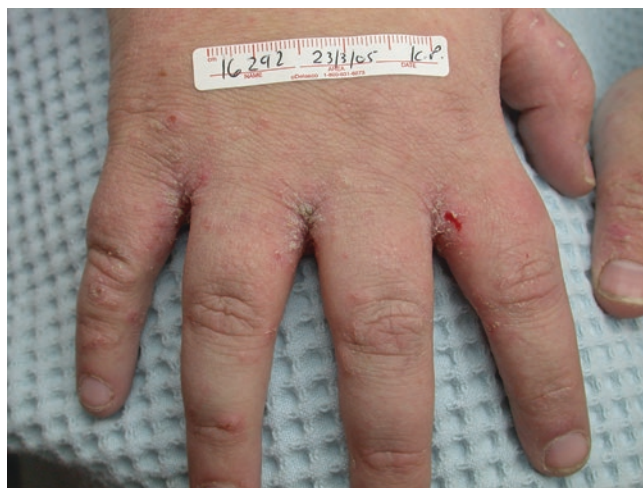

Fig. 31.4 Scabies burrows on a hand. Note crusting and erosions

tiginisation of scabies may lead to a wrong diagnosis of impetigo. Sometimes the scabies mite cannot be found in a patient presenting with widespread pruritus. Previous

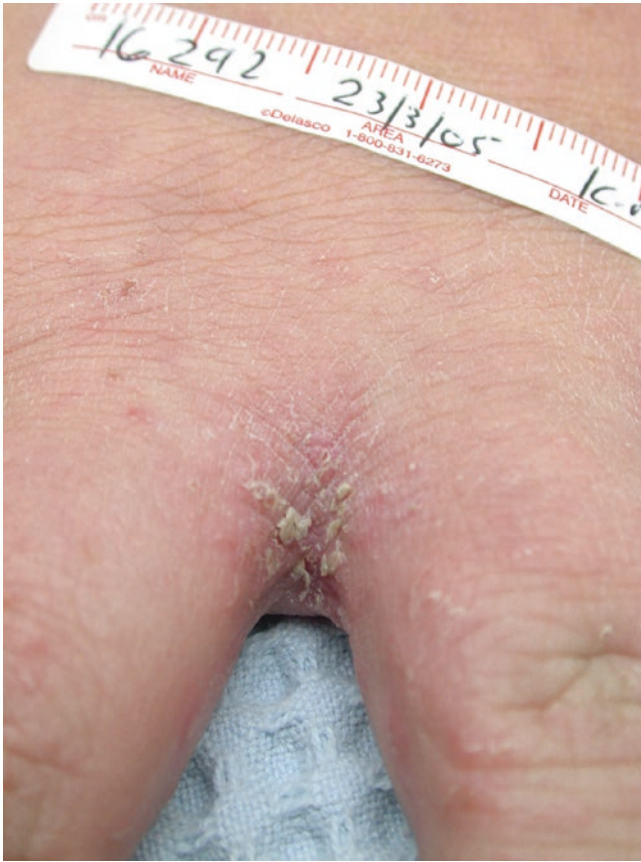

Fig. 31.5 Scabies burrows with crusting overlying digital web spaces of hand

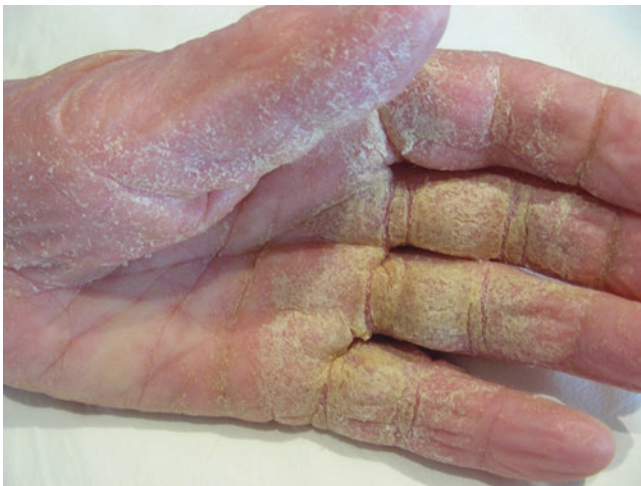

Fig. 31.6 Hyperkeratotic, scaly palms of crusted scabies

treatments, including the use of topical corticosteroids, may have altered the clinical appearance, resulting in “scabies incognito.” The correct diagnosis is made weeks or months later, when the scabies mite is finally identified. Crusted scabies with widespread scaly plaques may be mistaken for chronic plaque psoriasis or chronic lichenified dermatitis. If scabies is suspected in a patient but no

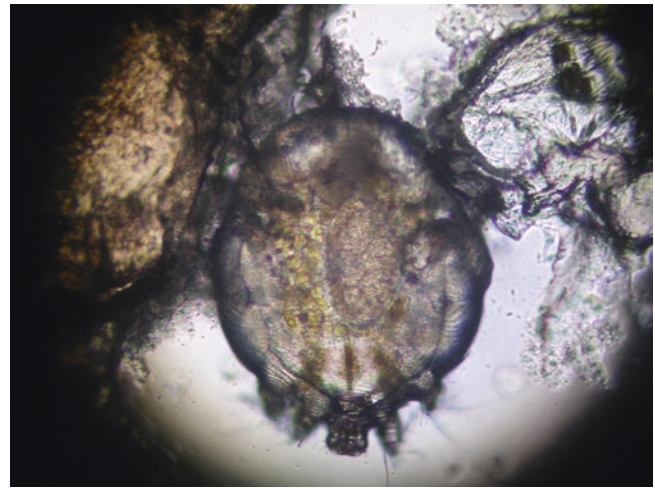


Fig. 31.7 Scabies mite under light microscope

mites or burrows can be identified, examination of close family contacts or sexual partners may reveal scabies infestation.

31.5 Treatment

Identification and isolation of the infected patient with scabies and infected partners or family members is important. The infected patient, sexual partners, and all close family contacts should be treated simultaneously. All bedding and clothing should be washed or sealed in plastic bags for at least 3 days. Worn clothing should be replaced with fresh clothing after bathing and application of a topical scabecticide. Topical scabecticides include permethrin 5% cream, benzyl benzoate 25%, lindane 1% lotion, crotamiton 10% lotion or cream, and sulphur 2–10% in petrolatum (soft white paraffin). Topical permethrin 5% cream and benzyl benzoate 25% (10–12.5% for children) need to be applied to the whole body below the neck for adults, left on for 8–14 h, and then washed off. The face and head of infants need to be treated. Applications of topical permethrin and benzyl benzoate should be repeated after 7 days. Caution is needed with the use of topical lindane, as toxicities (seizures and aplastic anaemia) have been reported. Pruritus may persist up to 4 weeks after treatment with topical scabecticides. Re-infestation with scabies is common, and repeat treatment with a topical scabecticide is necessary. Oral ivermectin is preferable for recurrent or persistent common scabies. A single 200 µg/kg dose of oral ivermectin is repeated 1 week later. Oral ivermectin is not recommended in pregnancy or for children weighing less than 15 kg. Crusted (Norwegian) scabies is best treated with a combination of a topical scabecticide and oral ivermectin. Recommendations for the treatment of crusted scabies with oral ivermectin vary. A single dose of oral ivermectin (200 µg/kg) is repeated 3–7 times over 1–4 weeks. Oral ivermectin is the preferred treatment in communities with high rates of scabies.

Trials in Pacific islands and remote Australian aboriginal communities have confirmed the superior efficacy of oral ivermectin over topical permethrin for common scabies. Mass treatment of whole communities reduces scabies and its complications [2–4]. Ancillary treatments for scabies include dilute hypochlorite bathing (“bleach baths”), washing with topical antiseptics and the use of oral antibiotics to treat secondary bacterial infection. Persisting scabetic nodules may be injected with intralesional corticosteroid.

Pearls

- Pruritic papules or nodules on penis or scrotum are (almost) pathognomonic for scabies infestation.
- Oral ivermectin is the best treatment for persistent, recurrent or crusted (Norwegian) scabies.

References

1. Currie BJ, Carapetis JR. Skin infections and infestations in Aboriginal communities in northern Australia. *Australas J Dermatol*. 2000;41:139–45.
2. Lawrence G, Leafasia J, Sheridan J, Hills S, Wate J, Wate C, et al. Control of scabies, skin sores and haematuria in children in the Solomon Islands: another role for ivermectin. *Bull World Health Organ*. 2005;83:34–42.
3. Romani L, Whitfeld MJ, Koroivueta J, Kama M, Wand H, Tikoduadua L, et al. Mass drug administration for scabies control in a population with endemic disease. *N Engl J Med*. 2015;373:230–13.
4. Kearns TM, Speare R, Cheng AC, McCarthy J, Carapetis JR, Holt DC, et al. Impact of an ivermectin mass drug administration on scabies prevalence in a remote Australian aboriginal community. *PLoS Negl Trop Dis*. 2015;9(10):e0004151.

Suggested Reading

- Workowski KA, Bolan GA, Centers for Disease Control and Prevention. Sexually transmitted diseases treatment guidelines, 2015. *MMWR Recomm Rep*. 2015;64(RR-03):1–137.
- World Health Organization. WHO guidelines for the management of sexually transmitted infections. Geneva: World Health Organization; 2003.

32.1 Definition

Pediculosis pubis is infestation of pubic or genital region with the pubic louse *Phthirus pubis* (crab louse). Other hair-bearing sites may be involved.

32.2 Aetiology

Phthirus pubis (crab louse) is a blood-sucking ectoparasite that attaches to pubic hair. The adult louse has six legs, with two prominent anterior legs that look like pincher claws of common aquatic crabs. The louse is dependent on sucking human blood and dies within 24 hours if separated from the human body. *Phthirus pubis* is spread by sexual contact and occasionally by fomites (clothing and bed linens). The diameter of scalp hair is usually too thin for *Phthirus pubis* to attach to, but the louse can attach to eyelashes and rarely to scalp hair. Pubic lice affect both sexes worldwide but are commoner in young, sexually active people with multiple partners and in people in crowded communities with limited sanitation. The modern fashion of removing part or all of the pubic hair (pubic depilation) has led to a dramatic reduction in the incidence of pubic lice in developed countries.

32.3 Clinical Features

Patients usually complain of pubic itch, a “crawling” sensation in pubic region or blood staining on underwear. Infected individuals may recall sexual activity with an infected person, often a single casual, unprotected episode of intercourse. Careful clinical examination with the naked eye may reveal a few small, slow-moving lice attached to pubic hairs and adjacent thigh hairs (Fig. 32.1). Light magnification greatly aids identification (Fig. 32.2). Nits or egg cases are not as easily seen as with pediculosis capitis (head lice). Light blue or grey macules (*maculae cerulae*), red macules, or crusts may be observed in the pubic region at sites of bites. Check

the axillae and coarse body hair of hirsute males, where *Phthirus pubis* also may be found. Scalp hair is rarely involved [1].

32.4 Diagnosis

Diagnosis is by identification of a louse under a plain glass slide with light microscopy (Fig. 32.3). Nits may occasionally be seen.

32.5 Treatment

Both the patient and all sexual partners should be treated. Topical treatments (pediculicides) include 1% permethrin cream rinse and pyrethrins with piperonyl butoxide. Second-line treatments include phenothrin 0.2% lotion and malathion 0.5% lotion (both off-label). Other alternative topical treatments include 5% permethrin cream (recommended for scabies), ivermectin 0.5% lotion, and benzyl benzoate 25% lotion. Topical 5% permethrin cream may be more effective than 1% permethrin cream (off-label). Caution is needed with topical lindane as toxicities (seizures and aplastic anaemia) have been reported. (Topical lindane has been withdrawn from the European Medicines Agency.) The chosen topical treatment should be applied after washing and drying the pubic region. Topical 1% permethrin cream and pyrethrins with piperonyl butoxide should be washed off after 10 min. Topical phenothrin 0.2% lotion needs to be washed off after 2 hour and malathion 0.5% lotion should be washed off after 8–12 hours. After removing the topical application, underwear and clothing should be replaced with clean clothing. Topical treatments should be repeated within 1–2 weeks. Oral ivermectin, given as a 200 µg/kg single dose and repeated after 1–2 weeks, is an alternative to topical treatment. Petrolatum (white paraffin) ointment should be used as an inert, occlusive eye ointment for pediculosis of the eyelashes. All bedding linen should be washed or stored

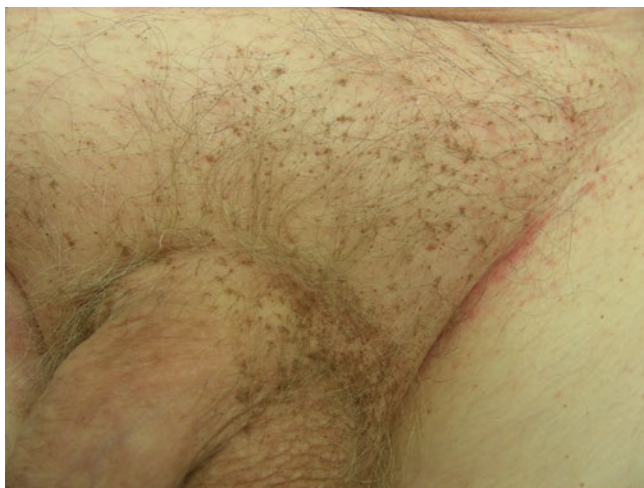

Fig. 32.1 Pediculosis pubis of pubic and groin region

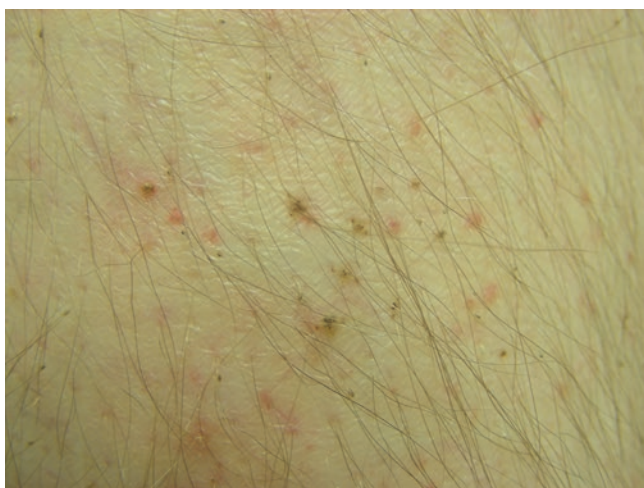

Fig. 32.2 Pediculosis pubis of pubic and groin region with grey (maculae cerulae) and red macules under hand-held magnification

in sealed plastic bags for up to 2 weeks. Removal of pubic hair is an important physical treatment for treating pubic lice. The increased popularity of pubic hair depilation (eg, Brazilian waxing) has been associated with a marked decline in reporting of pediculosis pubis.

Screening for other sexually transmissible diseases is essential, as up to 30% of patients are co-infected with another sexually transmissible disease [2]. Sexual contact should be avoided until treatment is completed. Condoms are important in preventing the spread of sexually transmissible diseases but do not offer protection from pediculosis pubis.



Fig. 32.3 Appearance of *Phthirus pubis* (pubic louse) under microscopy

Pearls

- Depilation of pubic hair has led to a dramatic reduction in pubic lice.
- Patients with pediculosis pubis may be co-infected with another sexually transmissible disease.
- Condoms do not offer protection against pediculosis pubis.

References

1. Eto A, Nakamura M, Ito S, Tanaka M, Furue M. An outbreak of pubic louse infestation on the scalp hair of elderly women. *J Eur Acad Dermatol Venereol.* 2017;31:e79–80.
2. Ko CJ, Elston DM. Pediculosis. *J Am Acad Dermatol.* 2004;50:1–12.

Suggested Reading

- Centers for Disease Control and Prevention. Parasites. 2015. <https://www.cdc.gov/parasites/lice/public/biology.html>. Accessed 6 June 2018.
- Salavastru CM, Chosidow O, Janier M, Tiplica GS. European guideline for the management of pediculosis pubis. *J Eur Acad Dermatol Venereol.* 2017;31:1425–8.

33.1 Definition

Genital granulomatous diseases are a heterogeneous collection of granulomatous diseases that may be localised to genitalia or part of a systemic granulomatous disease.

33.2 Aetiology

Genital granulomatous diseases may be either infective or noninfective. Non-infective genital granulomatous diseases include granuloma annulare [1, 2], necrobiosis lipoidica [3], sarcoidosis, Crohn's disease, granulomatous lymphangitis [4] and foreign body granulomas [5, 6]. Up to 40% of adult males with genital granulomatosis have associated Crohn's disease [7]. Genital granulomatosis, orofacial granulomatosis, Melkersson-Rosenthal syndrome and granulomatous lymphangitis may all be manifestations of Crohn's disease [4]. Infectious genital granulomatous diseases include tuberculosis and syphilis [8]. Atypical viral, fungal, bacterial or mycobacterial genital granulomatous diseases need to be considered in any immunosuppressed patient.

33.3 Clinical Features

Genital granulomatous disease may be asymptomatic, itchy, irritated, painful or may even present with bleeding. Patients with granulomatous genital disease may be systemically well and present with asymptomatic papules, nodules, plaques or ulceration. Other patients experience significant symptoms that include fevers, weight loss, abdominal pain, diarrhea or rectal bleeding. Relevant past medical diseases include sarcoidosis, tuberculosis and Crohn's disease (Figs. 33.1 and 33.2). Past sexually transmissible infections (STIs), previous infectious granuloma-

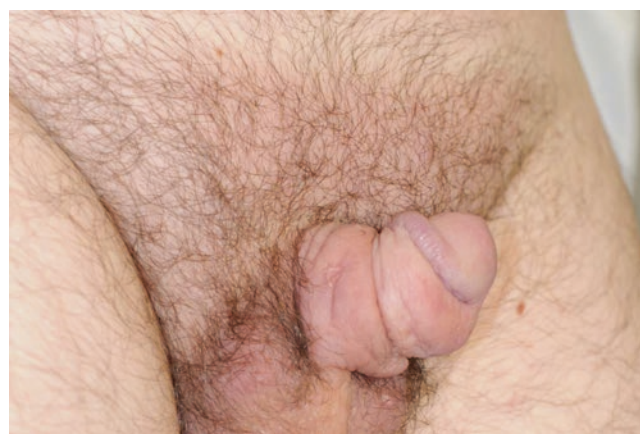

Fig. 33.1 Granulomatous edema associated with gastrointestinal Crohn's disease

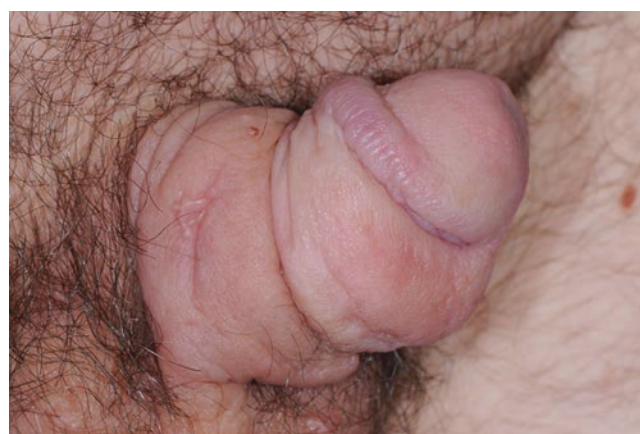

Fig. 33.2 Granulomatous edema associated with gastrointestinal Crohn's disease

tous diseases (*eg*, tuberculosis, leprosy), social circumstances, travel history and current treatment are all important. Different geographic regions and societies have




Fig. 33.3 Granulomatous inflammation of penile shaft due to injected foreign substance for penile enlargement

different spectra of granulomatous diseases. A crucial history of prior injection of foreign substances into the genitalia may be omitted by the patient because of shame or embarrassment (Fig. 33.3).

The clinical examination should assess the general health of any patient and should look for signs of orofacial granulomatosis (facial swelling, lip swelling, scrotal tongue, facial paresis), sarcoidosis (lupus pernio, papulonodular eruption, scar sarcoid, erythema nodosum), cutaneous tuberculosis (wartlike tuberculosis, lupus vulgaris, papular or nodular tuberculides), and Crohn's disease (perianal fissuring). The clinical presentation can be varied and atypical in immunosuppressed patients. Have a high index of suspicion for possible infective granulomatous disease in immunosuppressed patients.

33.4 Diagnosis

The granulomatous histological pattern is non-specific for aetiology. Once the granulomatous histological pattern is identified, it is important to attempt to define the specific aetiology of the genital disease. Diagnosis of many genital granulomatous diseases is based on a combination of clinical features, histopathology and investigations. A specific diagnosis of sarcoidosis may be possible if sarcoidal granulomas are present in the biopsy tissue. Sometimes it is only possible to exclude important granulomatous diseases, including sar-

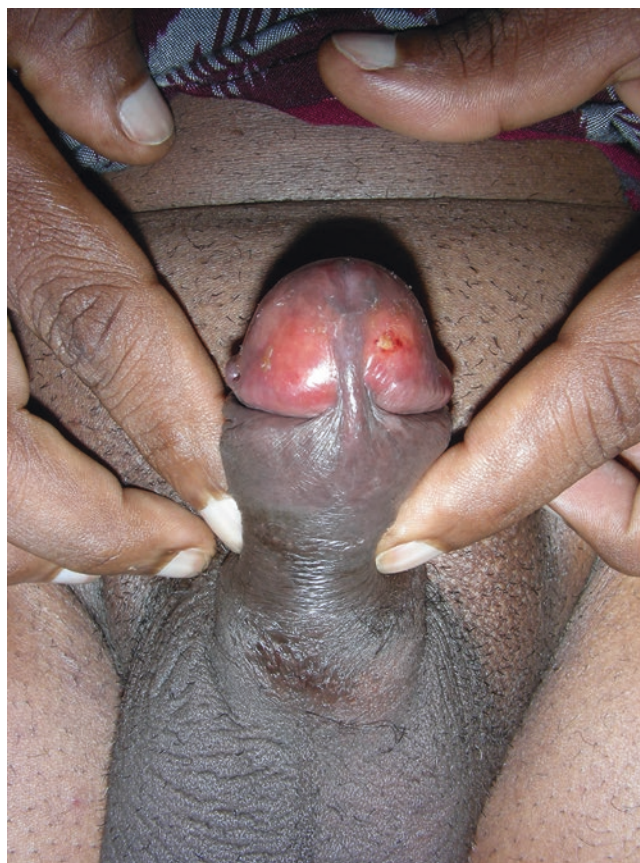

Fig. 33.4 Painful granulomatous inflammation of glans penis with no detectable gastrointestinal Crohn's disease

coidosis, Crohn's disease, tuberculosis and granulomatous sexually transmissible diseases (Fig. 33.4). Genital skin biopsy tissue should be sent for routine hematoxylin and eosin (H&E) staining, periodic acid–Schiff (PAS) staining and staining for mycobacteria (*eg*, Ziehl-Neelsen stain). The Ziehl-Neelsen stain may confirm tuberculosis, the Fite stain may confirm leprosy and the PAS stain may confirm a deep fungal infection. A fresh biopsy specimen needs to be sent for microscopy and culture. All relevant information should be provided to histopathology and microbiology colleagues. Useful baseline investigations include complete blood examination, liver function, renal function, serum fasting glucose, tuberculin testing, interferon-gamma release assay test (QuantiFERON-TB Gold test), syphilis serology, HIV antibodies, chest x-ray or CT scan, lower gastrointestinal endoscopy, and colonoscopy. Further special investigations are

aimed at confirming or excluding possible diagnoses based on the results of the initial tests.

33.5 Treatment

Treatment is based on an accurate etiologic diagnosis. Crohn's disease is treated with oral corticosteroids, steroid-sparing agents such as azathioprine, and anti-tumour necrosis factor (TNF) agents. Surgical resection of redundant tissue and plastic surgical reconstruction may be necessary.

Pearls

- Genital granulomatous diseases include noninfective and infective, localised and systemic disease.
- Treatment of granulomatous genital disease is based on accurate etiologic diagnosis.

References

1. Sidwell RU, Green JS, Agnew K, Francis ND, Roberts NM, Madden N, Bunker CB. Subcutaneous granuloma annulare of the penis in 2 adolescents. *J Paediatr Surg.* 2005;40:1329–31.
2. Narouz N, Allan PS, Wade AH. Penile granuloma annulare. *Sex Transm Infect.* 1999;75:186–7.
3. Tokura Y, Mizushima Y, Hata M, Takigawa M. Necrobiosis lipoidica of the glans penis. *J Am Acad Dermatol.* 2003;49:921–4.
4. Vricella GJ, Coplen DE, Austin PF, White FV. Granulomatous lymphangitis. *J Urol.* 2013;190:1052–3.
5. Hohaus K, Bley B, Kostler E, Schonlebe J, Wollina U. Mineral oil granuloma of the penis. *J Eur Acad Dermatol Venereol.* 2003;17:585–7.
6. Santos P, Chaveiro A, Nunes G, Fonseca J, Cardosos J. Penile parafinoma. *J Eur Acad Dermatol Venereol.* 2003;17:583–4.
7. Alexakis C, Gordon K, Mellor R, Chong H, Mortimer P, Pollok R. Ano-genital granulomatosis and Crohn's disease: a case series of males presenting with genital lymphoedema. *J Crohns Colitis.* 2017;11:454–9.
8. Sciubba JJ, Said-Al-Naief N. Orofacial granulomatosis: presentation, pathology and management of 13 cases. *J Oral Pathol Med.* 2003;32:576–85.

34.1 Definition

Cutaneous edema is the accumulation of extracellular fluid in skin. Lymphedema is the accumulation of lymph, an extracellular fluid rich in protein. Edema or lymphedema of male genitalia may involve the glans, foreskin, penile shaft, scrotum or the whole external genitalia.

34.2 Aetiology

Acute edema of the partially retracted foreskin occurs with paraphimosis, usually associated with lichen sclerosis with phimosis. Acute edema may be due to allergic contact dermatitis or absorption of a previously sensitised allergen (angioedema) (Fig. 34.1). Male genital lymphedema may be acute or chronic, but in clinical practice, chronic genital lymphedema is more common. Chronic lymphedema is the result of a failure of lymphatic drainage, usually due to obstruction of lymphatic flow. If no underlying disorder is identified, chronic genital lymphedema is termed *chronic idiopathic genital lymphedema* (or *chronic idiopathic penile edema*) (Fig. 34.2). Primary (idiopathic) genital lymphedema is due to lymphatics that are lacking or malformed (Milroy's disease). Secondary (acquired) chronic genital lymphedema is due to infectious or non-infectious causes. The commonest cause of chronic genital lymphedema in tropical regions of world is filariasis ("elephantiasis tropica"). In the developed world, the most important cause is granulomatous lymphangitis, often associated with Crohn's disease (Figs. 34.3 and 34.4). Genital granulomatous lymphangitis may represent an incomplete or atypical form of Crohn's disease [1]. Extraintestinal (metastatic) Crohn's disease, orofacial granulomatosis (which includes granulomatous cheilitis and Melkersson-Rosenthal syndrome) and genital granulomatous lymphangitis may be part of a spectrum of cutaneous Crohn's disease. In boys, genital lymphedema usually precedes gastrointestinal Crohn's disease [2]. Other causes of chronic genital lymphedema include obstruction or damage to lymphatics (by infections, tumours,

surgery or radiation treatment), self-injected foreign substances, and sarcoidosis.

34.3 Clinical Features

Most male patients with chronic genital lymphedema report non-pitting swelling of the penile shaft, foreskin or scrotum that begins in adolescence or later adulthood, though geni-

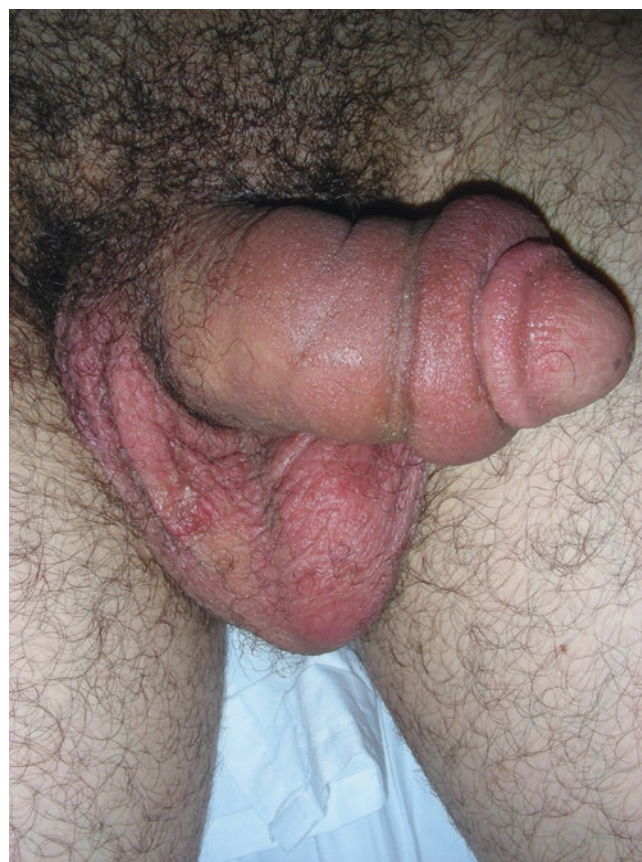

Fig. 34.1 Acute penile edema associated with angioedema of face. Note microvesicles

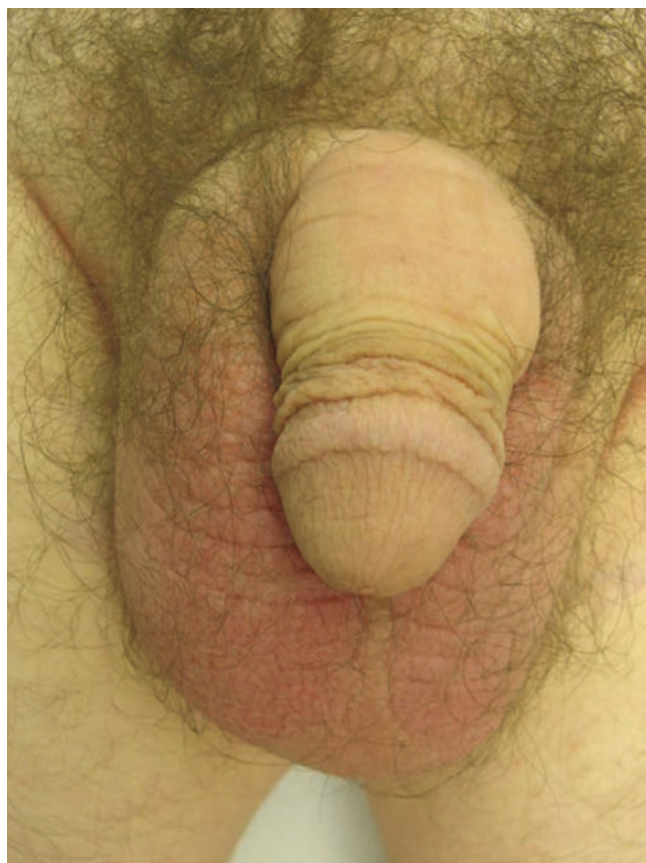


Fig. 34.2 Chronic idiopathic penile lymphedema (no cause found)

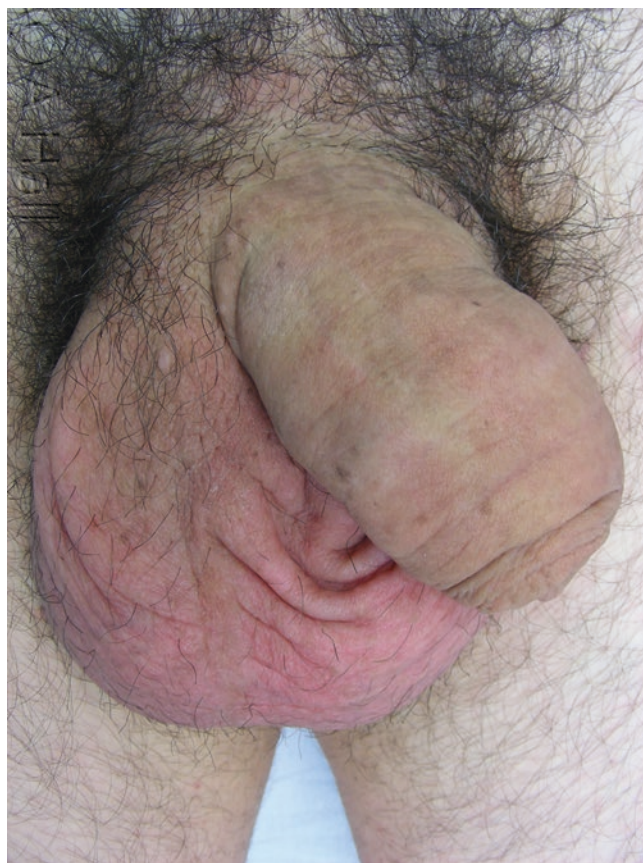

Fig. 34.3 Chronic penile lymphedema associated with Crohn's disease

tal swelling may begin in childhood. Genital lymphedema is initially painless swelling of the penile shaft and scrotum. Later, the glans and foreskin may become swollen. Aching, pain, recurrent infections and urinary difficulty become issues with progression of the disease. A past history of Crohn's disease, sarcoidosis, hidradenitis suppurativa, sexually transmissible infections (STIs) (lymphogranuloma venereum, syphilis), tuberculosis or an injected foreign substance (*eg*, silicone, paraffin) may help to make a diagnosis. Male patients are reluctant to volunteer information about foreign substances self-injected into their genitalia. Specific questioning about self-injection is necessary if genital swelling or lymphedema begins in adulthood. Chronic genital lymphedema has a significant negative impact on sexuality and quality of life. Patients may become socially isolated and have reduced mobility that leads to increasing obesity. Genital examination reveals non-tender swelling of the foreskin, shaft of the penis or scrotum. Obesity contributes to swelling of the suprapubic region. Abdominal, genital, testicular, and rectal examination is essential to detect lymphadenopathy, pelvic masses or malignancy. It is important to attempt to retract the fore-

skin to carefully examine the glans and the under surface (mucosal aspect) of the foreskin. Associated hidradenitis suppurativa may be evident. Erosions, ulcers, fissures, or fistulae may be visible on anogenital inspection, suggestive of perianal Crohn's disease [3].

34.4 Diagnosis

Chronic genital lymphedema is a clinical diagnosis, but investigations are necessary to try to determine specific etiology. Selection of investigations is guided by each clinical situation. Genital skin biopsy is important to detect granulomatous inflammation or granulomatous lymphangitis. Special stains for tuberculosis (Ziehl-Neelsen stain) and leprosy (Wade Fite stain) should be requested if appropriate. Exclude underlying Crohn's disease, hidradenitis suppurativa, amyloidosis, sarcoidosis, trauma, foreign bodies, malignancy and surgical or radiation treatment [4]. Useful blood tests include complete blood count, C-reactive protein, liver function, renal function, serum fasting glucose, angiotensin-converting enzyme, interferon-gamma release assay test (QuantiFERON-TB Gold test) and syphilis

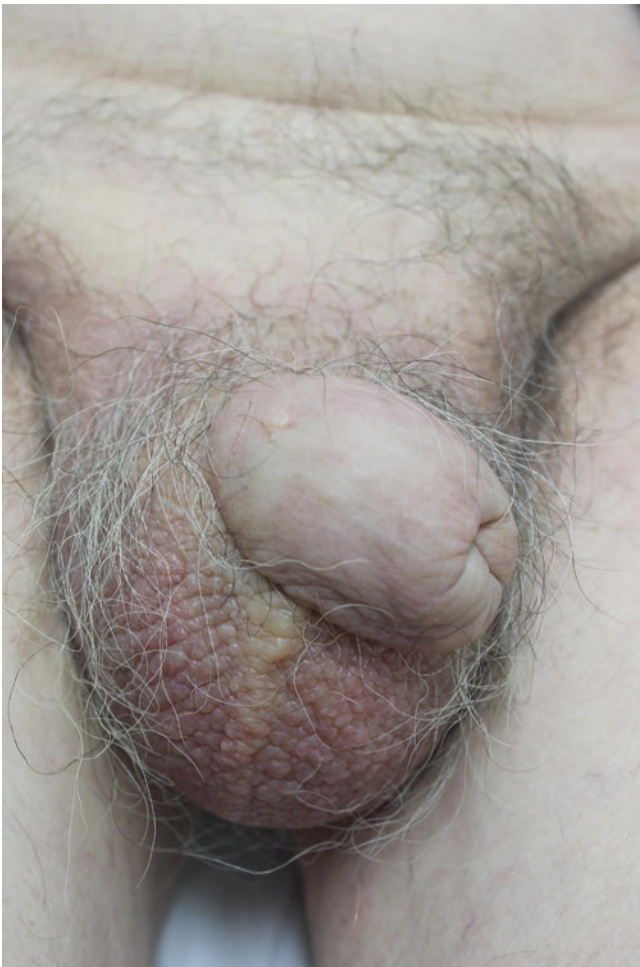

Fig. 34.4 Chronic penile lymphedema associated with Crohn's disease

serology. Serologic screening for occult malignancies should be considered, including prostate-specific antigen (PSA). Specific infections (filariasis, lymphogranuloma venereum) may need to be excluded if potentially relevant. If the patient is at risk for filariasis, microscopic examination of a blood smear obtained at night is the standard method of diagnosis. Alternatively serologic testing for filariasis (antifilarial IgG4) may be useful, but testing may be negative in established lymphedema. Imaging of the chest, abdomen, and pelvis (chest x-ray, CT, or MRI scans) may help to exclude tuberculosis, mass lesions and enlarged lymph nodes. Endoscopy (gastroscopy and colonoscopy) is important to exclude Crohn's disease. Further screening for occult malignancy is based on perceived risk.

34.5 Treatment

Genital lymphedema should be treated early because of its significant impact on quality of life and to prevent progression to scarring and fibrosis. Acute flares of genital edema

require removal or avoidance of the triggering allergen or irritant, an empiric course of systemic antibiotics and a short course of systemic corticosteroids. If a specific cause of chronic genital lymphedema is recognised, treatment is directed at the etiology of the genital lymphedema. Treatment of Crohn's disease includes immunosuppression (prednisone, prednisolone, azathioprine, 6-mercaptopurine), sulfasalazine, and anti-tumour necrosis factor (TNF) therapy (*eg*, infliximab, adalimumab). Long-term oral antibiotic prophylaxis (*eg*, macrolides, clindamycin, trimethoprim, ciprofloxacin) may reduce frequent recurrent genital cellulitis or erysipelas [5]. Treatments for established idiopathic chronic genital lymphedema include long-term oral antibiotics (*eg*, minocycline), mechanical or manual lymph drainage, compression therapy and surgery. Repeated intralesional injections of corticosteroids may benefit genital lymphedema, as intralesional corticosteroids may be beneficial for granulomatous cheilitis. Surgical debulking of excessive tissue of the foreskin, penile shaft, or scrotum (scrotal reduction) with split skin grafting may benefit established chronic genital lymphedema with fibrosis. Long-term compressive therapy has been shown to be effective for penile shaft lymphedema [6].

Pearls

- Chronic genital lymphedema (or edema) may be the initial presentation of Crohn's disease.
- Exclude Crohn's disease in patients with chronic genital lymphedema (or edema).

References

1. Murphy MJ, Kogan B, Carlson JA. Granulomatous lymphangitis of the scrotum and penis. Report of a case and review of the literature of genital swelling with sarcoidal granulomatous inflammation. *J Cutan Pathol*. 2001;28:419–24.
2. Barrick BJ, Tollefson MM, Schoch JJ, McEvoy MT, Hand JL, Wieland CN, Davis DM. Penile and scrotal swelling: an under-recognized presentation of Crohn's disease. *Pediatr Dermatol*. 2016;33:172–7.
3. Bunker CB, Shim TN. Male genital edema in Crohn's disease. *J Am Acad Dermatol*. 2014;70:385.
4. Reitsma W, Wiegman MJ, Damstra RJ. Penile and scrotal lymphedema as an unusual presentation of Crohn's disease: case report and review of the literature. *Lymphology*. 2012;45:37–41.
5. Porter W, Dinneen M, Bunker C. Chronic penile lymphedema: a report of 6 cases. *Arch Dermatol*. 2001;137:1108–10.
6. Facio MF, Spessoto LC, Gatti M, Ferraz Arruda PF, Ferraz Arruda JG, Antoniassi TS, et al. Clinical treatment of penile fibrosis after penoscrotal lymphedema. *Urol Case Rep*. 2017;11:14–6.

35.1 Definition

Male genital dysaesthesia is defined by its symptoms: burning, a hot sensation, irritation, discomfort or increased sensitivity to touch of the external genitalia, in the absence of other clinical disease.

35.2 Aetiology

This syndrome has various names, including male genital dysaesthesia, red scrotum syndrome (the original description [1]), burning scrotum syndrome, male genital burning syndrome, dysaesthetic penoscrotodynia and restless genital syndrome. The aetiology remains unknown. Many possible causes have been suggested, including neuropathy, localized erythromelalgia [2], neurovascular aetiology, excessive use of topical corticosteroids, contact allergy and a functional somatic symptom disorder [3]. Previous lower back pain or trauma has been associated with male genital dysaesthesia, but in most cases the association is probably coincidental and not causal. Flushing with telangiectatic rosacea of the face is often associated, suggesting a genetic tendency. Alcohol and caffeine have been postulated as triggers. While excessive use of genital topical corticosteroids ("steroid addiction") has been postulated as a cause, genital dysaesthesia occurs in patients who have not used any topical corticosteroids [4]. Vulvodynia in women is an analogous dysaesthesia that also has no recognized aetiology.

35.3 Clinical Features

Most patients are fair-skinned (skin phototypes 1 and 2) and over 50 years of age, but this disorder is also seen in younger men and has been reported in skin of colour patients. Variable symptoms reported including burning, a hot sensation, irritation, an "uncomfortable" sensation, increased sensitivity to touch (hyperesthesia), unprovoked pain, provoked pain (allodynia) and dyspareunia. Some men find wearing underpants

difficult. Symptoms may be aggravated by sitting. Itch is not a primary symptom but itch may be secondary to irritant dermatitis. The glans, foreskin, penile shaft, scrotum or entire external genitalia may be involved. It is important to enquire about numbness, motor weakness and sphincter incontinence to exclude possible neurological disease. A history of previous shingles (herpes zoster), lower back pain, trauma or surgery points to a possible underlying neurological cause, but the association with shingles, lower back pain or trauma may be coincidental rather than causal. Clinical examination of the anogenital region, groins, and proximal thighs should be normal except for possible increased sensitivity to light touch (cotton wool test). Redness of the anterior scrotum is not invariably present, but sharply defined redness of the anterior scrotum with sparing of the median raphe may be evident in very fair males (skin phototypes 1 and 2) (Figs. 35.1, 35.2, and 35.3).

35.4 Diagnosis

Diagnosis is clinical as there is no specific diagnostic test or investigation. Baseline screening includes a complete blood count, C-reactive protein, serum fasting glucose, vitamin B12 and syphilis serology. Syphilis serology testing is reassuring for patients who are fearful of a sexually transmissible infection (STI) or cancer. Biopsy of normal-appearing genital skin is not helpful and should be avoided. If itch is significant, patch testing to exclude possible contact allergens should be considered but is usually unhelpful. Computerised tomography (CT) or magnetic resonance imaging (MRI) of the lower back may be considered if there is a history of significant lower back pain, trauma, or surgery, but imaging of the lower spine is usually unhelpful.

35.5 Treatment

Male genital dysaesthesia may cause significant disruption to social and sexual relationships. Most men with genital dysaesthesia have seen many doctors, usually with little benefit.

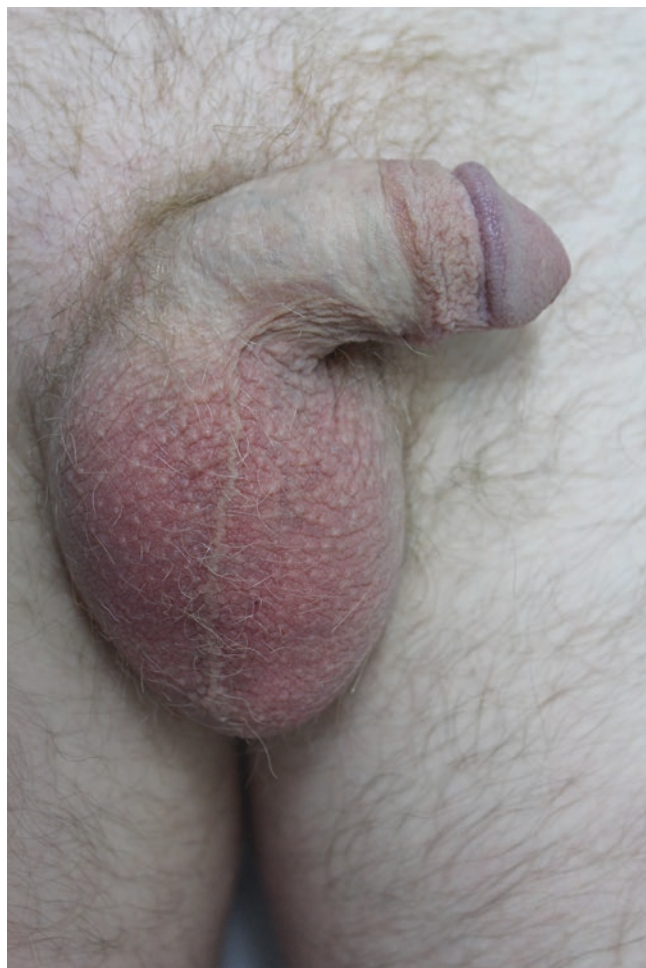


Fig. 35.1 Redness of the anterior scrotum in a male patient with genital dysaesthesia

Establishing a supportive, ongoing therapeutic relationship is important. Acknowledgement that genital dysaesthesia is a real disease and not imaginary helps the patient come to terms with this often frustrating disorder. Reassurance that there is no cancer or STI is very important. Reset the patient's expectation of treatment, aiming for a reduction in the severity of symptoms, rather than cure.

General measures include removing all irritants (including antibacterial washes and wipes), using a non-soap wash and a moisturiser regularly after washing. Bland emollients (eg, petrolatum or soft white paraffin) act as both a moisturiser and a lubricant for sexual activity. Wearing of loose-fitting underwear is sometimes beneficial. Keeping a "symptom diary" may help to recognise possible triggers. A trial of avoiding caffeine and alcohol may be worthwhile. Use of topical corticosteroids should be stopped. Cold compresses may provide temporary relief.

Specific treatments include low-dose amitriptyline (5–10 mg in the late afternoon), nortriptyline, doxycycline,

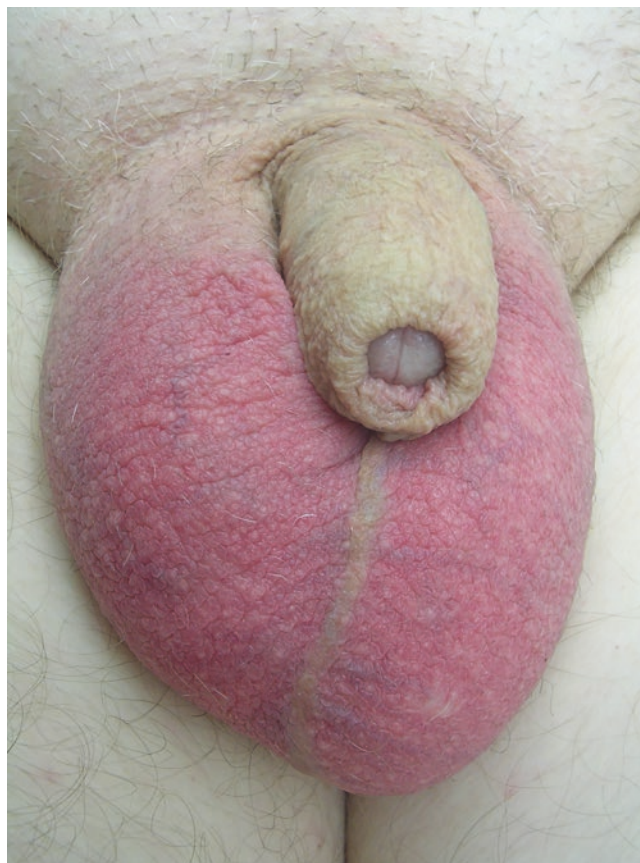

Fig. 35.2 Prominent redness of the anterior scrotum with sparing of the median raphe

gabapentin, pregabalin and serotonin-noradrenaline reuptake inhibitors (eg, duloxetine, venlafaxine). If these treatments fail or if the patient declines systemic treatment, useful alternatives include 1% menthol in aqueous cream, pimecrolimus 1% cream, tacrolimus 0.1% ointment, or topical lidocaine spray.

No treatment is universally successful. Treatment with oral corticosteroids and unproven surgical treatments should be avoided. Psychological or psychiatric support should be offered to severely distressed patients. Patience and persistence in the setting of a supportive therapeutic relationship are essential.

Pearls

- Male genital dysaesthesia is a common disorder causing burning, irritation, and significant distress.
- Males with genital dysaesthesia usually have a normal-appearing scrotum, without redness.
- Aim to reduce the severity of the symptoms of genital dysaesthesia, rather than cure.

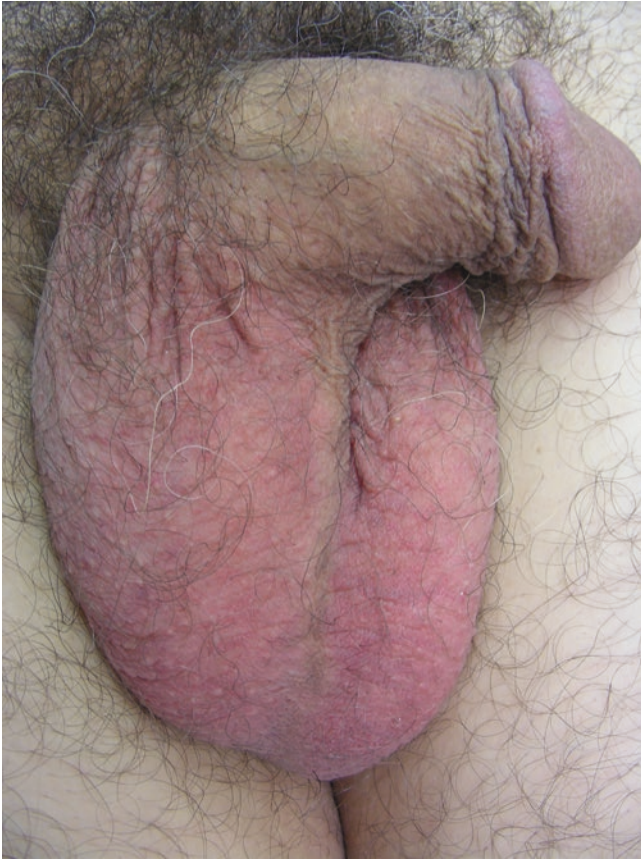

Fig. 35.3 Male patient with genital dysaesthesia

References

1. Fisher BK. The red scrotum syndrome. *Cutis*. 1997;60:139–41.
2. Prevost N, English JC 3rd. Case reports: red scrotal syndrome: a localized phenotypical expression of erythromelalgia. *J Drugs Dermatol*. 2007;6:935–6.
3. Anyasodor MC, Taylor RE, Bewley A, Goulding JM. Dysaesthetic penoscrotodynia may be a somatoform disorder: results from a two-centre retrospective case series. *Clin Exp Dermatol*. 2016;41:474–9.
4. Narang T, Kumaran MS, Dogra S, Saikia UN, Kumar B. Red scrotum syndrome: idiopathic neurovascular phenomenon or steroid addiction? *Sex Health*. 2013;10:452–5.

Superficial Thrombophlebitis of the Penis (Penile Mondor's Disease)

36

36.1 Definition

Penile Mondor's disease is superficial thrombophlebitis or thrombosis of the dorsal vein of the penis.

36.2 Aetiology

Penile Mondor's disease is commonly reported after vigorous, prolonged sexual activity. All aspects of Virchow's triad may play a role in pathogenesis: damage to the blood vessel wall, vascular stasis and hypercoagulability [1]. Vigorous, prolonged sexual or non-sexual physical activity damage a blood vessel wall, leading to altered blood flow. Similarly, physical trauma, surgery or injection of intravenous drugs into the dorsal penile vein may damage the vessel wall [2]. Hypercoagulability is important in the pathogenesis of Mondor's thrombophlebitis of the chest wall (often associated with malignancy) but thrombophilia is rarely associated with penile Mondor's disease. Penile Mondor's disease is not an infectious disease even though a patient may report a past sexually transmissible infection (STI). Penile Mondor's disease has been confused with sclerosing lymphangitis of the penis, which is a separate disease, differentiated from penile Mondor's disease by Doppler ultrasound. Penile Mondor's disease is thrombophlebitis of the dorsal penile vein and not a disease of penile lymphatics.

36.3 Clinical Features

Penile Mondor's disease is probably much more common than reported. Most patients are 20–40 years of age and present with a tender or asymptomatic cord-like swelling on the dorsum of the distal penile shaft (Figs. 36.1 and 36.2). Often there is a history of prior vigorous or prolonged sexual activity 24–48 hours earlier. Vigorous non-sexual physical activity may also precipitate penile Mondor's disease. Pain may be worse with erections, intercourse or masturbation [1]. Other genital symptoms (discharge, dysuria, fever) are not

reported. Examination reveals a palpable cord-like swelling on the dorsal aspect of the distal penile shaft, mid penile shaft or extending as far as the base of the penis and pubic region. Overlying redness or edema may be noted. The complete physical examination is otherwise normal.

36.4 Diagnosis

Diagnosis is primarily clinical, based on a history of the sudden appearance of a tender cord-like swelling on the dorsum of penile shaft [3]. As penile Mondor's disease results in distress for the patient, an accurate diagnosis is important. If the clinical diagnosis is in doubt, Doppler ultrasound scanning is the gold standard for diagnosis [4]. Doppler ultrasound scanning demonstrates non-compressibility of the dorsal vein of the penis. Doppler scanning helps to differentiate penile Mondor's disease from non-venereal sclerosing lymphangitis of the penis. Spontaneous resolution of penile Mondor's disease within a few weeks helps confirm the clinical diagnosis. Extensive investigations are not warranted unless there is clinical evidence for or suspicion of hypercoagulability or malignancy. Penile skin biopsy should be avoided. Differential diagnoses include sclerosing lymphangitis of the penis and Peyronie's disease.

36.5 Treatment

There is no specific treatment for penile Mondor's disease, which usually resolves spontaneously within 4–8 weeks [2, 4]. Reassurance that there is no evidence of a sexually transmissible infection (STI) or cancer is comforting to the patient. Abstinence from sexual activity and vigorous sport until complete resolution has occurred is important.

Symptomatic treatment may be necessary. Hot or cold compresses may ease pain and discomfort. Aspirin and non-steroidal anti-inflammatory medications are sometimes recommended but do not seem to shorten the duration of the disease [1]. Anticoagulant therapy should be avoided, as

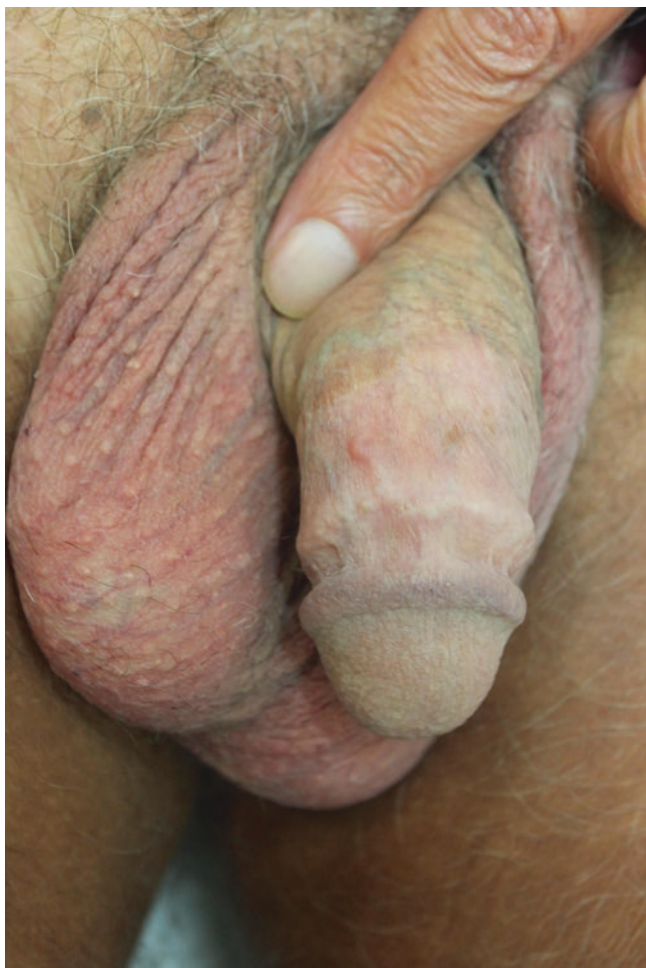

Fig. 36.1 Circumferential swelling proximal to the coronal sulcus (penile Mondor's disease)

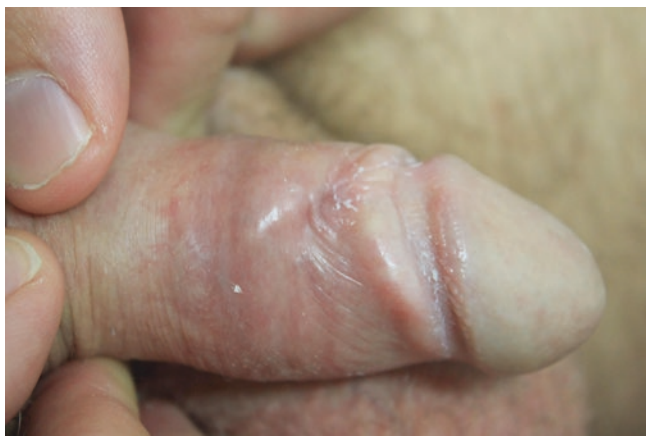

Fig. 36.2 Superficial thrombophlebitis proximal to the coronal sulcus of the penis

there is no proven benefit. Thrombectomy has been recommended if the clot persists beyond 6 weeks [2].

Recurrences are possible with further vigorous sexual or physical activity. Follow-up to confirm total resolution of penile superficial thrombophlebitis or thrombosis is important. Resolution helps confirm the clinical diagnosis.

Pearls

- Penile Mondor's disease follows vigorous or prolonged sexual activity.
- Penile Mondor's disease usually resolves spontaneously within 4–8 weeks.

References

1. Walsh JC, Pimboeuf S, Garvin DS. A common presentation to an uncommon disease. Penile Mondor's disease: a case report and literature review. *Int Med Case Rep J.* 2014;7:155–7.
2. Öztürk H. Penile Mondor's disease. *Basic Clin Androl.* 2014;24:5.
3. Polat H, Yucel MO, Gok A, Benlioglu C, Cift A, Sarica MA. Penile Mondor's disease: primum non nocere! *Urol J.* 2015;12(2):2096–8.
4. O'Neal JM, Castleberg E, Dinh VA. Diagnosis of Mondor's disease in the emergency department with bedside ultrasound. *Case Rep Emerg Med.* 2015;2015:817960.

37.1 Definition

Fixed drug eruption is a focal, circumscribed patch or plaque or a more extensive mucocutaneous reaction pattern occurring at same site each time the same drug is ingested.

37.2 Aetiology

The exact pathogenesis of fixed drug eruption is not completely known. Most likely, the causative drug combines with a protein hapten to stimulate an immunological response. A long list of prescribed and self-administered (“over-the-counter”) medications have been implicated in causing fixed drug eruption. The list of possible drugs varies with the type of clinician reporting, the prescribing habits and the geographic region. The drugs most commonly reported to the central register as causing fixed drug eruptions in the United Kingdom are antibiotics (trimethoprim, amoxicillin), nonsteroidal anti-inflammatory drugs (mefenamic acid, naproxen) and systemic antifungal agents (fluconazole). British dermatologists reported paracetamol, nonsteroidal anti-inflammatory drugs (mefenamic acid, ibuprofen, aspirin), sulphasalazine and anti-infective medications (fluconazole, tetracyclines, and trimethoprim) as the commonest drugs causing fixed drug eruptions [1]. In Pakistan, 73% of reported fixed drug eruptions were due to cotrimoxazole, with 20% of fixed drug eruptions occurring on genitalia [2]. In Qatar, the drugs most commonly associated with genital fixed drug eruptions were cotrimoxazole, tetracycline, and ampicillin [3]. Foods, preservatives and herbal medicines have also been implicated.

37.3 Clinical Features

Although fixed drug eruptions occur most commonly on limbs, they occur on genitalia in 20% of patients [2]. Most patients are 20–40 years of age. The fixed drug eruption may occur from 1 day to 2 months after drug exposure [4], but the

incubation period may be shorter if the patient has had prior exposure and sensitization. Most fixed drug eruptions are asymptomatic, but swelling, pruritus or pain may be reported. Restlessness, dysuria and urinary retention have been reported in boys with genital fixed drug eruption [5].

Variable clinical appearances have been described. Most fixed drug eruptions appear as a solitary erythematous or hyperpigmented patch or plaque. A dusky red, purple or pigmented annular patch or plaque with an erythematous “halo” and central bulla on glans, foreskin or penile shaft occurring within hours of taking an oral medicament that recurs following exposure to same drug is very suggestive of fixed drug eruption. A solitary hyperpigmented patch or plaque was commonest clinical presentation in a large study [2] but hyperpigmentation is usually seen with resolution of fixed drug eruption. Diagnostic difficulty occurs if genital fixed drug eruption is eroded or ulcerated (Fig. 37.1). Scaling, an erythematous patch, bullae or purpura are other common presentations (Fig. 37.2). Lesions may be single or multiple. Fixed drug eruption has been mistaken for a sexually transmissible infection (STI). In these cases, fixed drug eruption was reported following unprotected sexual intercourse when the female partner ingested a medication to which the male partner was sensitised [6–9]. This is probably a very rare event.

37.4 Diagnosis

Diagnosis of fixed drug eruption is not easy. Clinical suspicion is crucial, as the diagnosis is based on history and clinical findings with histopathological correlation. Genital fixed drug eruption may be confused with lichen planus, psoriasis, plasma cell (Zoon’s) balanitis, allergic contact dermatitis, erythema multiforme or a sexually transmissible infection, particularly herpes genitalis. Skin biopsy is necessary for histopathology correlation, as fixed drug eruption has atypical presentations including persistent fixed drug eruption. The typical histology of fixed drug eruption is a lichenoid reaction pattern or interface dermatitis with similarity to the

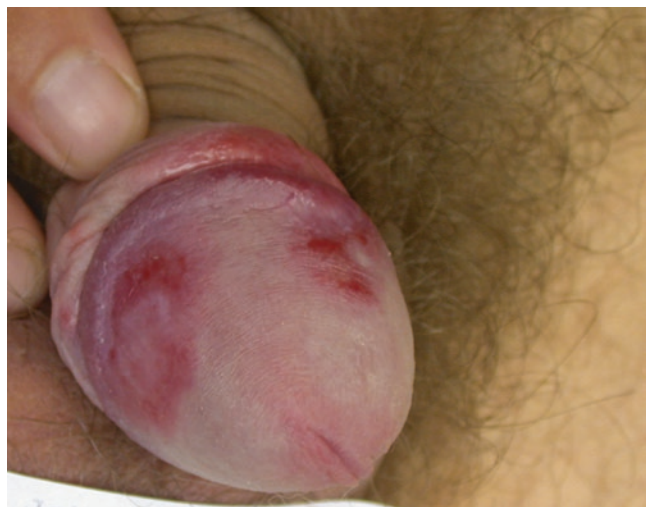

Fig. 37.1 Fixed drug eruption appearing as eroded, erythematous-violaceous plaque on the glans penis. Note the red “halo”

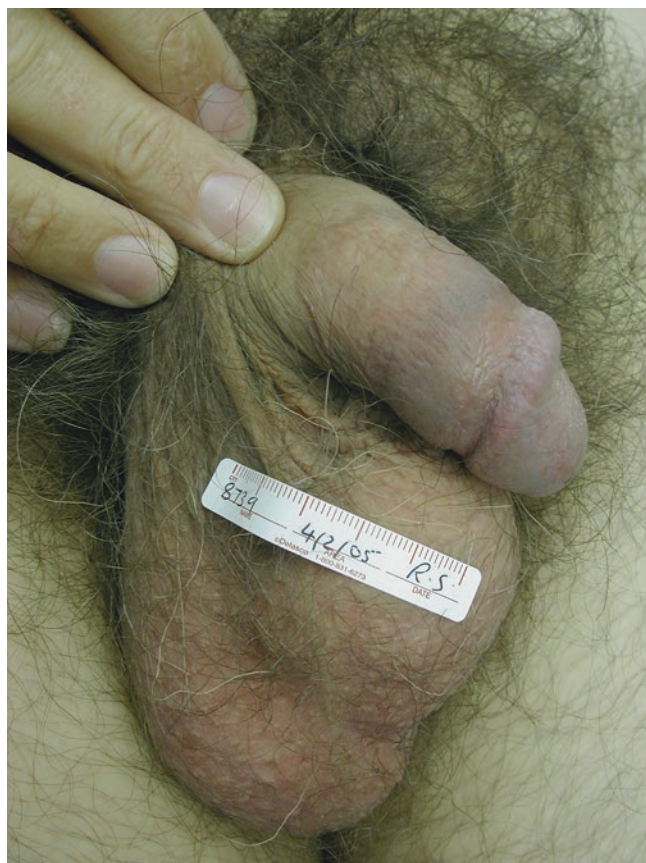

Fig. 37.2 Fixed drug eruption appearing as subtle, erythematous-pigmented annular plaque on the shaft of the penis

histology of erythema multiforme. A prominent vacuolar change with apoptotic basal layer Civatte bodies, an obscured dermoepidermal junction, and predominantly lymphocytic infiltrate extending to the epidermis and deeply into the dermis are usually seen. Neutrophils are seen in the inflamma-

tory cell infiltrate. Melanin incontinence is common. Very early lesions may show spongiosis, dermal edema and eosinophils in inflammatory infiltrate of the dermis. The bullous variant shows a subepidermal split [10].

Clinical challenge with the suspected drug may help to confirm the diagnosis. For ethical and logistical reasons, an oral provocation test of the suspect drug is not done routinely in clinical practice. Skin patch testing with a topical preparation of the ingested drug may be used to confirm the diagnosis and is safer [11].

37.5 Treatment

Recognition and avoidance of the causative drug is the cornerstone of management. Treatment with a moderately potent topical corticosteroid preparation is usually adequate. Alternatively, a short course of systemic corticosteroid may be used. Resolution usually occurs within 2–3 weeks once the offending drug is ceased.

Pearls

- A red or pigmented annular lesion of the genitals that recurs after ingestion of the same oral medication is suggestive of fixed drug eruption.
- Genital fixed drug eruption may be confused with a sexually transmissible infection.

References

1. Savin JA. Current causes of fixed drug eruption in the UK. *Br J Dermatol.* 2001;145:667–8.
2. Mahboob A, Haroon TS. Drugs causing fixed eruptions: a study of 450 cases. *Int J Dermatol.* 1998;37:833–8.
3. Gaffoor PMA, George WM. Fixed drug eruptions on the male genitals. *Cutis.* 1990;45:242–4.
4. Patel TK, Thakkar SH, Sharma D. Cutaneous adverse drug reactions in Indian population: a systematic review. *Indian Dermatol Online J.* 2014;5(Suppl 2):S76–86.
5. Nussinovitch M, Prais D, Ben-Amitai D, Amir J, Volovitz B. Fixed drug eruption in the genital area in 15 boys. *Pediatr Dermatol.* 2002;19:216–9.
6. Maatouk I, Moutran R, Fahed M, Helou J. A “sexually transmitted” fixed drug reaction. *Sex Transm Dis.* 2014;41:626–7.
7. Berger RE. Fixed drug eruption--a sexually inducible reaction? *J Urol.* 2005;173:1990.
8. Zavar V, Kirloskar M, Chuh A. Fixed drug eruption – a sexually inducible reaction? *Int J STD AIDS.* 2004;15:560–3.
9. Gruber F, Stasić A, Lenković M, Brajac I. Postcoital fixed drug eruption in a man sensitive to trimethoprim-sulphamethoxazole. *Clin Exp Dermatol.* 1997;22:144–5.
10. Weedon D. *Weedon's skin pathology.* 3rd ed. London: Churchill Livingstone; 2010. p. 50–1.
11. Lee AY. Topical provocation in 31 cases of fixed drug eruption: change of causative drugs in 10 years. *Contact Dermatitis.* 1998;38:258–60.

Darier's Disease and Papular Acantholytic Dyskeratosis

38

38.1 Definition

Darier's (Darier) disease is an autosomal dominantly inherited acantholytic disease characterised by keratotic papules and plaques of seborrhoeic areas on the trunk and flexures. *Papular acantholytic dyskeratosis* or acantholytic dermatosis of the anogenital region is a localised variant of Darier's disease that involves the groins and anogenital region.

38.2 Etiology

Darier's disease is inherited as an autosomal dominant disease due to mutation in the *ATP2A2* gene [1] but with marked variable phenotype (clinical expression). Spontaneous mutations occur. Papular acantholytic dyskeratosis or acantholytic dermatosis of anogenital region is caused by somatic mosaicism of the *ATP2A2* gene [2].

38.3 Clinical Features

Darier's disease affects both sexes equally but with marked variable clinical expression, even within the same family. Hyperkeratotic, skin-coloured to yellow or brown papules on the trunk and flexures first appear around adolescence (Figs. 38.1 and 38.2). Keratotic papules coalesce into widespread, malodorous, fissured and disfiguring keratotic plaques (Fig. 38.3). Vesiculobullous lesions may be seen. Moist, fissured plaques occur in flexures and the anogenital region (Figs. 38.4 and 38.5). Most patients complain of the cosmetic appearance of Darier's disease or of the odor. Palmoplantar pits and keratotic punctate keratoses (Fig. 38.6) with nail dystrophy are important clinical signs. Characteristic nail dystrophy with either white or alternating red and white longitudinal bands with V-shaped notching of the distal nail plate is almost pathognomonic for Darier's disease (Fig. 38.7). Dystrophic nail plate changes are usually seen in only one or two finger-

nails. Both oral and anogenital mucosal involvement may be seen. Darier's disease follows a chronic relapsing course throughout life and may temporarily clear. Flares are more common with heat, humidity, and sun exposure.

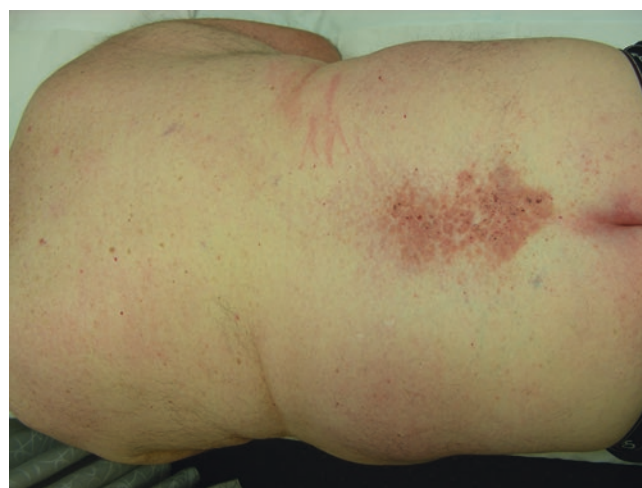


Fig. 38.1 Clustered keratotic papules of Darier's disease of lower back

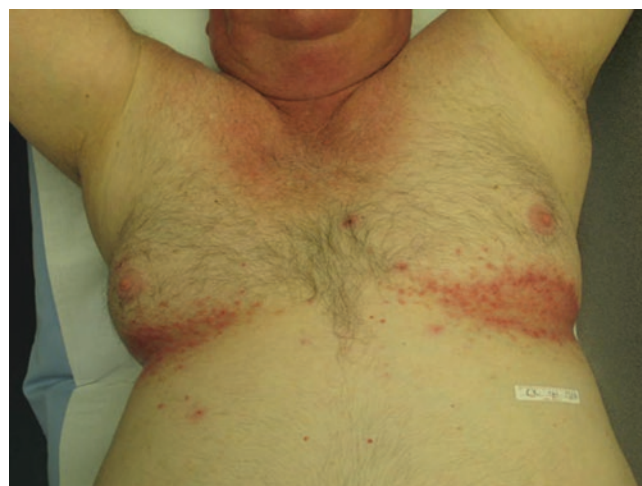

Fig. 38.2 Darier's disease of the submammary region

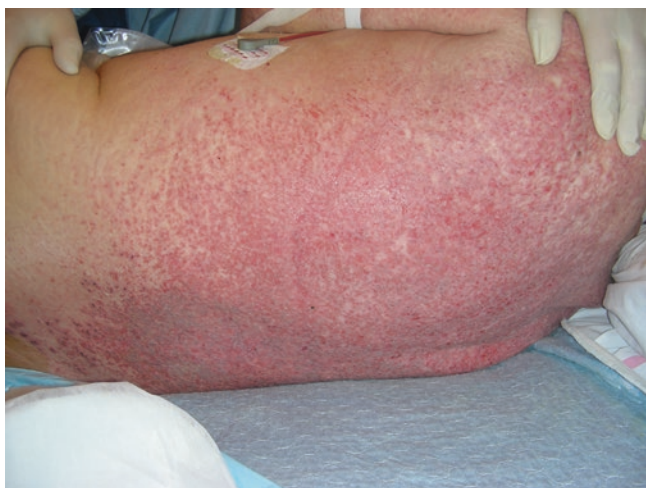

Fig. 38.3 Extensive Darier's disease of the back

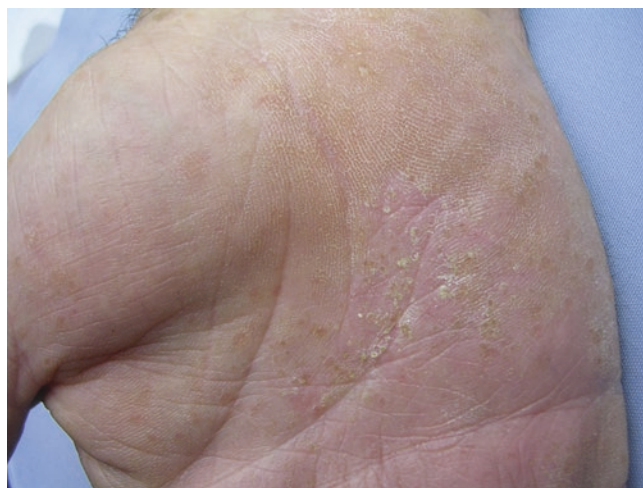

Fig. 38.6 Keratotic punctate palmar keratoses of Darier's disease

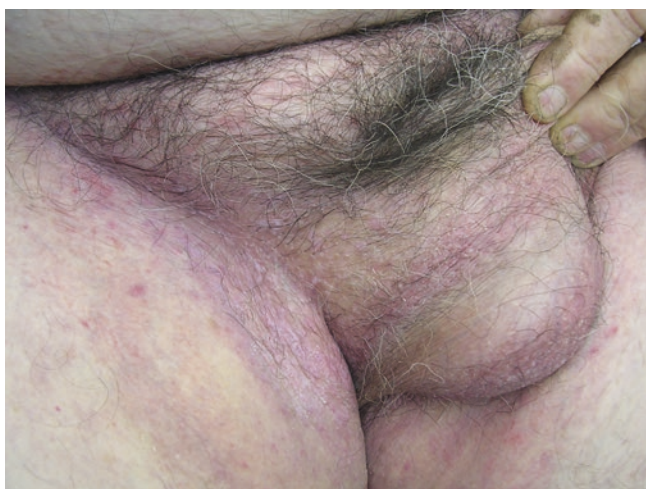

Fig. 38.4 Darier's disease of the inguinal region and scrotum

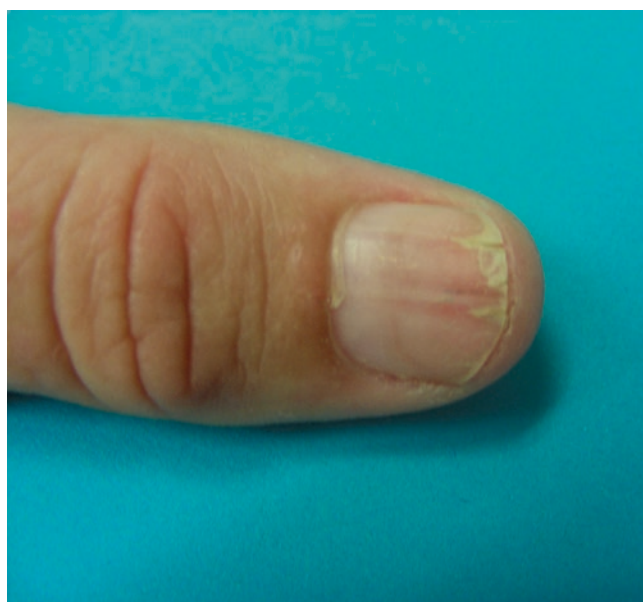

Fig. 38.7 Nail dystrophy with longitudinal bands and V-shaped notching of distal nail plate

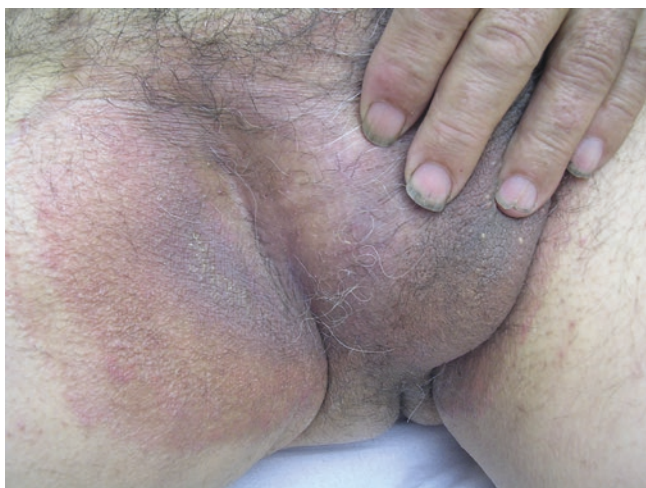

Fig. 38.5 Darier's disease of the inguinal region and scrotum

Darier's disease may be complicated by herpes simplex virus infection. Darier's disease often has debilitating effect on individuals, leading to major psychosocial issues and poorer quality of life.

Papular acantholytic dyskeratosis or acantholytic dermatosis of the anogenital region was first reported in women [3] and subsequently in males [4]. In male patients, papular acantholytic dyskeratosis presents as multiple pruritic papules and macerated patches in the groins and anogenital region that may be misdiagnosed as genital warts. Some patients have similar papules on the chest.

38.4 Diagnosis

Histological confirmation of the clinical diagnosis of Darier's disease is important. Histology of Darier's disease shows suprabasilar acantholysis with cleft formation (lacuna) of papules or plaques and overlying orthokeratotic plug. Dyskeratotic cells (corps ronds and grains) are seen above a suprabasilar cleft. Focal acantholytic dyskeratosis is not specific for Darier's disease and is seen in a variety of lesions, including papular acantholytic dyskeratosis. Clinical differential diagnoses of Darier's disease include seborrheic dermatitis, acne, Grover's disease, Hailey-Hailey disease, acanthosis nigricans, pemphigus vulgaris, pemphigus vegetans, confluent and reticulate papillomatosis and Dowling-Degos disease. Ano-genital Darier's disease and papular acantholytic dyskeratosis may be misdiagnosed as genital warts, leading to guilt and inappropriate treatments.

38.5 Treatment

Genetic counselling about the inheritance pattern of Darier's disease is most important. General management of inguinal and anogenital disease includes avoidance of irritants, use of non-soap wash, regular application of moisturiser, reduction of sweating, and avoidance of sunburn. Cool soaks and cool bathing may help. Specific treatment measures include careful use of a low-potency topical corticosteroid and treatment of superimposed infections. Topical antiseptics help to control flares of superficial infection. Treatment of Darier's disease of the groin and anogenital regions is limited by the irritancy of topical preparations. Other reported topical treatments include 5-fluorouracil [5], topical retinoids [6], and topical diclofenac [7]. Systemic therapies include doxycycline [8] and acitretin [9]. Physical treatments are reserved for patients with more severe disease or those for whom systemic treatments fail or are unsuitable. Physical treatments include photodynamic therapy (PDT) [10], superficial radiotherapy, and laser treatments [11–13].

Pearls

- Consider Darier's disease in any patient with chronic, relapsing flexural eruption.
- Nail dystrophy with white or alternating red and white longitudinal bands with V-shaped notching of the distal nail plate is almost pathognomonic for Darier's disease.
- Histological correlation is essential for diagnosis of Darier's disease.

References

1. Ikeda S, Mayuzumi N, Shigihara T, Epstein EH Jr, Goldsmith LA, Ogawa H. Mutations in *ATP2A2* in patients with Darier's disease. *J Invest Dermatol*. 2003;121:475–7.
2. Knopp EA, Saraceni C, Moss J, McNiff JM, Choate KA. Somatic *ATP2A2* mutation in a case of papular acantholytic dyskeratosis: mosaic Darier disease. *J Cutan Pathol*. 2015;42:853–7.
3. Krishnan RS, Ledbetter LS, Reed JA, Hsu S. Acantholytic dermatosis of the vulvocutaneous area. *Cutis*. 2001;67:217–9,220.
4. Wong TY, Mihm MC Jr. Acantholytic dermatosis localized to genitalia and crural areas of male patients: a report of three cases. *J Cutan Pathol*. 1994;21:27–32.
5. Knulst AC, De La Faille HB, Van Vloten WA. Topical 5-fluorouracil in the treatment of Darier's disease. *Br J Dermatol*. 1995;133:463–6.
6. English JC 3rd, Browne J, Halbach DP. Effective treatment of localized Darier's disease with adapalene 0.1% gel. *Cutis*. 1999;63:227–30.
7. Santos-Alarcon S, Sanchis-Sanchez C, Mateu-Puchades A. Diclofenac sodium 3% gel for Darier's disease treatment. *Dermatol Online J*. 2016;22(4):17.
8. Sfecci A, Orion C, Darrieux L, Tissae L, Safa G. Extensive Darier disease successfully treated with doxycycline monotherapy. *Case Rep Dermatol*. 2015;7:311–5.
9. Christophersen J, Geiger JM, Danneskiold-Samsøe P, Kragballe K, Larsen FG, Laurenberg G, et al. A double-blind comparison of acitretin and etretinate in the treatment of Darier's disease. *Acta Dermatol Venereol*. 1992;72:150–2.
10. Exadaktylou D, Kurwa HA, Calonje E, Barlow RJ. Treatment of Darier's disease with photodynamic therapy. *Br J Dermatol*. 2003;140:606–10.
11. Cannarozzo G, Bonciani D, Sannino M, Tamburi F, Morini C, Piccolo D, Nistico SP. Dye laser treatment for Darier's disease: results of a case series. *Photomed Laser Surg*. 2016;34:305–7.
12. Raszewska-Famielec M, Dudra-Jastrzebska M, Borecki A, Chodorowski G. Darier-white disease treated with fractional CO₂ laser in two cases. *Dermatol Ther*. 2015;28:254–7.
13. Beier C, Kaufmann R. Efficacy of erbium:YAG laser ablation in Darier disease and Hailey-Hailey disease. *Arch Dermatol*. 1999;135:423–7.

Hailey-Hailey Disease (Familial Benign Chronic Pemphigus)

39

39.1 Definition

Hailey-Hailey disease (familial benign chronic pemphigus) is a rare inherited disease characterised by variable episodic or persistent maceration, erosions, or blistering of intertriginous regions.

39.2 Aetiology

Hailey-Hailey disease is inherited as an autosomal dominant disease caused by heterozygous mutations in the *ATP2C1* gene [1, 2] with variable expression.

39.3 Clinical Features

Hailey-Hailey disease presents in adulthood with variable severity of episodic or persistent maceration, painful fissures (rhagades), erosive malodorous plaques (vegetations) or blistering of intertriginous regions. The main intertriginous sites are the axillae, inguinal regions and perineum (Figs. 39.1 and 39.2). These intertriginous sites are usually symmetrically involved. Submammary regions, the sides of the neck and other sites of friction may be involved (Koebner phenomenon). Hailey-Hailey disease may present primarily in inguinal, genital and perineal regions with weeping and irritation. Affected individuals mainly complain of itch, pain, or malodour of intertriginous sites. Social embarrassment often leads to a reduced quality of life. Involvement of the genital and perineal region often has negative impact on sexual and psychological quality of life.

Helpful clues to diagnosis include the longitudinal white bands of fingernail plates seen in some patients. Infrequently, Hailey-Hailey disease is a more severe, widespread disease. Extensive and painful disease may be very disabling and affect mobility. Hailey-Hailey disease occasionally involves mucosae. Hailey-Hailey disease does not have any systemic involvement. Rarer variants include segmental disease fol-

lowing Blaschko's lines, representing postzygotic mosaicism. Like Darier's disease, Hailey-Hailey disease often follows a chronically relapsing course with remissions and relapses. Relapses may be triggered by sweat, friction, sun exposure or secondary infection. Hailey-Hailey disease may become secondarily infected with pyogenic bacteria or herpes simplex virus. Squamous cell carcinoma has been reported to arise on the genitalia of a male patient with Hailey-Hailey disease [3] and on the vulva of a female patient with Hailey-Hailey disease of the vulva [4].

39.4 Diagnosis

Diagnosis of Hailey-Hailey disease is based on correlation of clinical and histologic features. Clinical features of episodic or persistent maceration, erosions or blistering of symmetrical intertriginous regions with a positive family history are very suggestive of Hailey-Hailey disease. Histology of the involved skin demonstrates suprabasilar acantholysis ("dilapidated brick wall" appearance) with negative direct immunofluorescence. Suprabasilar acantholysis is more widespread in Hailey-Hailey disease than in Darier's disease. Vesicle formation with clefting may be seen, whereas dyskeratosis is less prominent than in Darier's disease. Clinical differential diagnoses of Hailey-Hailey disease include irritant dermatitis (intertrigo), allergic contact dermatitis, impetigo, candidiasis, tinea, flexural Darier's disease and pemphigus vegetans.

39.5 Treatment

Management of Hailey-Hailey disease is often difficult, with remissions and relapses. General management is similar to the management of Darier's disease, including genetic counselling, general hygiene and washing, reduction of sweating and treatment of superimposed infections. Bleach baths may help to reduce the bacterial load and superimposed infection.

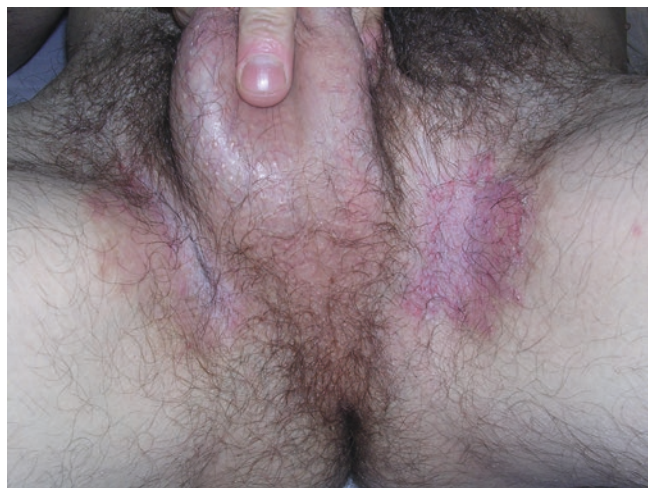


Fig. 39.1 Hailey-Hailey disease as a symmetrical irritated inguinal eruption (intertrigo)

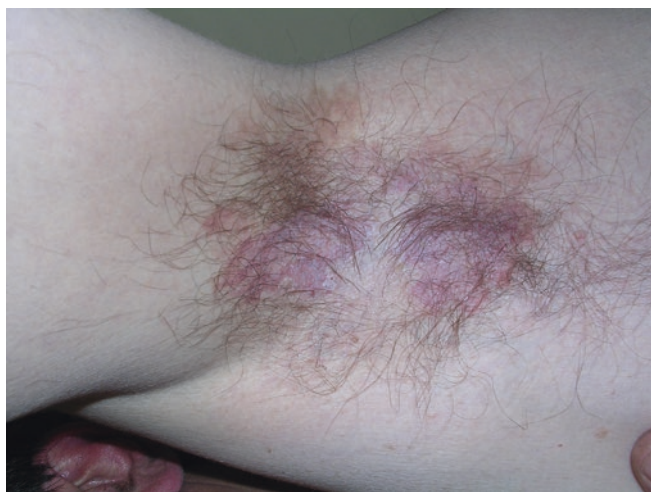

Fig. 39.2 Hailey-Hailey disease symmetrically involving the axillae

Specific treatment includes judicious use of a low-potency corticosteroid cream and topical antibiotics [5]. Alternative topical treatments include topical tacrolimus [6], alternating topical tacrolimus with potent topical corticosteroid [7] and topical calcitriol [8]. Botulinum toxin reduces sweat production and has been used for Hailey-Hailey disease [9]. Systemic therapies include oral antibiotics, oral corticosteroids, oral retinoids [10, 11], methotrexate and oral cyclosporin [12]. Low-dose oral naltrexone has shown benefit [13]. Ultraviolet B therapy [14], photodynamic therapy [15], laser treatment [16, 17] and electron beam radiation [18] have all helped patients with Hailey-Hailey disease. Superficial radiotherapy offers short-term improvement but

not lasting remission [19]. Surgical treatments include dermabrasion and excision with skin grafting [20]. Targeted therapies (biologic treatments) have not yet shown benefit for patients with Hailey-Hailey disease.

Pearls

- Hailey-Hailey disease is commonly misdiagnosed as irritant dermatitis (intertrigo).
- Longitudinal white fingernail bands are a diagnostic clue for Hailey-Hailey disease.

References

1. Majore S, Biolcati G, Barboni L, Cannistraci C, Binni F, Crisi A, et al. *ATP2C1* gene mutation analysis in Italian patients with Hailey-Hailey disease. *J Invest Dermatol*. 2005;125:933–5.
2. Zhang XQ, Wu HZ, Li BX, Xu YS, Wu JB, Lin LL, et al. Mutations in the *ATP2C1* gene in Chinese patients with Hailey-Hailey disease. *Clin Exp Dermatol*. 2006;31:702–5.
3. Chun SI, Whang KC, Su WP. Squamous cell carcinoma arising in Hailey-Hailey disease. *J Cutan Pathol*. 1988;15:234–7.
4. Cockayne SE, Rassl DM, Thomas SE. Squamous cell carcinoma arising in Hailey-Hailey disease of the vulva. *Br J Dermatol*. 2000;142:540–2.
5. Aroroa H, Bray FN, Cervantes J, Falto Aizpurua LA. Management of familial benign chronic pemphigus. *Clin Cosmet Investig Dermatol*. 2016;9:281–90.
6. Rocha Paris F, Fidalgo A, Baptista J, Caldas LL, Ferreira A. Topical tacrolimus in Hailey-Hailey disease. *Int J Tissue React*. 2005;27:151–4.
7. Umar SA, Bhattacharjee P, Brodell RT. Treatment of Hailey-Hailey disease with tacrolimus ointment and clobetasol propionate foam. *J Drugs Dermatol*. 2004;3:200–3.
8. Rajpara SM, King CM. Hailey-Hailey disease responsive to topical calcitriol. *Br J Dermatol*. 2005;152:916–7.
9. Charlton OA, Stewart TJ, Rosen RH. Treatment of Hailey-Hailey disease with botulinum toxin. *Australas J Dermatol*. 2018;59:229–31. <https://doi.org/10.1111/ajd.12726>.
10. Mashiko M, Akiyama M, Tsuji-Abe Y, Shimizu H. Bacterial infection-induced generalized Hailey-Hailey disease successfully treated by etretinate. *Clin Exp Dermatol*. 2006;31:57–9.
11. Hunt MJ, Salisbury EL, Painter DM, Lee S. Vesiculobullous Hailey-Hailey disease: successful treatment with oral retinoids. *Australas J Dermatol*. 1996;37:196–8.
12. Berth-Jones J, Smith SG, Graham-Brown RA. Benign familial chronic pemphigus (Hailey-Hailey disease) responds to cyclosporin. *Clin Exp Dermatol*. 1995;20:70–2.
13. Albers LN, Arbiser JL, Feldman RJ. Treatment of Hailey-Hailey disease with low dose naltrexone. *JAMA Dermatol*. 2017;153:1018–20.
14. Hayakawa K, Shiohara T. Coexistence of psoriasis and familial benign pemphigus: efficacy of ultraviolet B treatment. *Br J Dermatol*. 1999;140:374–5.
15. Ruiz-Rodriguez R, Alvarez JG, Jaén P, Acevedo A, Córdoba S. Photodynamic therapy with 5-aminolevulinic acid for recalcitrant familial benign pemphigus (Hailey-Hailey disease). *J Am Acad Dermatol*. 2002;47:740–2.

16. Christian MM, Moy RL. Treatment of Hailey-Hailey disease (or benign familial pemphigus) using short pulsed and dwell time carbon dioxide lasers. *Dermatol Surg*. 1999;25:661–3.
17. Beier C, Kaufmann R. Efficacy of erbium:YAG laser ablation in Darier disease and Hailey-Hailey disease. *Arch Dermatol*. 1999;135:423–7.
18. Graham PM, Melkonian A, Fivenson D. Familial benign chronic pemphigus (Hailey-Hailey disease) treated with electron beam radiation. *JAAD Case Rep*. 2016;2:159–61.
19. Roos DE, Reid CM. Benign familial pemphigus: little benefit from superficial radiotherapy. *Australas J Dermatol*. 2002;43:305–8.
20. Aroroa H, Bray FN, Cervantes J, Falto Aizpurua LA. Management of familial benign chronic pemphigus. *Clin Cosmet Investig Dermatol*. 2016;9:281–90.

40.1 Definition

Hidradenitis suppurativa (acne inversa) is a chronic autoinflammatory disease with recurrent nodules, abscesses, sinuses and scarring of intertriginous and anogenital regions, with significant comorbidities.

40.2 Aetiology

The exact pathogenesis of hidradenitis suppurativa is unclear. Hidradenitis suppurativa falls within the spectrum of autoinflammatory disorders [1]. Hidradenitis suppurativa was originally seen as a disorder of apocrine sweat glands (acne inversa), with follicular occlusion leading to disruption of hair follicles. Association of hidradenitis suppurativa with acne conglobata, pilonidal sinus and dissecting folliculitis of the scalp was referred to as the *follicular occlusion triad*. Hidradenitis suppurativa is now believed to be a disease of the follicular epithelium involving a complex interplay of inflammation, genetics, smoking, obesity, metabolic disturbance, microbiome, barrier dysfunction, and environmental factors. Various proinflammatory cytokines, including interleukin-1 β and tumour necrosis factor- α , are involved in driving the autoinflammatory disease.

40.3 Clinical Features

Hidradenitis suppurativa usually begins after puberty and before 40 years of age. Females are more commonly affected than males. Usually there is an insidious onset of erythema, discomfort, pruritus and hyperhidrosis that progresses to tender nodules and painful, malodorous, discharging sinuses, causing psychological and sexual dysfunction. Papules, inflammatory nodules, and discharging abscesses occur symmetrically in axillary (Figs. 40.1 and 40.2), inguinal, gluteal, perineal, and anogenital regions, as well as the inner thighs (Figs. 40.3 and 40.4). Submammary and intermammary

regions are involved in women. The nape of the neck, back, chest and waist may be involved if the disease is more severe. Nodules and abscesses may resolve or leave ulcers, scars, or sinus tracts. Polyporous or multi-headed comedones may be seen and aid clinical diagnosis (Fig. 40.5).

The psychological impact of hidradenitis suppurativa is great. Depression is common. Anogenital involvement has a marked negative impact on sexual quality of life. Resultant scarring further contributes to reduced quality of life [2].

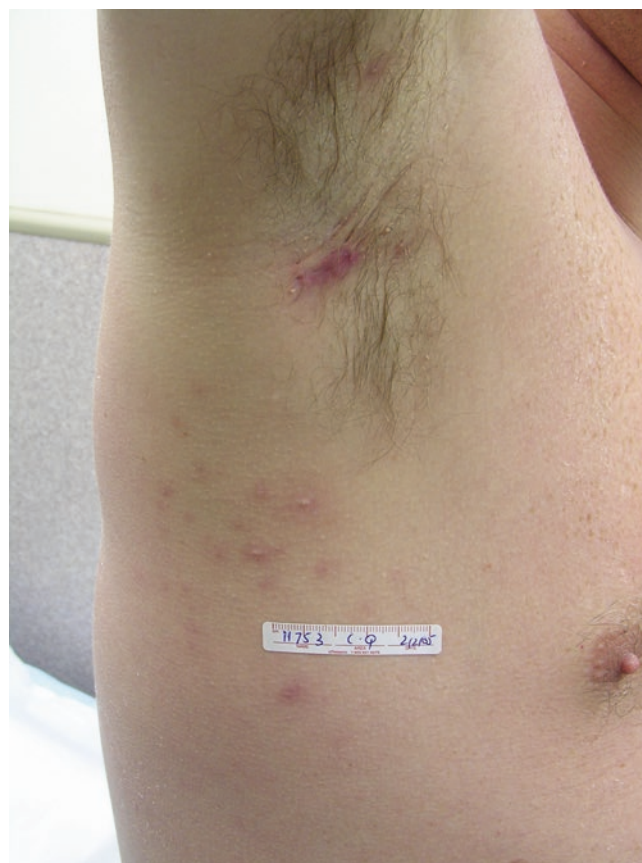


Fig. 40.1 Mild hidradenitis suppurativa of the axilla with papules and scarring

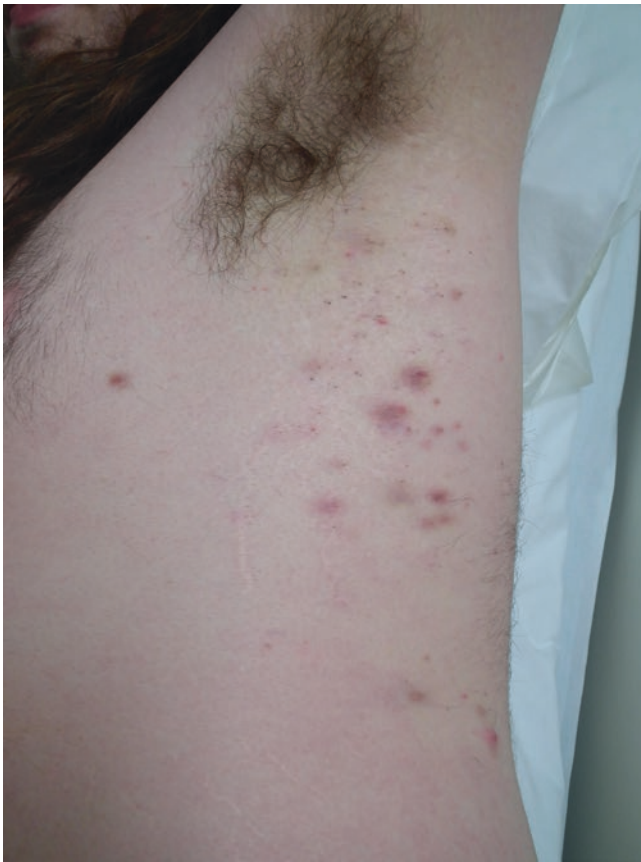

Fig. 40.2 Hidradenitis suppurativa of axilla with papulo-nodules, comedones, and early scarring

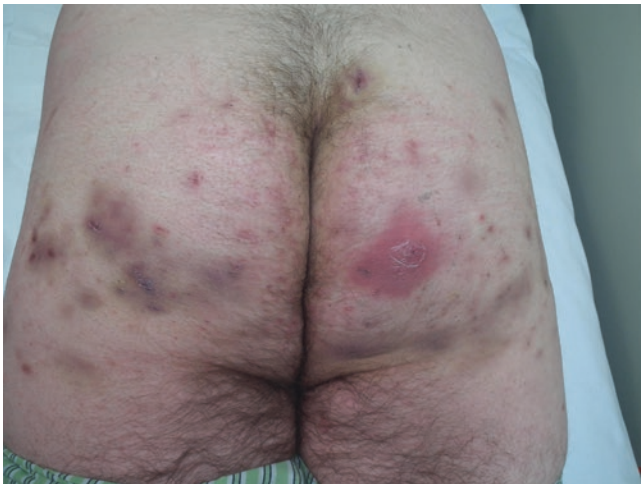

Fig. 40.3 Severe hidradenitis suppurativa of the buttocks with inflammatory nodules and marked scarring

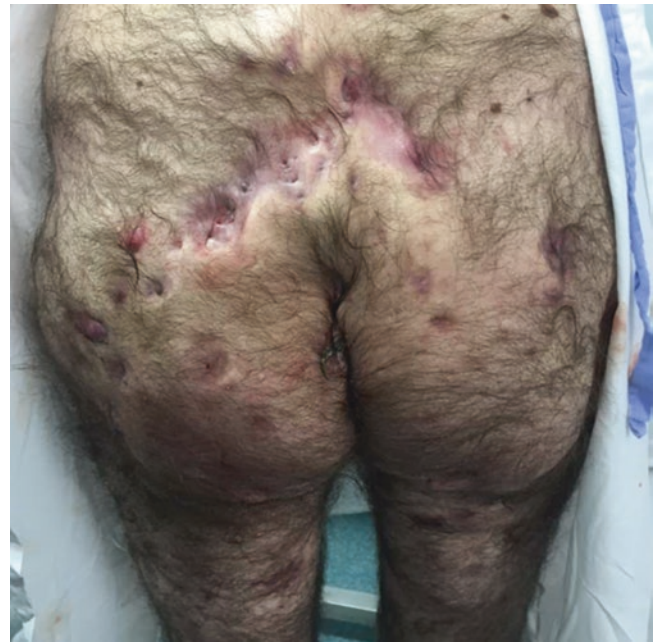

Fig. 40.4 Severe scarring of the gluteal region with sinus tracts

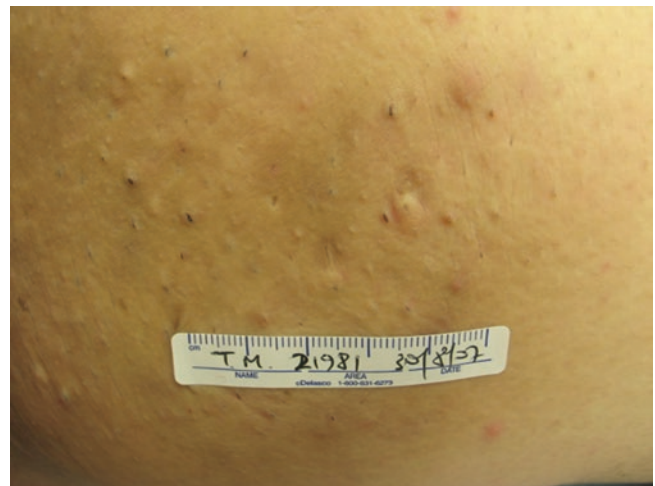


Fig. 40.5 Close up of papulo-nodules, comedones and early scarring of hidradenitis suppurativa

Comorbidities include smoking, obesity, acne, metabolic syndrome (obesity, hyperlipidemia, insulin resistance, diabetes, hypertension), cardiovascular disease, polycystic ovary syndrome (in women), depression, pilonidal sinus, spondyloarthropathy and inflammatory bowel disease (Crohn's disease). Complications include chronic lymphedema and cutaneous squamous cell carcinoma (SCC) (Fig. 40.6). Cutaneous squamous cell carcinoma may arise in perineal or anogenital hidradenitis suppurativa [3].

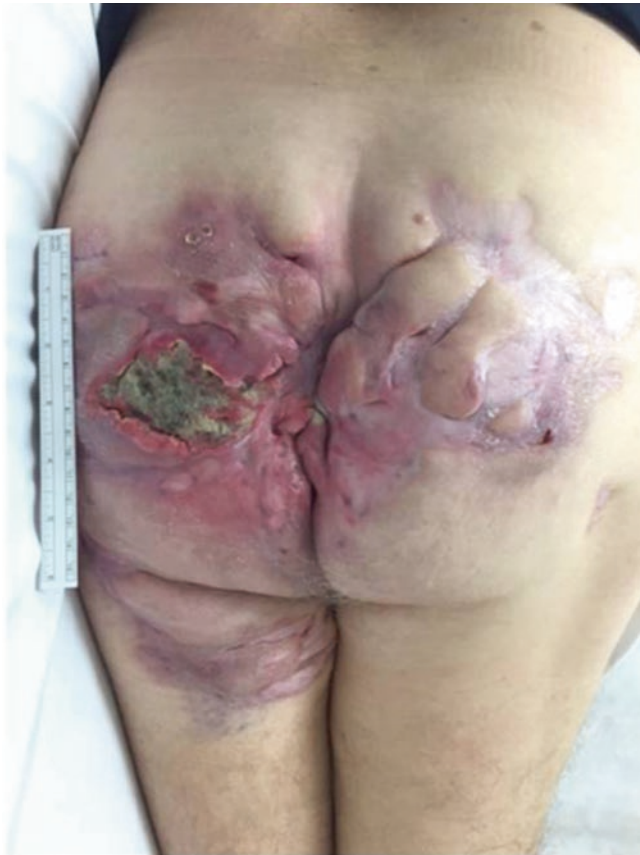

Fig. 40.6 Ulcerating squamous cell carcinoma complicating chronic hidradenitis suppurative of the gluteal region

40.4 Diagnosis

Hidradenitis suppurativa is a clinical diagnosis based on typical lesions (nodules, abscesses, sinus tracts), occurring at certain anatomical sites (axillae, submammary or intermammary areas, groins, perineum, perianal area, buttocks) and following a chronic course with relapses. The diagnosis of hidradenitis suppurativa is often delayed by an average of 7 years. Hidradenitis suppurativa is often misdiagnosed as folliculitis or boils (furuncles), resulting in inappropriate treatments that may add to morbidity. Skin swabs, complete blood count, erythrocyte sedimentation rate (ESR) or C-reactive protein (CRP) are useful baseline tests. Tests to detect comorbidities (anaemia, hyperlipidemia, diabetes) are important. Skin biopsy is not helpful in the initial diagnosis of hidradenitis suppurativa, but is important if a lesion is suspicious for a squamous cell carcinoma (SCC). Tissue imaging (ultrasonography and magnetic resonance imaging

(MRI) is not helpful in the initial diagnosis of hidradenitis suppurativa but ultrasonography or MRI are useful to detect deep abscesses of the buttock or perianal disease. Colonoscopy is important to exclude Crohn's disease in cases of perianal or buttock involvement. Differential diagnoses include epidermal (epidermoid) cysts, pilonidal cysts or abscess, erysipelas, Crohn's disease, lymphogranuloma venereum, granuloma inguinale and cutaneous tuberculosis.

40.5 Treatment

Management of a patient with hidradenitis suppurativa is difficult and requires a holistic approach. There is currently no curative treatment. It is essential to focus treatment on the patient, local skin disease, comorbidities and complications. Education on the nature of hidradenitis suppurativa and sympathetic ongoing care and support are important. General measures include encouragement to reduce weight, increase physical activity and cease smoking (although smoking cessation may not improve the disease). Pain management and wound care management are important issues. The use of antiseptic and antibacterial washes, avoidance of skin irritants and wearing of loose clothing should be encouraged. Mild disease with local abscesses without scarring (Hurley I) is treated with topical clindamycin 1% (twice daily for 3 months) or topical resorcinol. Oral antibiotics (doxycycline, minocycline or clindamycin with rifampicin) are used for patients with moderate disease with multiple lesions, recurrent abscesses, and scarring (Hurley I–II) or if topical therapy has failed. Metformin may help an obese patient with insulin resistance. For more severe disease with interconnected sinus tracts and abscesses (Hurley III), systemic antibiotic therapy, intralesional corticosteroids, a short course of oral corticosteroids, systemic retinoids (acitretin) and biologic agents (targeted therapies) are necessary. Infliximab and adalimumab are the biologic agents that have been most studied and have shown good efficacy. Targeted (biologic) therapies blocking interleukin-1 β (including anakinra) and interleukin-1 α are being trialled.

Surgical treatments include local excision, derofing and wide excision and skin grafting [4]. Incision and drainage of an inflamed nodule relieves pain, but the recurrence rate is up to 100% [5]. As wide radical excision has significant recurrence rates, attempts at heroic surgery should be approached with caution [5]. Surgical treatment is reserved for severe and disabling late-stage disease with sinuses and fistulae [6]. The use of light- and laser-based treatments has been reported with variable and inconclusive results [7].

Pearls

- Hidradenitis suppurativa is commonly misdiagnosed as boils.
- Comorbidities of hidradenitis suppurativa include depression and reduced quality of life.
- Squamous cell carcinoma is an important complication of anogenital hidradenitis suppurativa.

References

1. Vekic DA, Frew J, Cains GD. Hidradenitis suppurativa, a review of pathogenesis, associations and management. Part 1. *Australas J Dermatol*. 2018; <https://doi.org/10.1111/ajd.12770>. [Epub ahead of print].
2. von der Werth JM, Jemec GB. Morbidity in patients with hidradenitis suppurativa. *Br J Dermatol*. 2001;144:809–13.
3. Maclean GM, Coleman DJ. Three fatal cases of squamous cell carcinoma arising in chronic perineal hidradenitis suppurativa. *Ann R Coll Surg Engl*. 2007;89:709–12.
4. Vekic DA, Cains GD. Hidradenitis suppurativa, a review of pathogenesis, associations and management. Part 2. *Australas J Dermatol*. 2018; <https://doi.org/10.1111/ajd.12766>. [Epub ahead of print].
5. Ritz JP, Runkel N, Haier J, Buhr HJ. Extent of surgery and recurrence rate of hidradenitis suppurativa. *Int J Color Dis*. 1998;13: 164–8.
6. Lam J, Krakowski AC, Friedlander SF. Hidradenitis suppurativa (acne inversa): management of a recalcitrant disease. *Pediatr Dermatol*. 2007;24:465–73.
7. Levoska MA, Nicholson CL, Hamzavi IH. A retrospective review of light- and laser-based management of hidradenitis suppurativa. *Semin Cutan Med Surg*. 2017;36:67–74.

41.1 Definition

Pemphigus and pemphigoid (bullous pemphigoid) are autoimmune, vesiculo-bullous diseases affecting the skin and mucosae. Pemphigus and pemphigoid may involve the ano-genital region.

41.2 Aetiology

Pemphigoid and pemphigus vulgaris are the most important immuno-bullous diseases that may involve the ano-genital region. Autoantibodies are directed against skin and mucosal antigens, leading to loss of cellular adhesion resulting in erosions, vesicles, and bullae. In bullous pemphigoid, circulating autoantibodies are directed against a 230-kD bullous pemphigoid antigen (BPAG1) or a 180-kD antigen (BPAG2). In pemphigus vulgaris and its variant, pemphigus vegetans, circulating autoantibodies are directed against desmoglein 3. In pemphigus foliaceus, the main targeted antigen is desmoglein 1, also occasionally seen in pemphigus vulgaris. A variety of different autoantibodies occur with cicatricial pemphigoid (mucous membrane pemphigoid).

41.3 Clinical Features

The ano-genital region is not commonly involved in immuno-bullous diseases. Erosions and vesiculo-bullous lesions are mostly seen on lower limbs with bullous pemphigoid (Figs. 41.1 and 41.2), on the trunk and oral mucosa with pemphigus vulgaris, in flexures with pemphigus vegetans and in seborrhoeic distribution with pemphigus foliaceus. In pemphigus vulgaris, the commonest mucosal site is the mouth, while the ano-genital mucosa is the second most common mucosal site. Ano-genital mucosal pemphigus vulgaris results in painful erosions and fissuring. Oral mucosal erosions occur less commonly in pemphigoid (10–30% of patients) than in pemphigus vulgaris, and ano-genital

involvement is much less common in pemphigoid. Both pemphigoid and pemphigus vulgaris may produce erosive disease confined to male genitalia in the absence of disease at other sites. Painful, red erosions with white maceration and fissuring occur on the glans, coronal sulcus and penile shaft (Fig. 41.3). After initially presenting as genital disease, erosions may later occur in the mouth (Fig. 41.4), followed by erosions, vesicles, or bullae at other sites (Fig. 41.5). Careful examination of all mucosal sites should be performed with a full skin examination. Oral mucosal involvement is occasionally seen in pemphigus vegetans but is very rare in pemphigus foliaceus. Oral mucosa and conjunctivae are commonly affected in cicatricial pemphigoid, but ano-genital mucosa may also be involved.

41.4 Diagnosis

Clinico-pathologic correlation is important in the diagnosis of pemphigoid and pemphigus vulgaris. Pemphigoid and pemphigus vulgaris should be included in the differential diagnosis of any patient with erosive penile disease. The main differential diagnoses of erosive penile disease include infections (herpes genitalis, syphilis, candidiasis), erosive lichen planus, fixed drug eruption, plasma cell (Zoon's) balanitis, aphthae, penile intraepithelial neoplasia (PIN) (erythroplasia of Queyrat, Bowen's disease) and early invasive squamous cell carcinoma (SCC).

Skin biopsy is essential to confirm a diagnosis of pemphigoid or pemphigus vulgaris and to exclude other differential diagnoses. Formalin-fixed tissue and a fresh skin biopsy specimen for direct immunofluorescence should be submitted for histological examination. Pemphigoid shows a sub-epidermal split with linear staining of the basement membrane zone for IgG by direct immunofluorescence. Pemphigus vulgaris shows suprabasilar acantholysis, with basal keratinocytes appearing like a "row of tombstones" with intercellular staining predominantly for IgG by direct immunofluorescence. Circulating autoantibodies may be

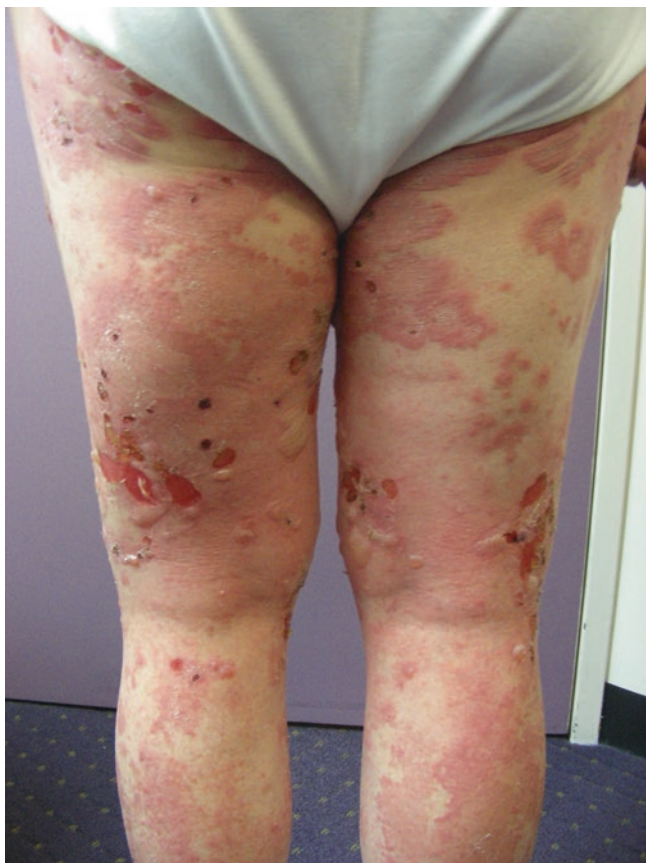

Fig. 41.1 Urticarial plaques, bullae and erosions of pemphigoid (bullous pemphigoid)

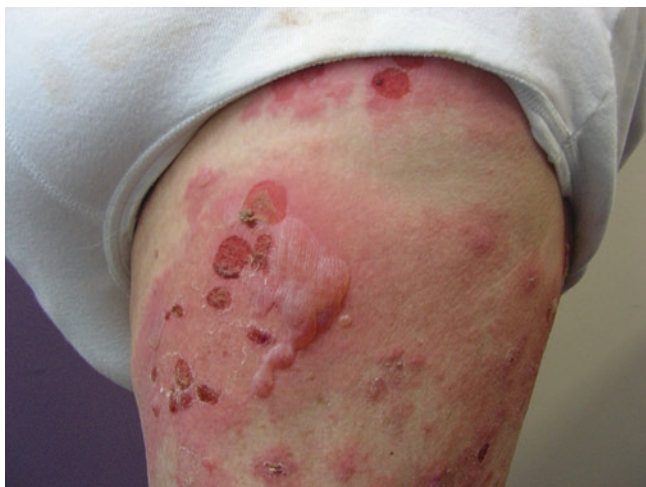

Fig. 41.2 Tense bullae and erosions of pemphigoid

detected by indirect immunofluorescence in both pemphigoid and pemphigus vulgaris. Baseline investigations are important for monitoring of systemic treatment.

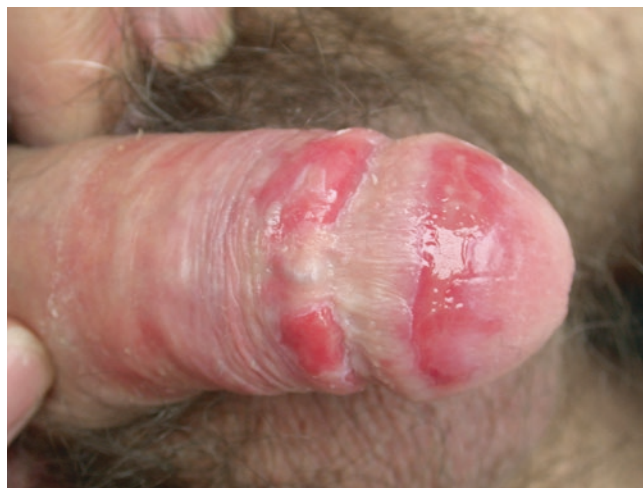

Fig. 41.3 Erosions of the glans and mucosal aspect of the foreskin due to pemphigoid confined to genitalia

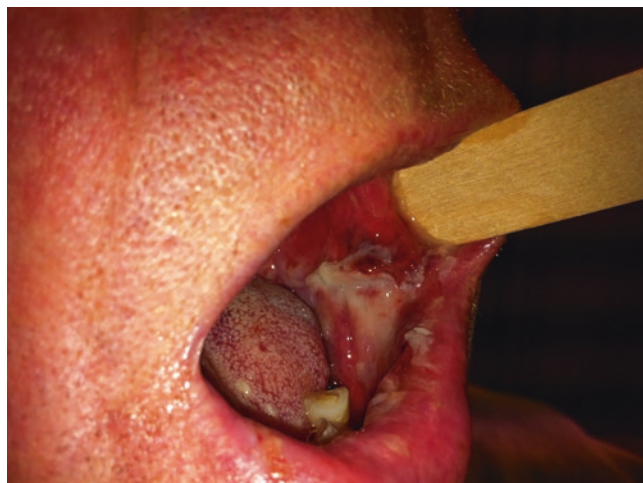

Fig. 41.4 Erosions of the oral mucosa due to pemphigus vulgaris

41.5 Treatment

Pemphigoid confined to genitalia usually responds to the application of a potent topical corticosteroid, whereas more widespread pemphigoid requires immunosuppressive treatment with an oral corticosteroid (prednisone or prednisolone). Steroid-sparing agents such as oral methotrexate may be necessary.

Pemphigus vulgaris presenting initially as solely genital disease usually requires systemic treatment, similar to pemphigus vulgaris at other sites. Treatment usually requires oral corticosteroids and a steroid-sparing agent such as azathioprine.

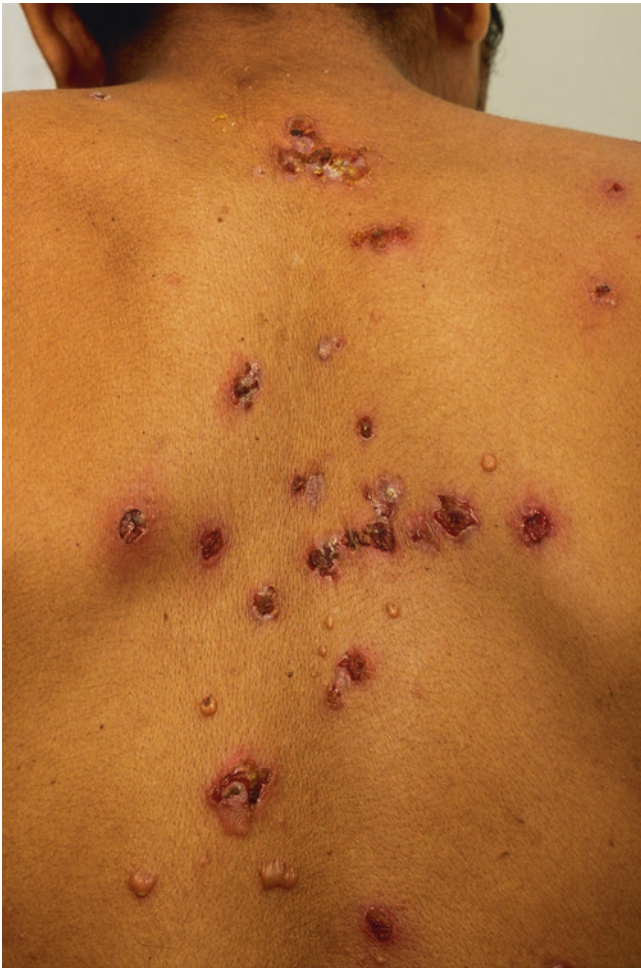

Fig. 41.5 Vesicles and erosions on the back of a patient with pemphigus vulgaris

Pearls

- Consider pemphigoid and pemphigus vulgaris for any male patient with erosive genital disease.
- In patients with erosive genital disease, exclude mucosal disease at other sites.

42.1 Definition

Aphthous ulcers (aphthae, canker sores) are common, acute, painful, non-infectious ulcers of oral mucosa that are usually recurrent. Complex aphthosis (recurrent aphthous ulceration, recurrent aphthous stomatitis) is characterized by oral or genital ulcers appearing synchronously, which may be associated with underlying systemic disease. Complex aphthosis (recurrent aphthous ulceration) needs to be distinguished from Behçet's disease and may represent an incomplete form (*forme fruste*) of Behçet's disease. Behçet's disease is a chronic autoinflammatory multisystem disease of unknown aetiology that is characterized by recurrent oral and genital ulceration involving mostly ocular, cutaneous, gastrointestinal, joint and neurological systems.

42.2 Aetiology

The aetiology of aphthous ulcers is unknown. Complex aphthosis (recurrent aphthous ulceration) is associated with deficiencies in vitamins (B1, B2, B6, B12) and deficiencies in folate, iron and zinc that are associated with some diseases (cyclic neutropenia, agranulocytosis, inflammatory bowel disease, systemic lupus erythematosus, Sweet's syndrome, HIV infection), allergies (foods, food dyes, preservatives) and medications (eg, NSAIDs). Behçet's disease is probably an autoinflammatory disease, the result of genetic factors, inflammatory mediators, infectious agents and immune dysregulation [1]. Behçet's disease has the highest prevalence along the old Silk Road from Japan though to the Mediterranean. The prevalence of Behçet's disease in North America and northern Europe is much less. Behçet's disease is rare in Africa. People who are HLA-B51 positive have increased risk for Behçet's disease. Infectious agents implicated as triggers for Behçet's disease include herpes simplex virus (HSV) and *Streptococcus* species. Immune-mediated vasculitic lesions and neutrophilic infiltration are seen in Behçet's disease.

42.3 Clinical Features

Aphthous ulcers are the most common cause of recurrent painful oral ulceration (recurrent aphthous ulceration or stomatitis), affecting at least 20% of the population [2]. More than 90% of aphthous ulcers are minor (less than 10 mm diameter) with a well-defined, erythematous border and covered with yellow to grey pseudomembrane. Minor aphthous ulcers occur mostly in younger people under 30 years of age. Most minor aphthous ulcers resolve spontaneously within 7–10 days. Major aphthous ulcers are 1–3 cm in diameter, take up to 6 weeks to heal, and may heal with scarring. Herpetiform aphthous ulcers are smaller (1–3 mm diameter), multiple, shallow ulcers that heal spontaneously within 7 days and are the least common form of aphthae.

Behçet's disease affects both sexes, with the peak age of onset between 20 and 30 years. Recurrent oral aphthous and genital ulceration are cardinal features of Behçet's disease. Oral ulceration is the commonest presenting symptom (Fig. 42.1). Recurrent genital ulceration occurs less frequently, takes longer to heal, and may result in scarring. Genital ulceration is usually painful. The commonest site for male genital ulceration is the scrotum (Figs. 42.2 and 42.3). Perianal, perineal, and inguinal ulceration is also seen. Cutaneous papulo-pustular lesions (pseudofolliculitis or acne-like lesions) occur on the trunk. Lesions resembling erythema nodosum appear on the lower legs. Subcutaneous thrombophlebitis and vasculitic lesions ("palpable purpura") are also seen. Vasculitic lesions may mimic Sweet's syndrome or pyoderma gangrenosum. It is important to exclude ocular, neurological, joint, gastrointestinal and deeper vascular involvement.

42.4 Diagnosis

Aphthous ulcers and Behçet's disease are diagnosed clinically. Behçet's disease is diagnosed on clinical criteria, as there is no diagnostic test or specific histologic features.

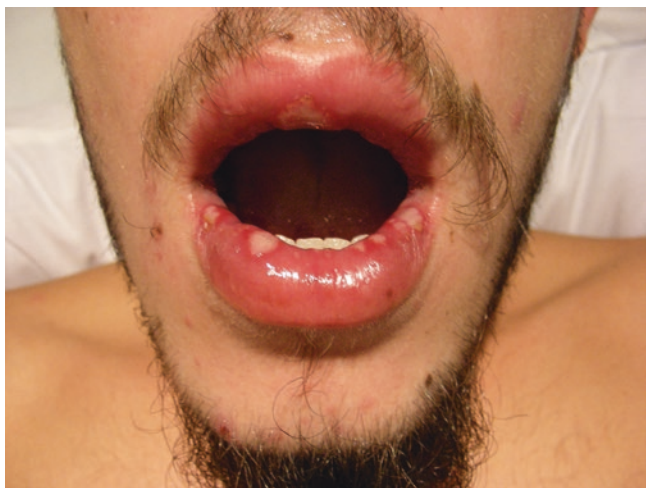

Fig. 42.1 Oral aphthous ulceration of Behçet's disease

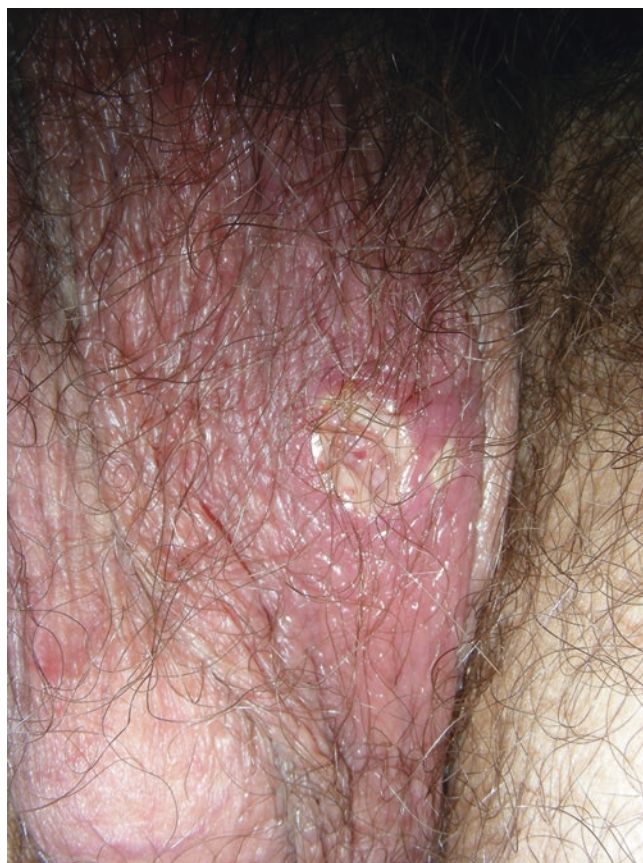

Fig. 42.3 Scrotal ulcer of Behçet's disease

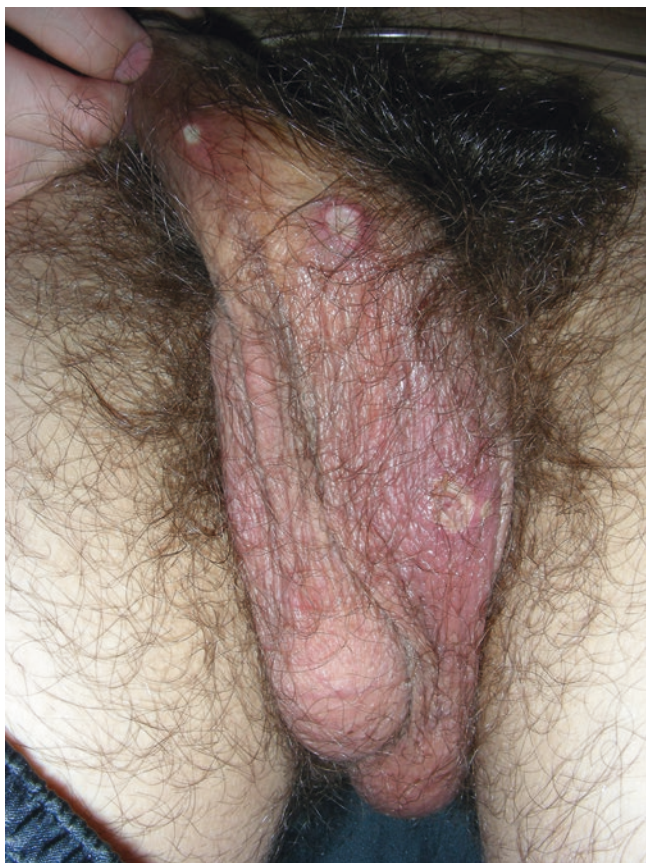

Fig. 42.2 Typical genital ulcers of Behçet's disease on the scrotum and penile shaft

The International Study Group diagnostic criteria for Behçet's disease require at least three episodes of oral ulceration over a 12-month period, with two of the following: recurrent genital ulceration (with genital scarring), ocular lesions (anterior uveitis, posterior uveitis, retinal

vasculitis), cutaneous lesions (pseudofolliculitis or papulopustular lesions, erythema nodosum-like lesions) and a positive pathergy test. A pathergy test is positive if a sterile pustule is produced 24–48 h after cutaneous trauma by a 20–26 G needle inserted at a 45-degree angle at four to six sites on the volar aspect of the forearm; the test is read by a physician. (The pathergy test is not likely to be positive in patients from North America and northern Europe). Vascular involvement (superficial phlebitis, deep vein thrombosis, large vein thrombosis, arterial thrombosis, and aneurysm) is commonly seen. Herpes simplex virus (HSV) infection, inflammatory bowel disease, systemic lupus erythematosus and reactive arthritis need to be excluded to make a diagnosis of Behçet's disease.

42.5 Treatment

Common oral aphthae are treated symptomatically with oral chlorhexidine washes, topical local anesthetic gel, oral tetracycline mouth rinses or potent topical corticosteroids (US Group I or II). As smoking appears to be protective for oral aphthae, chewing nicotine gum is beneficial for some patients.

Morbidity from Behçet's disease is high, but mortality is low. The aims in treating patients with Behçet's disease are to induce a remission, prevent irreversible tissue damage and improve quality of life. Treatment needs to be individualized depending on the patient, the severity of disease and organ involvement. A multidisciplinary approach is necessary to manage patients with systemic disease. Patients need reassurance that Behçet's disease is not a sexually transmissible infection (STI), as most patients have been treated for an STI despite negative testing. Management includes treatment with oral chlorhexidine washes, oral tetracycline mouth rinses or potent topical corticosteroids. If topical corticosteroids fail to improve oral or genital ulceration, intralesional corticosteroid injections, oral colchicine or oral dapsone may be tried. Short courses of oral corticosteroids should be reserved for resistant ulceration. If mucocutaneous disease is severe, treatments include methotrexate and thalidomide. For ocular and systemic organ involvement, treatments include immunosuppressives (oral or pulsed corticosteroid therapy, azathioprine, tacrolimus, chlorambucil), anticoagulants for major vessel thrombotic events and biologic treatments (targeted therapy). Biologic treatments including

tumour necrosis factor alpha antagonists (infliximab, adalimumab) and interleukin-1 inhibitors are effective and are being used more often.

Pearls

- Not all genital ulceration is due to genital herpes.
- Aphthous ulceration and Behçet's disease are important causes of non-infectious genital ulceration.
- Morbidity from Behçet's disease is high. Patients with Behçet's disease need a multidisciplinary treatment approach.

References

1. Gbate JV, Jorizzo J. Behçet's disease and complex aphthosis. *J Amer Acad Dermatol*. 1999;40:1–20.
2. Rogers RS 3rd. Recurrent aphthous stomatitis: clinical characteristics and associated systemic disorders. *Semin Cutan Med Surg*. 1997;16:278–83.

43.1 Definition

Reactive arthritis is a multisystem disease characterised by non-infectious urethritis, arthritis, and conjunctivitis (the classic triad of reactive arthritis) with cutaneous involvement. Reactive arthritis was previously termed *Reiter's disease* or *Reiter syndrome*.

43.2 Aetiology

Reactive arthritis is probably an autoimmune disease with a genetic predisposition triggered by various infectious agents. Human leukocyte antigen B27 (HLA-B27) positivity is seen in 75% of patients with reactive arthritis and is associated with a worse prognosis. HLA-B27 positivity is also associated with seronegative spondylarthropathies [1], including ankylosing spondylitis and psoriatic arthritis. Reactive arthritis is considered a disorder related to psoriasis [2]. Triggering infections for reactive arthritis include gastrointestinal infections (*Shigella*, *Salmonella*, and *Campylobacter*) and genitourinary infections, especially *Chlamydia trachomatis*. Reactive arthritis is more severe in HIV-positive patients.

43.3 Clinical Features

Most patients are young men, with peak onset at 20–30 years of age. The onset of reactive arthritis usually occurs within 1 month of the triggering infection. Patients may recall gastrointestinal symptoms (abdominal pain, diarrhea) or genitourinary symptoms (dysuria, frequency, penile discharge) that were followed by the early symptoms of reactive arthritis, including fever, malaise and fatigue. Only one third of patients show the classic triad of urethritis, arthritis, and conjunctivitis at initial presentation.

Genital skin involvement occurs in one third of patients. Erosions or ulceration may occur on the glans penis if the

man is uncircumcised. A moist, scaly psoriasiform plaque with a circinate or gyrate edge (*circinate balanitis*) is seen in circumcised and uncircumcised males (Fig. 43.1). The scaly psoriasiform plaque on the glans of uncircumcised males (*circinate balanitis*) may harden, crust, become painful, or even scar. Less severe psoriasiform changes may occur on the penile shaft or scrotum.

Cutaneous features similar to pustular psoriasis are seen in one third of patients, including vesicles, papules and pustules on the plantar surfaces of feet. Painful keratotic papules may resemble “hobnails” on boots (*punctate keratoderma* or *keratoderma blenorrhagicum*) (Fig. 43.2). Keratotic plantar papules may coalesce into a keratotic plaque on plantar surfaces (*diffuse keratoderma*). Less severe psoriasiform changes may be noted on the palms, scrotum, trunk or scalp. Psoriatic nail dystrophy (thickening of nail plates or total nail dystrophy) is common.

As reactive arthritis is a sero-negative spondyloarthritis, inflammatory back pain may dominate the clinical presentation. Sometimes only a few joints may be inflamed. Joint aches or pains may be migratory [1].

43.4 Diagnosis

Reactive arthritis is a clinical diagnosis with no diagnostic test. Cutaneous features of reactive arthritis are similar to pustular psoriasis. The differential diagnosis of cutaneous features of reactive arthritis includes psoriasis, dermatitis, cutaneous drug reaction, sarcoidosis and cutaneous T-cell lymphoma. The differential diagnosis of circinate balanitis includes psoriasis, lichen planus, plasma cell (Zoon's) balanitis, penile intraepithelial neoplasia (PIN) (*in situ* squamous cell carcinoma) or early invasive squamous cell carcinoma. Baseline investigations include complete blood count, erythrocyte sedimentation rate, C-reactive protein (CRP) and urinalysis. Useful investigations to detect underlying diseases include serology and culture of urine, urethra, blood and stool for *Chlamydia*, antistreptolysin O titre (ASOT),

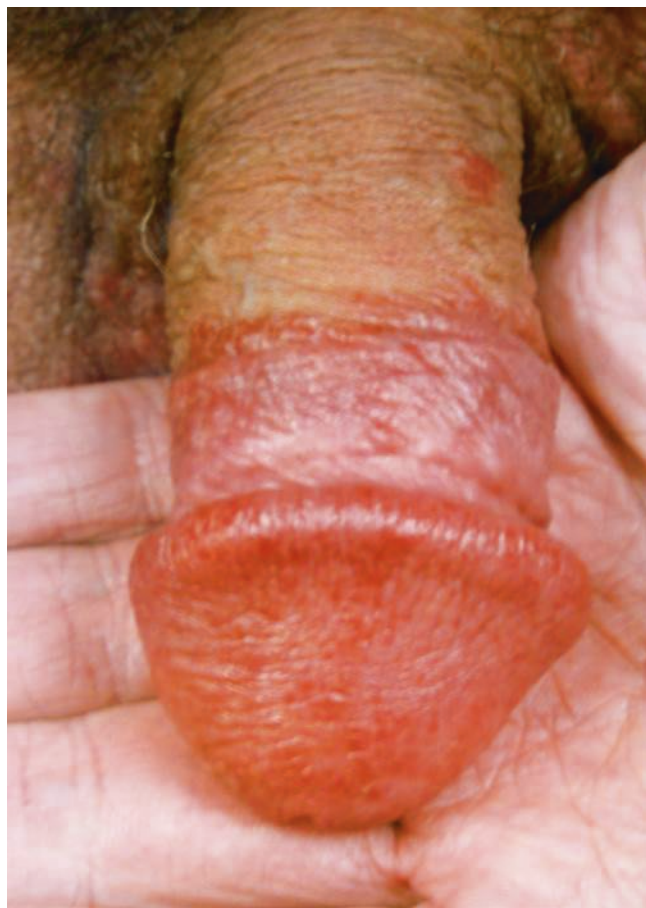

Fig. 43.1 Psoriasiform erythema of the glans penis (circinate balanitis) with reactive arthritis

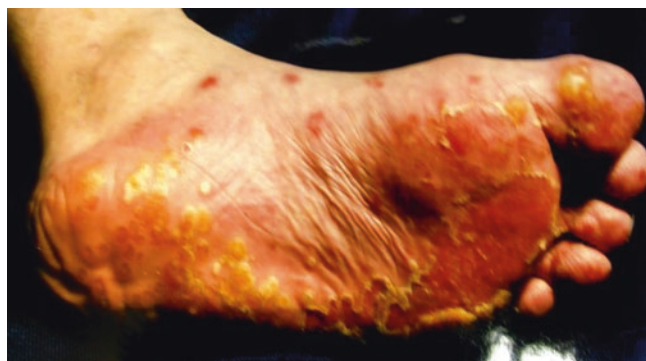

Fig. 43.2 Keratoderma of reactive arthritis (keratoderma blenorrhagicum)

anti-DNase B testing, HIV antibodies, tuberculosis screening with a tuberculin skin test or the interferon-gamma release assay test (QuantiFERON-TB Gold test) and, HLA-B27 testing. Radiographic examination of symptom-

atic joints (plain radiographs, computerised tomography (CT) or magnetic resonance imaging (MRI) is important. Arthrocentesis for synovial fluid examination is necessary for symptomatic joints. Skin biopsy may be necessary to exclude penile intra-epithelial neoplasia (PIN) (*in situ* squamous cell carcinoma) or early invasive squamous cell carcinoma. Circinate balanitis has identical histology to psoriasis.

43.5 Treatment

No specific cure exists for reactive arthritis. Reactive arthritis follows a variable course but usually resolves within 12 months. Relapses may occur, and some patients develop chronic joint disease. Treatment is aimed at controlling symptoms and improving or maintaining functional activity. Analgesics, NSAIDs, intralesional corticosteroids, low-dose oral corticosteroids and disease-modifying antirheumatic drugs (DMARDs) combined with physiotherapy are useful. Involvement of relevant specialty colleagues (infectious disease, ophthalmology, rheumatology, gastroenterology, cardiology, physiotherapy, rehabilitation specialists) is important. Treatment of cutaneous disease is the same as for cutaneous psoriasis, with topical corticosteroids, topical keratolytics (salicylic acid), vitamin D analogues (calcipotriol), topical calcineurin inhibitors or systemic treatment with oral acitretin or methotrexate.

Pearls

- Reactive arthritis is characterised by urethritis, arthritis, conjunctivitis, and psoriasiform skin features.
- Reactive arthritis is probably a variant of psoriasis with features of cutaneous psoriasis and psoriatic arthropathy.
- Consider HIV infection if reactive arthritis is severe, especially if the patient is positive for HLA-B27.

References

1. Selmi C, Gershwin ME. Diagnosis and classification of reactive arthritis. *Autoimmun Rev*. 2014;13(4-5):546–9.
2. Stavropoulos PG, Soura E, Kanelleas A, Katsambas A, Antoniou C. Reactive arthritis. *J Eur Acad Dermatol Venereol*. 2015;29(3):415–24.

44.1 Definition

Genital trauma includes the result of various forces (mechanical, thermal, friction, pressure, suction), penetrating injuries, insertion of foreign materials, or iatrogenic trauma from surgery or radiation treatment. Artefactual disease (*dermatitis artefacta*, *dermatitis factitia*, *factitious disorder*) is self-induced trauma.

44.2 Aetiology

External male genitalia are prone to trauma. Uncircumcised males are more prone to trauma, as uncircumcised boys may catch their foreskin in zip fasteners. Genital trauma may result from mechanical injury (Fig. 44.1), thermal burn (Fig. 44.2), chemical burn (Fig. 44.3), friction, pressure, suction, penetrating injuries or injection of foreign materials (Fig. 44.4) [1, 2]. Penile “fracture” (penile rupture) occurs with strenuous sexual activity or falling when the penis is erect. Superficial dorsal penile vein thrombosis (penile Mondor’s disease, superficial thrombophlebitis) is triggered by vigorous or prolonged sexual activity but does not usually result in permanent injury. Studs, rings, and other jewellery are inserted for adornment (Fig. 44.3). Foreign substances injected into the penile shaft for penile enlargement include paraffin, oils, and silicone (Fig. 44.4). Constriction bands around the penile shaft or self-instrumentation of the urethra are used for autoeroticism. Tattooing with injected dyes is for adornment. Beads, smooth stones, or pearls are injected subdermally into the penile shaft for increased sexual arousal in parts of southeastern Asia. The genitals are a common site for self-injection of narcotics and other analgesics. Autoerotic behaviour or sexual experimentation may result in genital trauma, such as suction blisters or purpura from a vacuum cleaner. Genital trauma or mutilation in the form of mechanical trauma or thermal burns may be a result of sexual abuse or torture. Iatrogenic trauma may occur from surgery (circumcision), drugs injected for erectile dysfunction, insertion

of dermal fillers, surgical insertion of erectile implants and electrical or thermal (laser) injury. Genital self-mutilation resulting in artefactual disease is self-induced trauma associated with significant psychopathology, including anxiety, depression or major psychosis [3].

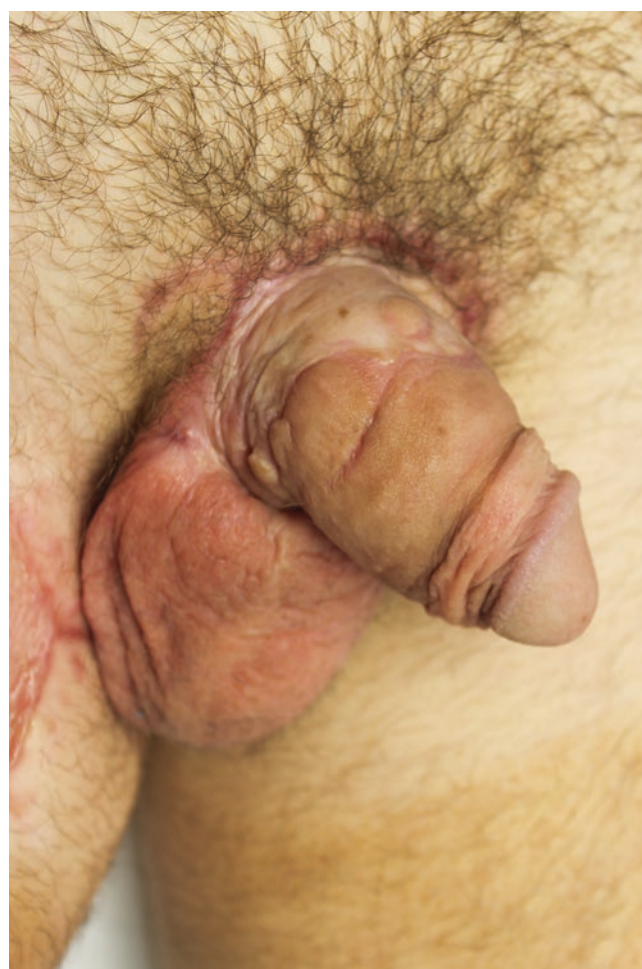

Fig. 44.1 Severe genital mechanical trauma with scarring following surgical skin grafting

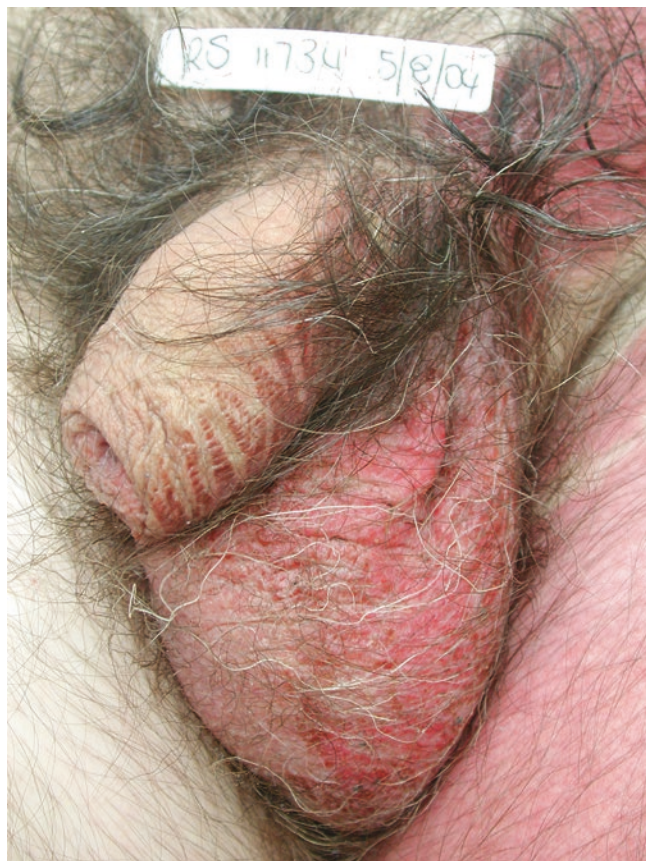

Fig. 44.2 Thermal burn with hot water of scrotum, penis, and adjacent inner thigh

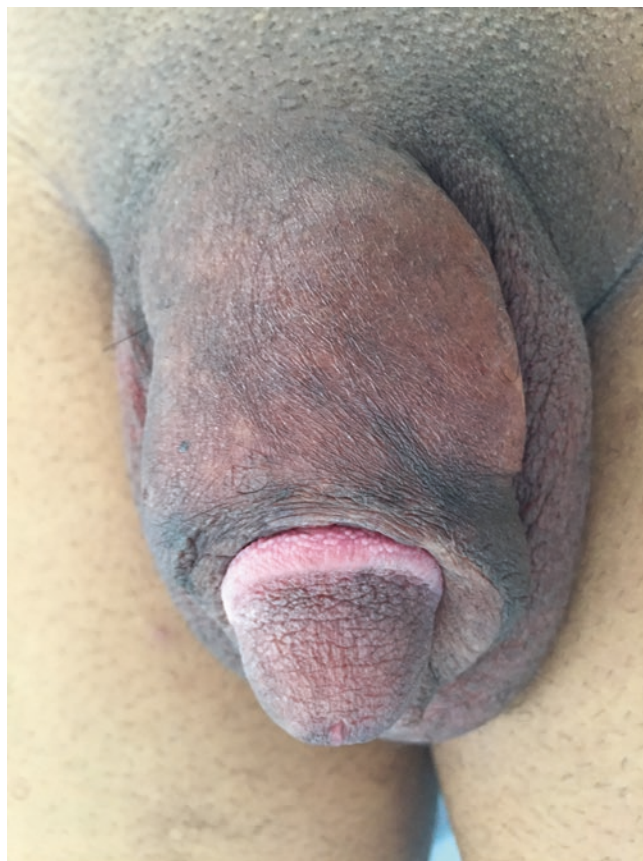

Fig. 44.4 Injected foreign material for penis enlargement

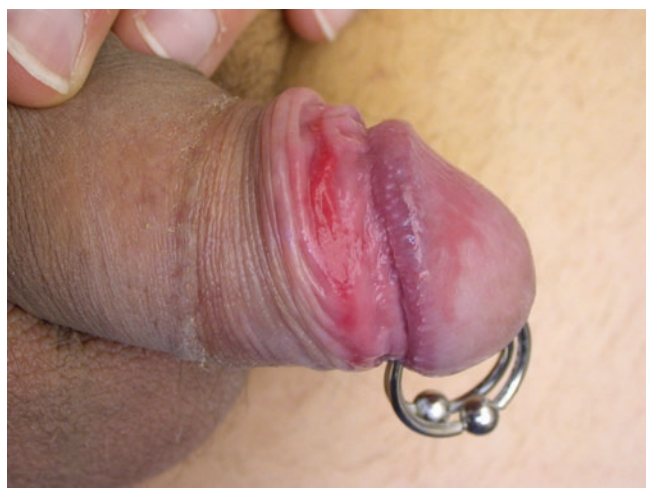

Fig. 44.3 Chemical burn with metallic foreign body through urethral meatus

44.3 Clinical Features

History taking may give an insight as to whether the genital trauma is accidental or intentional. It is important to attempt to understand each patient's social and cultural environment to determine if the behaviour is consistent with his society or

culture. Identify patients with cognitive or intellectual impairment, significant psychological or psychiatric issues (anxiety, depression, personality disorders, major psychosis) and patients with addiction issues (illicit drugs). A patient may give a clear history of trauma in which the cause is readily identified, or he may be guarded and evasive. Male patients are reluctant to admit self-injecting foreign substances, particularly if used for penile enlargement. Abused or tortured patients may be reluctant to offer any explanation for their genital injury. Patients presenting with dermatitis artefacta often give a "hollow history" with little detail indicating the cause of their genital disease or injury. Clinical signs depend on the cause of trauma or disease. Mechanical, chemical, thermal, suction or surgical trauma may result in erosions, bruising, inflammation (dermatitis), ulceration or scarring. Injected foreign substances result in swelling (edema), nodules, deformity, phimosis, dyspareunia, erectile dysfunction, infection, discharging sinus tracts, scarring or necrosis.

44.4 Diagnosis

Diagnosis of genital trauma is clinically based, requiring a thorough history and examination. Diagnostic investigations include skin swabs for microbiological examination if infection

is suspected. Skin biopsy is helpful if paraffinoma is suspected (sclerosing granuloma of male genitalia). Histological examination of any resected tissue at surgical exploration might confirm self-injecting of a foreign substance. Ultrasonography or magnetic resonance imaging (MRI) may be useful if the cause of penile swelling, edema, or deformity is unclear. Sometimes the cause is identified only at surgical exploration.

44.5 Treatment

Management includes removal or avoidance of any obvious causative agent, treatment of any local wounds and restoration of normal function. It is important to attempt to maintain normal appearance and prevent future trauma. Patients with dermatitis artefacta often need psychological or psychiatric help. Patients who self-mutilate their genitalia (including auto-amputation) need emergency surgical care and ongoing intensive psychological and psychiatric help [3].

Pearls

- Males who self-inject foreign material into their own genitalia often hide their behaviour.
- Patients with dermatitis artefacta usually provide little detail indicating the cause.
- Patients who genitally self-mutilate need emergency psychological or psychiatric care.

References

1. Furr J, Culkin D. Injury to the male external genitalia: a comprehensive review. *Int Urol Nephrol*. 2017;49:553–6.
2. Ahmed U, Freeman A, Kirkham A, Ralph DJ, Minhas S, Muneer A. Self injection of foreign materials into the penis. *Ann R Coll Surg Engl*. 2017;99:e78–82.
3. Veeder TA, Leo RJ. Male genital self-mutilation: a systematic review of psychiatric disorders and psychosocial factors. *Gen Hosp Psychiatry*. 2017;44:43–50.

45.1 Definition

Melanocytic nevi (naevi) are congenital or acquired collections of benign melanocytes (melanocytic nevus cells) in the skin. Variants include congenital, acquired, junctional, compound, intradermal, blue and atypical nevi (*dysplastic nevus* or *Clark's nevus*).

45.2 Aetiology

Both genetic and environmental factors (especially ultraviolet light) are important in the development of most benign melanocytic nevi, but ultraviolet light is not a factor in genital nevi. Somatic mutations have been detected in benign genital melanocytic nevi, similar to mutations in genital melanoma [1].

45.3 Clinical Features

Melanocytic nevi are common in fairer-skinned people. Melanocytic nevi may be congenital or acquired and may occur at any anatomical site. Congenital melanocytic nevi are classified by diameter into small (<1.5 cm), medium-sized (1.5–20 cm), or large (>20 cm). Congenital melanocytic nevi are usually more darkly pigmented at birth, appearing as tan, dark brown, or black macules, papules, patches, or plaques. More than one colour may be seen within a congenital melanocytic nevus. Pigmented terminal hairs may grow from a congenital melanocytic nevus. Large or giant congenital melanocytic nevi (“bathing trunk nevi”) may involve the genital region. Congenital melanocytic nevi may be associated with neurocutaneous melanosis.

Acquired melanocytic nevi are classified clinically and histologically into junctional (Figs. 45.1 and 45.2), compound, intradermal and atypical types (Clark's or dysplastic nevus) (Fig. 45.3). Acquired nevi may be skin-coloured (most intradermal nevi), light brown, tan, dark brown, black

or blue macules or papules with a sharply defined border. Most acquired melanocytic nevi are less than 6 mm in diameter. Terminal hairs may grow out from compound and

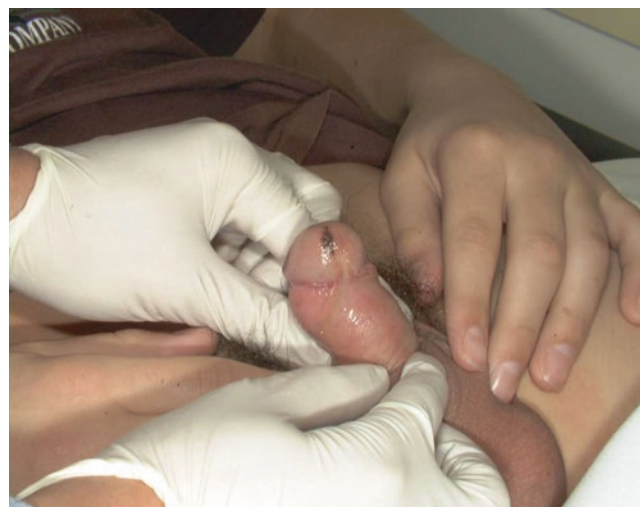

Fig. 45.1 Junctional melanocytic nevus on glans penis of a 13-year-old boy

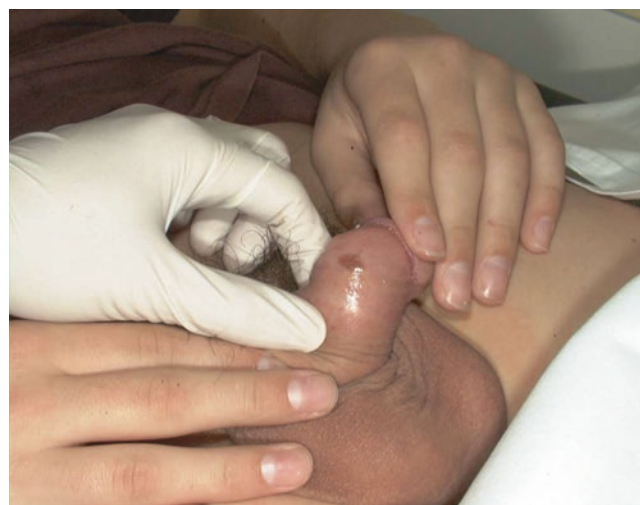

Fig. 45.2 Junctional melanocytic nevus on shaft of penis of same 13-year-old boy

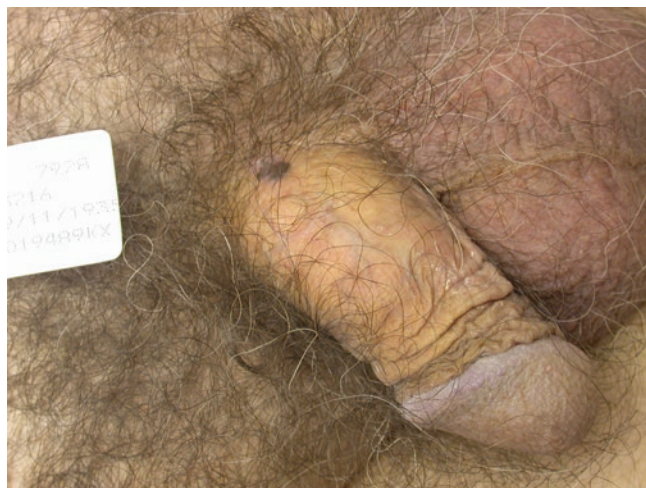

Fig. 45.3 Mildly dysplastic melanocytic nevus at base of penile shaft of an adult male

intradermal nevi. Most acquired melanocytic nevi on male genitalia are junctional or compound melanocytic nevi.

45.4 Diagnosis

Benign melanocytic nevi need to be differentiated from melanoma. History determines whether a melanocytic nevus is congenital or acquired. A history of change in a pigmented lesion is very important. Changes in a pigmented lesion suggestive of malignant change include darkening, enlargement or development of an irregular border. These changes may indicate that a melanoma was originally wrongly misdiagnosed as a benign nevus. Clinical diagnosis is aided by dermoscopic examination (dermatoscopy or epiluminescent microscopy). Differentiation of benign melanocytic nevi from other pigmented lesions (lentigines, genital melanotic macules, post-inflammatory hyperpigmentation and melanoma) is very important. There is no evidence that melanocytic nevi of genital skin have a greater risk of malignant transformation than those in other anatomical sites. Clinical photography is useful to monitor melanocytic nevi. Where doubt exists about the diagnosis, skin biopsy for histologic examination is essential. Excision biopsy and shave biopsy are the preferred meth-

ods for genital biopsy, but if a melanocytic nevus is located on the glans, punch biopsy may be chosen [2].

45.5 Treatment

Treatment of congenital melanocytic nevi is complicated and controversial. Small congenital melanocytic nevi do not need removal, but clinical photography with annual long-term follow-up is wise. Medium-sized congenital melanocytic nevi may not be associated with an increased risk for melanoma. Clinical photography with annual follow-up is necessary. Large congenital melanocytic nevi are associated with increased lifelong risk of melanoma. Removal of large congenital melanocytic nevi is complicated by the age of the patient (often a child), anesthetic and surgical risks and the cosmetic result of surgery. Management decisions must be individualised for each patient. If diagnosis of a benign acquired melanocytic nevus is confidently made, reassurance and observation are only necessary. If there is diagnostic uncertainty or raised patient concern, it is justifiable to remove the melanocytic nevus by surgical excision with a narrow (2–3 mm) margin.

Pearls

- Management of a congenital melanocytic nevus must be individualized for each patient.
- Differentiation of melanocytic nevus from melanoma is essential. If there is clinical suspicion of melanoma, don't delay in taking a skin biopsy.

References

1. Tseng D, Kim J, Warrick A, Nelson D, Pukay M, Beadling C, et al. Oncogenic mutations in melanomas and benign melanocytic nevi of the female genital tract. *J Am Acad Dermatol.* 2014;71:229–36.
2. Primus G, Soyer HP, Smolle J, Mertl G, Pummer K, Kerl H. Early 'invasive' malignant melanoma of the glans penis and the male urethra. Report of a case and review of the literature. *Eur Urol.* 1990;18:156–9.

Genital Melanotic Macules and Genital Lentiginosis

46

46.1 Definition

A *lentigo* (plural *lentigines*) is a well-defined brown to black macule with an increased number of benign melanocytes at the dermal-epidermal junction. Genital melanotic macules (genital lentiginosis, mucosal melanosis) are discrete, hyperpigmented macules or patches on genitalia with a normal number of melanocytes but increased basal hyperpigmentation.

46.2 Aetiology

Most simple or solar lentigines occur on fair-skinned individuals and are induced by ultraviolet (UV) light exposure. PUVA lentigines are associated with UVA exposure and occur on genitalia following PUVA treatment (photochemotherapy with use of a Psoralen followed by ultraviolet-A or UVA exposure). The aetiology of genital melanotic macules is unknown in most cases. Genital melanotic macules may occur in isolation, as a component of Laugier-Hunziker syndrome or as part of a variety of syndromes with multisystem abnormalities [1]. Genital lentiginosis may represent post-inflammatory hyperpigmentation following lichen planus [2] or lichen sclerosus [3]. Laugier-Hunziker syndrome is a benign acquired disorder of adulthood of unknown cause, characterized by hyperpigmentation of oral mucosa and fingernails (longitudinal melanonychia) with genital involvement where other pigmentary disorders are excluded [4, 5]. Multiple lentigines are associated with a variety of hereditary and acquired syndromes, some involving genital lentiginosis. These disorders include LEOPARD syndrome [6], Carney complex (including LAMB syndrome) [7], Bannayan-Riley-Ruvalcaba syndrome [8] and Peutz-Jeghers syndrome [9].

46.3 Clinical Features

Genital melanotic macules occur in both sexes beginning at an average age of 40 years. Genital melanotic macules are asymptomatic, solitary (50%) or multiple tan to dark brown or black macules on the external genitalia (Figs. 46.1, 46.2, 46.3, 46.4, and 46.5), which remain stable or slowly enlarge.

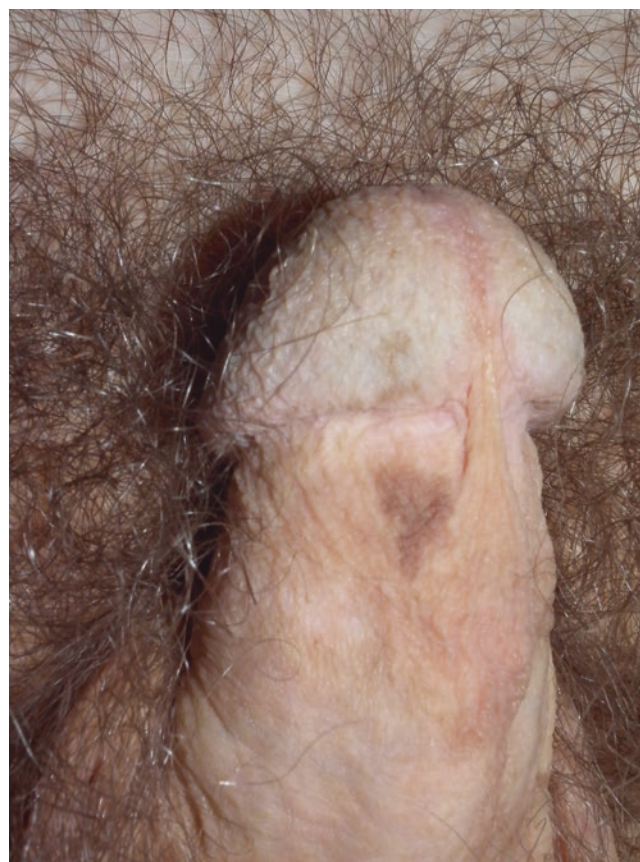

Fig. 46.1 Genital melanotic macule on ventral shaft of the penis

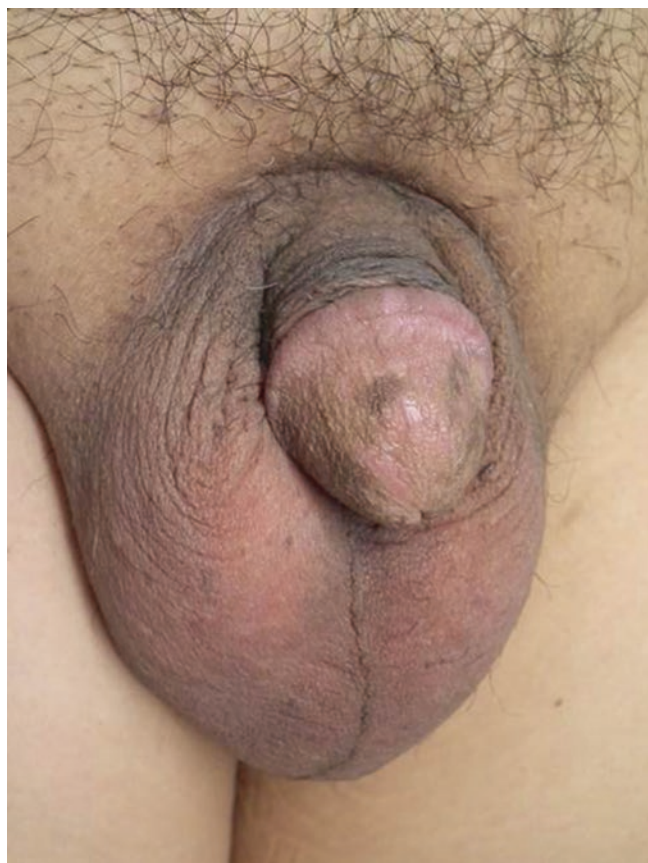

Fig. 46.2 Multiple genital melanotic macules on glans penis

Most genital melanotic macules occur on the glans [1]. Some lesions are larger, irregular patches with multifocal variable pigmentation involving the entire glans [10]. Many patients (and their physicians) are concerned about possible melanoma. Genital melanotic macules are clinically very similar to melanomas, particularly when extensive, irregular pigmented patches are seen on the glans. Full clinical examination is necessary to detect associated syndromes, including Laugier-Hunziker syndrome, Addison's disease, Peutz-Jeghers syndrome, LEOPARD syndrome, Carney complex and Bannayan-Riley-Ruvalcaba syndrome.

46.4 Diagnosis

Differentiation of a genital melanotic macule from melanoma can be very difficult but is most important. Clinical diagnosis may be aided by dermoscopy [11]. Biopsy is usually necessary to exclude melanoma. Shave or incisional biopsies are preferable to sample a larger genital melanotic macule.

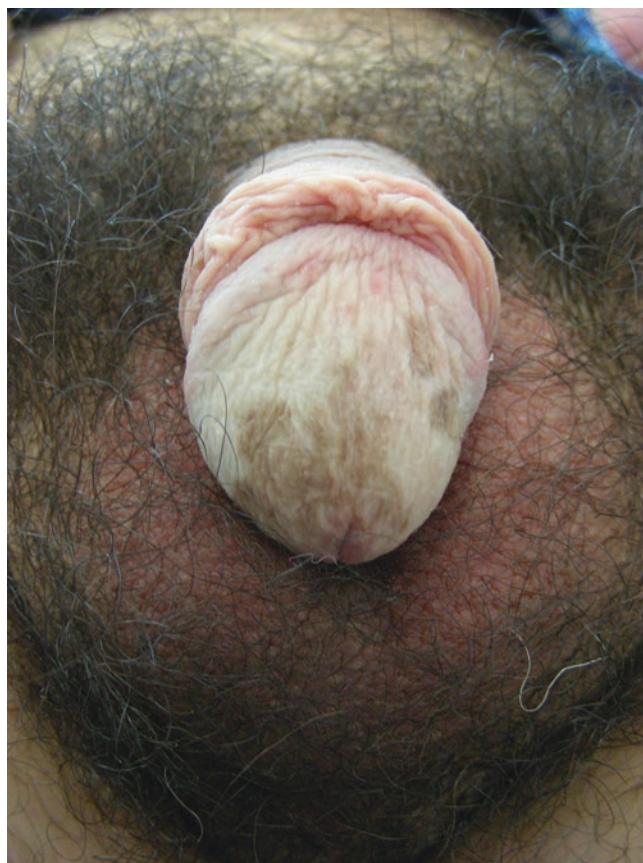

Fig. 46.3 Extensive genital melanotic macules on glans penis

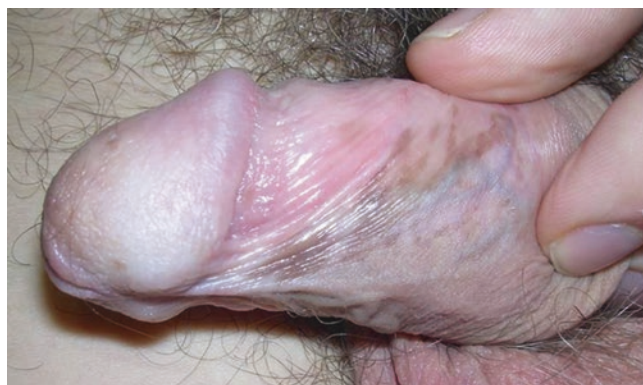

Fig. 46.4 Genital melanotic macules on mucosal aspect of the foreskin

Punch biopsy or local excision biopsy can adequately remove a smaller genital melanotic macule. Histopathology of genital melanotic macules shows an increase in melanin in basal keratinocytes with no marked (or only a minor) increase in melanocytes with no cytologic atypia.

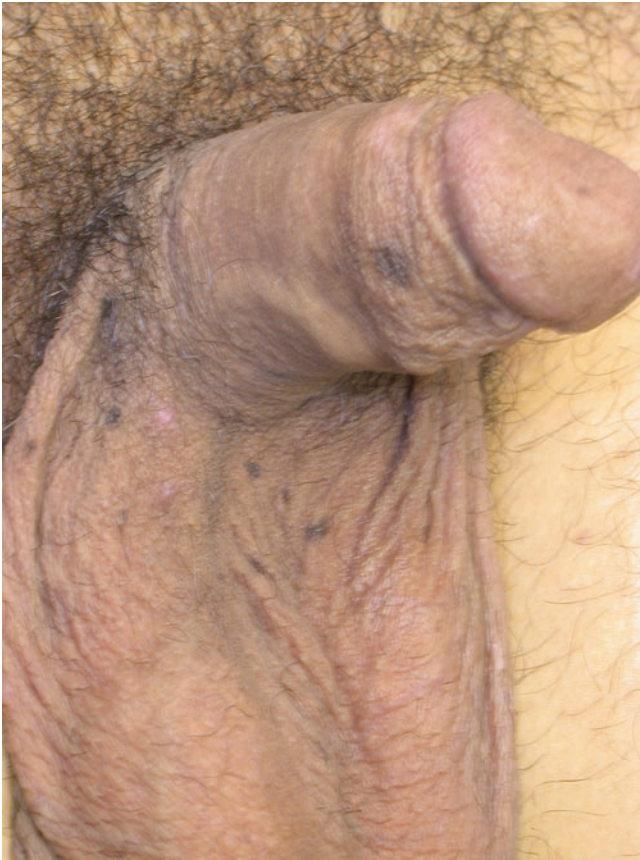

Fig. 46.5 Multiple genital melanotic macules on the scrotum and penis

46.5 Treatment

No treatment is necessary once the diagnosis has been con-

firmed histologically. Although a genital melanotic macule is not considered a premalignant lesion, long-term follow-up clinical photography is wise.

References

1. Lenane P, Keane CO, Connell BO, Loughlin SO, Powell FC. Genital melanotic macules: clinical, histologic, immunohistochemical, and ultrastructural features. *J Am Acad Dermatol.* 2000;42:640–4.
2. Isbary G, Dyall-Smith D, Coras-Stepanek B, Stolz W. Penile lentigo (genital mucosal macule) following annular lichen planus: a possible association? *Australas J Dermatol.* 2014;55:159–61.
3. El Shabrawi-Caelen L, Soyer HP, Schaeppi H, Cerroni L, Schirren CG, Rudolph C, et al. Genital lentigines and melanocytic nevi with superimposed lichen sclerosis: a diagnostic challenge. *J Am Acad Dermatol.* 2004;50:690–4.
4. Mahmood T, Menter A. The Laugier-Hunziker syndrome. *Proc (Bayl Univ Med Cent).* 2015;28:41–2.
5. Lalosevic J, Zivanovic D, Skiljevic D, Medenica L. Laugier-Hunziker syndrome - Case report. *An Bras Dermatol.* 2015;90:223–5.
6. Coppin BD, Temple IK. Multiple lentigines syndrome (LEOPARD syndrome or progressive cardiomyopathic lentiginosis). *J Med Genet.* 1997;34:582–6.
7. Correa R, Salpea P, Stratakis CA. Carney complex: an update. *Eur J Endocrinol.* 2015;173:M85–97.
8. Yehia L, Ni Y, Eng C. Germline *TTN* variants are enriched in *PTEN*-wildtype Bannayan-Riley-Ruvalcaba syndrome. *NPJ Genom Med.* 2017;2:37.
9. Beggs AD, Latchford AR, Vasen HF, Moslein G, Alonso A, Aretz S, et al. Peutz-Jeghers syndrome: a systematic review and recommendations for management. *Gut.* 2010;59:975–86.
10. Barnhill RL, Albert LS, Shama SK, Goldenhersh MA, Rhodes AR, Sober AJ. Genital lentiginosis: a clinical and histopathologic study. *J Am Acad Dermatol.* 1990;22:453–60.
11. Mannone F, De Giorgi V, Cattaneo A, Massi D, De Magnis A, Carli P. Dermoscopic features of mucosal melanosis. *Dermatol Surg.* 2004;30:1118–23.

Pearls

- Genital melanotic macule needs to be differentiated from melanoma.
- Clinical differentiation of a genital melanotic macule from melanoma can be very difficult. Biopsy all larger and irregular genital melanotic macules to exclude melanoma.

47.1 Definition

Seborrhoeic keratosis (plural *seborrhoeic keratoses*) is the commonest benign keratocytic tumour of hair-bearing skin of fair-skinned (skin photo-types 1–3) adults. Seborrhoeic keratoses occur on non-mucosal genital skin, mostly the penile shaft.

47.2 Aetiology

The aetiology of seborrhoeic keratoses is unknown but genetic and environmental factors have been implicated. Seborrhoeic keratoses are more common with increasing age. Somatic mutations have been associated. Some patients have a strong family history of seborrhoeic keratoses (familial form). Seborrhoeic keratoses are more common on exposed sites, suggesting sun exposure as a factor but seborrhoeic keratoses also occur on sun-protected sites. The role of human papillomavirus (HPV) is debated but HPV has been associated with some non-genital seborrhoeic keratoses. Friction may be a factor in genital seborrhoeic keratoses.

47.3 Clinical Features

Seborrhoeic keratoses are seen on people of all skin photo-types, mostly as a disease of middle age, increasing in number with age. Seborrhoeic keratoses occur on any hair-bearing skin site, sparing mucosae, palms, and soles. The most common sites include the chest, back, forehead (hairline), and waist. Seborrhoeic keratoses occur in the male genital region, including the groins and penile shaft but spare the glans. Contrary to the opinion of some, seborrhoeic keratoses are not rare on the male genitalia. Seborrhoeic keratoses are mostly asymptomatic, solitary, well-defined, flat, waxy-looking tumours that become more exophytic and multiple with increasing age. Seborrhoeic keratoses vary considerably in colour, from pink, yellow, light tan, dark brown to black

(Figs. 47.1, 47.2, and 47.3). Seborrhoeic keratoses are occasionally arranged in linear fashion beneath the breasts in women and groins in both sexes. Multiple genital seborrhoeic keratoses may be clinically identical to genital warts (condyloma acuminata) (Figs. 47.4, 47.5, and 47.6). Papules of bowenoid papulosis tend to be smoother, occurring on the mucosal aspect of the foreskin and the glans of uncircumcised

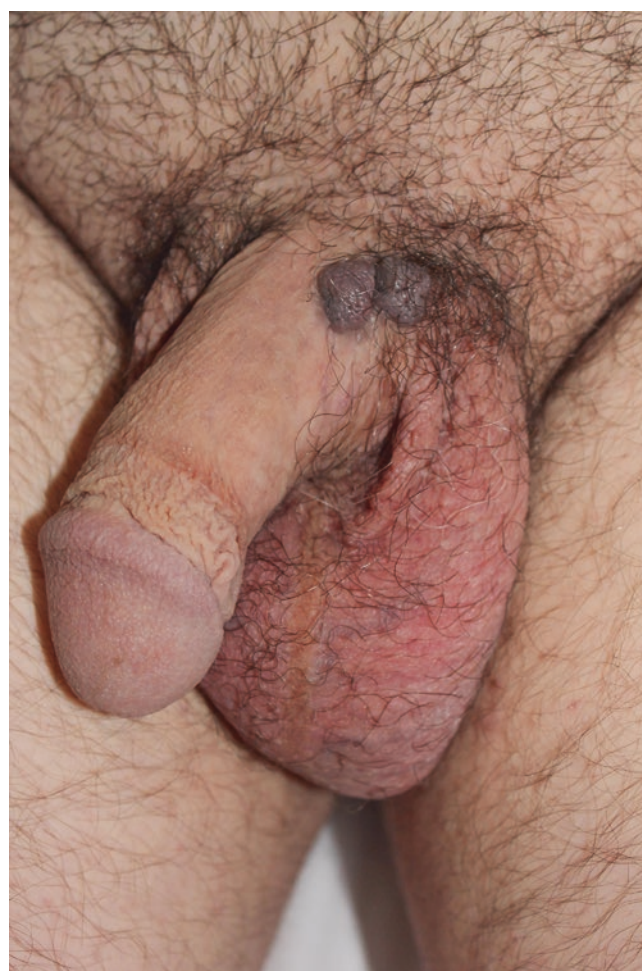

Fig. 47.1 Pigmented seborrhoeic keratoses at base of penile shaft

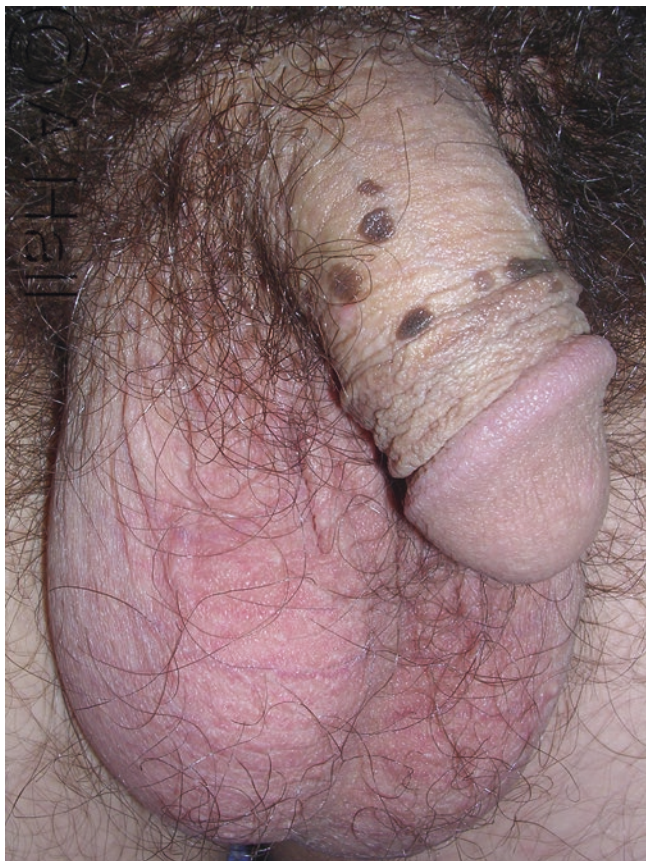

Fig. 47.2 Multiple pigmented seborrhoeic keratoses on penile shaft

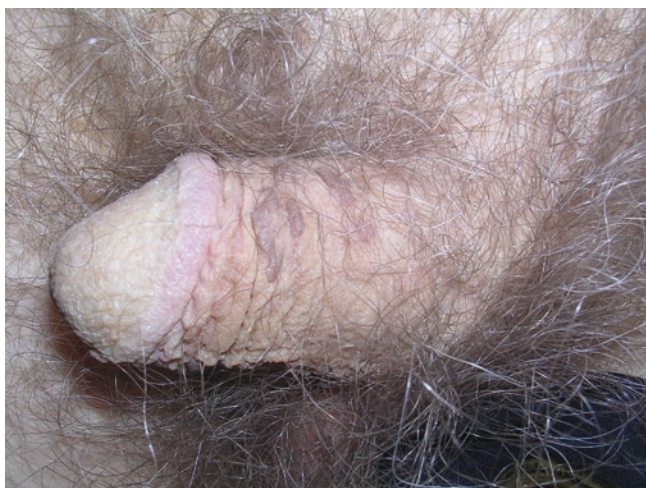

Fig. 47.3 Multiple pale verrucous seborrhoeic keratoses on penile shaft

males. Rarely, seborrhoeic keratoses can grow to considerable size and may be confused with Buscke-Lowenstein tumour [1]. Other variants of seborrhoeic keratoses include dermatosis papulosis nigra and stucco keratoses. Dermatitis papulosis nigra are small, pigmented papules on the face or chest of darker-skinned (skin of color) people. Stucco keratoses are

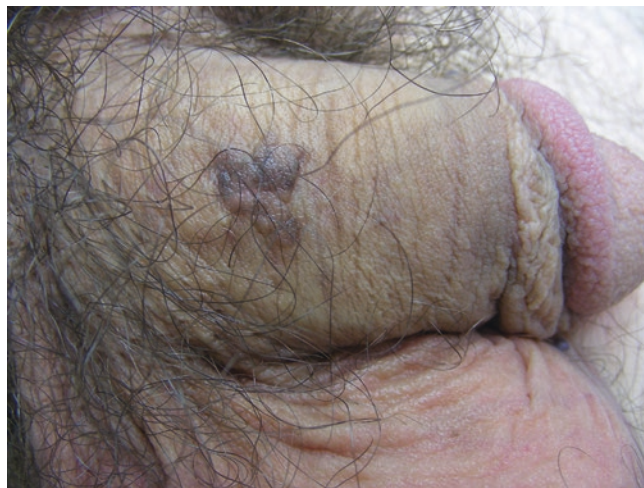

Fig. 47.4 Pigmented verrucous seborrhoeic keratosis on penile shaft

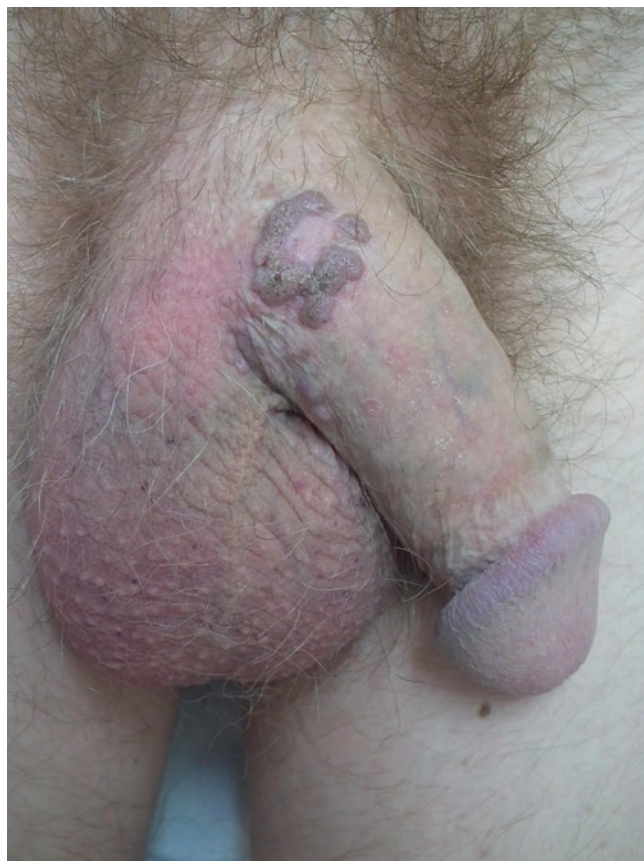

Fig. 47.5 Annular seborrhoeic keratosis treated for years as a genital wart

small, keratotic white papules around the ankles and feet of fairer-skinned (skin photo-types 1–3) people. Neither dermatosis papulosis nigra nor stucco keratoses are seen on male genitalia. The very rare variant of eruptive seborrhoeic keratoses on the trunk associated with internal cancers (sign of Leser-Trélat) is not reported occurring on male genitalia.

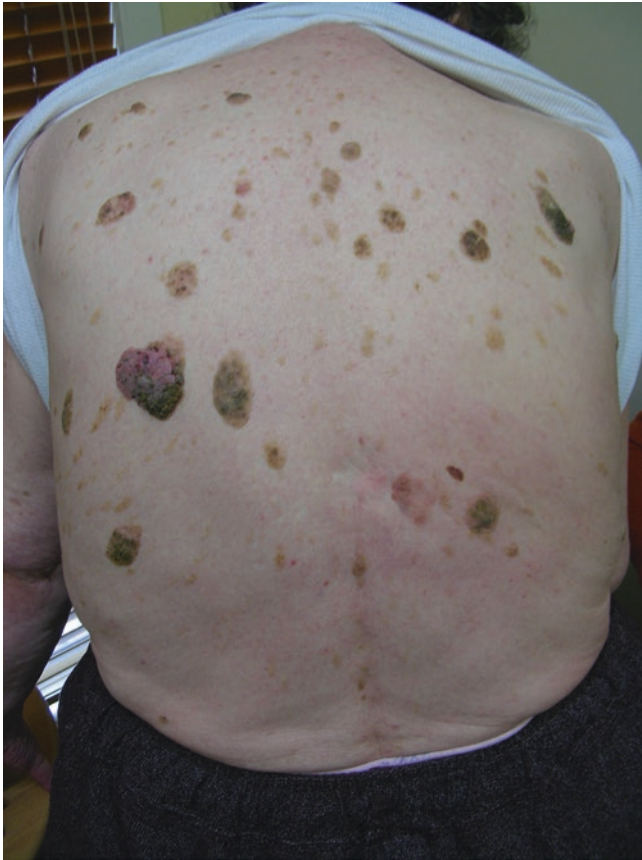

Fig. 47.6 Common appearance of multiple verrucous seborrheic keratosis on back

47.4 Diagnosis

Seborrheic keratoses are usually diagnosed clinically, but clinical diagnosis is not always easy. The differential diagnosis of genital seborrheic keratoses includes genital warts, melanocytic nevi, melanoma, bowenoid papulosis (penile intraepithelial neoplasia) and pigmented basal cell carcinoma. Multiple genital seborrheic keratoses are often wrongly diagnosed and incorrectly treated as genital warts. Rarely, seborrheic keratoses can grow to considerable size, so differentiation from Buscke-Lowenstein tumour may be difficult (1). Making a correct diagnosis is very important for management. Dermoscopic examination may aid clinical diagnosis to differentiate seborrheic keratosis from melanocytic nevus, melanoma, pigmented basal cell carcinoma and other pigmented lesions. Dermoscopic features of seborrheic keratosis include milia-like cysts (pseudo-horn cysts), comedo-like openings, brain coral appearance (“sulci and gyri” of cerebral cortex) and “moth-eaten” border. If clinical diagnosis of a genital seborrheic keratosis is difficult, biopsy for histological examination is necessary. Shave excision or curettage with a sharp, disposable curette are the preferred

biopsy techniques. Histologic features include a well-defined exophytic tumour with acanthosis consisting of a mixture of basaloid and squamous cells, papillomatosis, and hyperkeratosis with keratin-filled invaginations (pseudo-horn cysts).

47.5 Treatment

Treatment of a genital seborrheic keratosis usually is not necessary if the diagnosis is confidently made. Wrongly diagnosing genital seborrheic keratoses as a sexually transmissible infection (STI) creates guilt, emotional distress and has a negative impact on sexual quality of life. Reassurance that a genital seborrheic keratosis is not a sexually transmissible infection (STI) is enormously important. Male patients may carry long-term guilt and shame, with relationships damaged by a wrong diagnosis of an STI made years earlier. Verrucous seborrheic keratoses are best treated by shave excision or curettage with a sharp, disposable curette and minimal cautery under local anaesthesia. The wound base may need further treatment with a chemical hemostatic agent (*eg*, aluminium chloride hexahydrate) after electrocautery. Shave excision and curettage have the advantages of both being diagnostic and therapeutic procedures. Alternative treatments for flat genital seborrheic keratoses include cryotherapy, trichloroacetic acid and laser destruction. Cryotherapy is less effective for thicker, verrucous seborrheic keratoses.

Pearls

- Genital seborrheic keratoses may be misdiagnosed as genital warts.
- Histological differentiation of seborrheic keratoses from genital warts can be difficult.
- Wrongly diagnosing a seborrheic keratosis as a genital wart leads to a negative impact on sexual quality of life and inappropriate treatment.

Reference

1. Sudhakar N, Venkatesan S, Mohanasundari PS, Thilagavathy S, Elangovan P. Seborrheic keratosis over genitalia masquerading as Buschke Lowenstein tumor. *Indian J Sex Transm Dis*. 2015;36:77–9.

48.1 Definition

Vitiligo is an acquired disease of loss of skin pigment, probably due to autoimmune destruction of melanocytes. *Hypopigmentation* is the clinical sign of a lighter-coloured macule or patch compared with the background skin colour, regardless of cause. *Depigmentation* is loss of skin pigmentation.

48.2 Aetiology

Approximately 1% of the world's population develops vitiligo, across all skin types. The exact etiology of vitiligo is unknown, but vitiligo is most likely an autoimmune disease. Familial clustering of vitiligo occurs, but inheritance is by a non-Mendelian pattern. Vitiligo is associated with other autoimmune diseases, including autoimmune thyroid disease, diabetes mellitus and alopecia areata. Melanocytes are destroyed by autoreactive CD8+ cytotoxic T cells. Segmental vitiligo is harder to explain; it may be the result of the release of chemical mediators from peripheral nerves.

Depigmentation usually occurs following inflammatory skin disease or chemical exposure. Post-inflammatory depigmentation or hypopigmentation follows various inflammatory diseases, including atopic dermatitis, psoriasis and lupus erythematosus. Depigmentation may follow occupational chemical exposure or the use of topical medications such as imiquimod [1].

48.3 Clinical Features

Vitiligo affects both sexes, with the peak incidence between 10 and 30 years age. The key clinical sign is asymptomatic, sharply defined macules or patches of white skin with no scaling, usually symmetrically distributed. Vitiligo is mostly asymptomatic. Some patients report itching or burning [2], and others report distress from the cosmetic impact of their

disease. Symmetrical depigmentation of the distal fingers and periorificial region is the most common pattern (acrofacial vitiligo). Other patterns include generalised (widespread) vitiligo, mucosal vitiligo (confined to mucosae), solitary focal vitiligo, segmental vitiligo, Koebner pattern (isomorphic phenomenon), and universal vitiligo (total or near-total depigmentation). Trichrome vitiligo is a morphologic variant in which partially depigmented patches exist within a totally depigmented patch. Vitiligo may involve the male genitalia, either locally or part of widespread vitiligo (Figs. 48.1, 48.2, 48.3, 48.4, and 48.5). Vitiligo of the genitalia may have a significant negative impact on patients' sexuality and quality of life [2]. Wood's (UVA) lamp examination is a useful diagnostic aid, that clearly demonstrates the distinct patches of depigmentation and helps to define the extent of vitiligo.

48.4 Diagnosis

Correct clinical diagnosis is essential, aided with Wood's (UVA) lamp examination. History-taking may reveal occupational exposure or other exposure to known depigmenting



Fig. 48.1 Vitiligo limited to the penile shaft

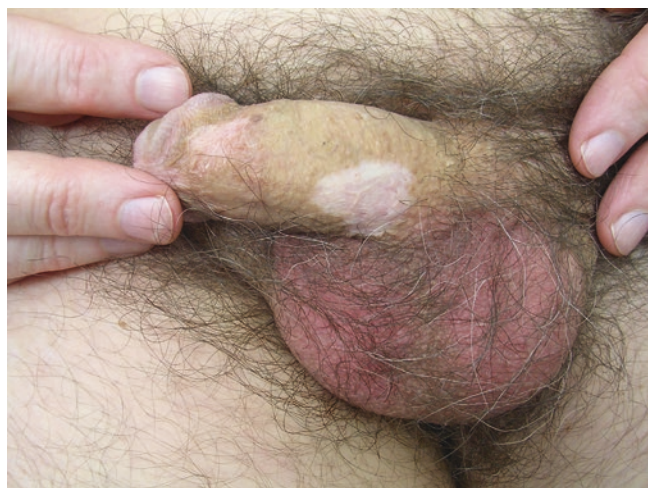

Fig. 48.2 Vitiligo of the penile shaft

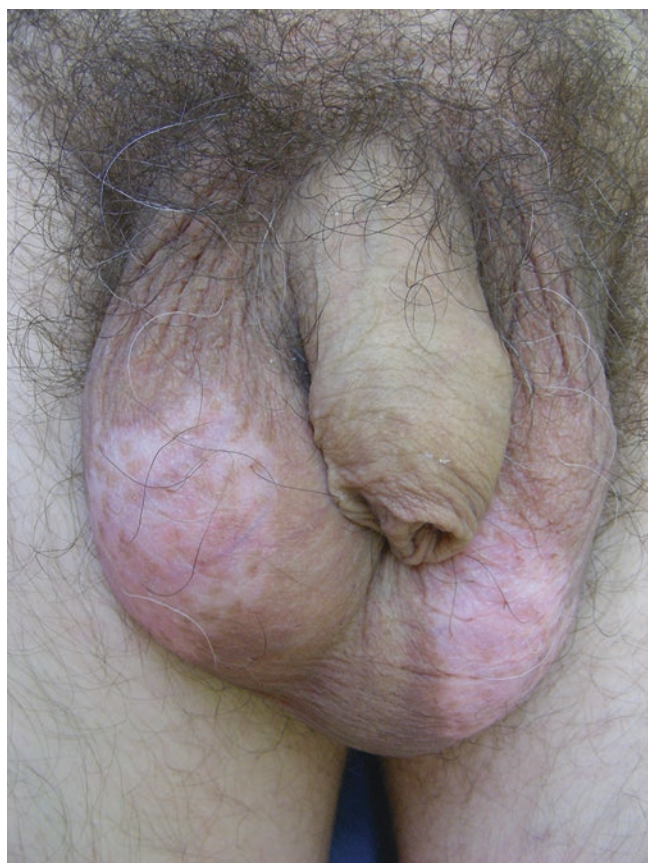

Fig. 48.3 Vitiligo of the scrotum

preparations. Cosmetic bleaching creams are commonly used in many parts of the world. Topical imiquimod used to treat genital warts has resulted in genital depigmentation identical to vitiligo [1]. Investigations to exclude associated diseases have a low yield, but tests of thyroid function, anti-thyroid antibodies and fasting blood glucose (exclude diabetes melli-

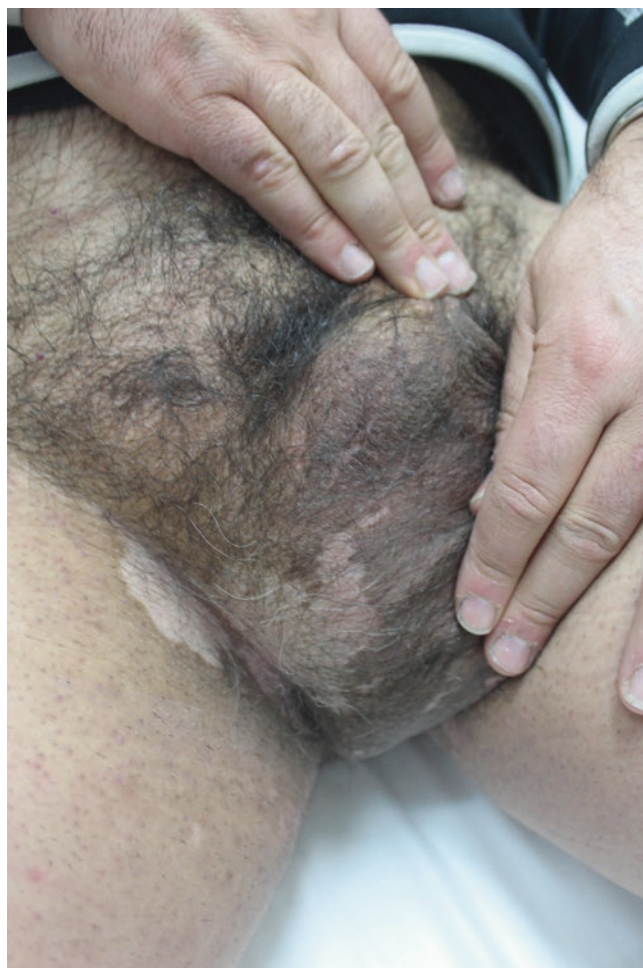

Fig. 48.4 Vitiligo affecting the scrotum and groin

tus) are important in adult patients. Fungal skin diseases may result in partial depigmentation with fine scaling, that may be confused with vitiligo. Skin scrapings for microscopy and culture help to exclude tinea corporis or pityriasis versicolor (“white spot disease” in the tropics). If depigmentation is seen around the eyes, an ophthalmology opinion helps to exclude eye involvement such as iritis, uveitis, or choroidal anomalies. Clinical examination should help to exclude rare syndromes associated with depigmentation (eg, Vogt-Koyanagi-Harada syndrome, Aalezzandrini syndrome).

The most important cause of genital hypopigmentation is lichen sclerosus (Fig. 48.6). Genital skin biopsy is valuable to confirm the clinical diagnosis of lichen sclerosus and differentiate lichen sclerosus from vitiligo. Histopathology is not routinely used to diagnose vitiligo. Skin biopsy may be helpful if the patient has widespread depigmentation to exclude diseases that may be hypopigmented or depigmented including psoriasis, lupus erythematosus, sarcoidosis, cutaneous T-cell lymphoma, leprosy and syphilis. Syphilis serology is necessary if syphilis is suspected. Depigmentation has rarely been reported in metastatic melanoma.

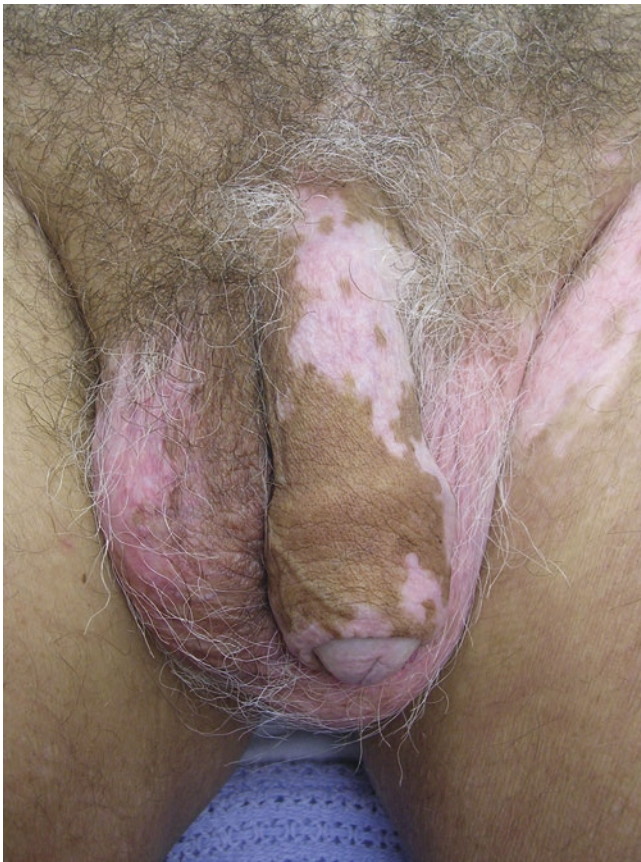

Fig. 48.5 Extensive vitiligo on the penis, scrotum, and groin

48.5 Treatment

For most patients, vitiligo is primarily a cosmetic problem with a significant negative psychological impact. The most important aspect of management is to determine the impact of vitiligo on each individual. The strongest predictors of negative impact on quality of life are the extent of depigmentation (greater than 25% body surface area) and the number of anatomical sites affected. Genital involvement is associated with increased sexual dysfunction [2, 3]. Surprisingly, the duration of vitiligo has less negative impact on quality of life. The cosmetic impact of vitiligo is often more significant amongst populations of predominantly darker skin phototypes (“skin of colour” patients). This greater impact of vitiligo may be partly founded in an historical fear of leprosy. The difficulty in treating vitiligo may further aggravate the negative impact of vitiligo on quality of life and sexuality.

Spontaneous repigmentation of vitiligo may occur on sun-exposed sites. Specific treatments for vitiligo at most body sites include cosmetic camouflage, use of sunscreens (to minimise the accentuation of depigmentation with tanning of sun-exposed sites), topical corticosteroids, topical calcineurin inhibitors, topical vitamin D analogues (calcipot-

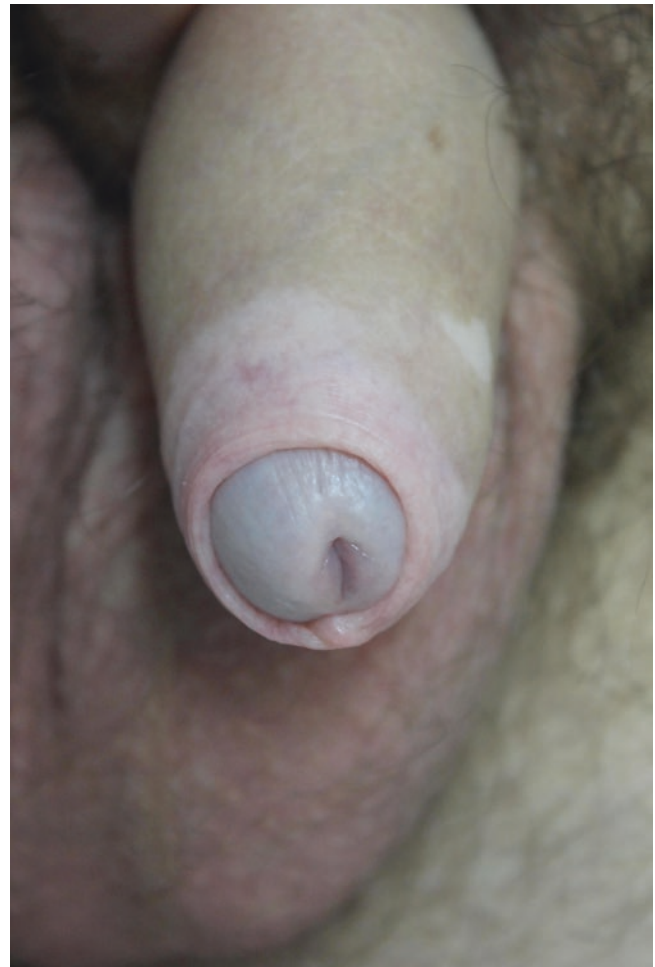

Fig. 48.6 Depigmentation of glans penis and foreskin associated with lichen sclerosus

riol), systemic psoralens with UVA exposure (PUVA), narrow-band UVB (NB-UVB), excimer laser (308 nm) and autologous skin grafting. Depigmentation is reserved for extensive disease.

Genital vitiligo often has a poorer response to topical corticosteroids than other sites. Both PUVA (photochemotherapy) and narrow-band UVB are contraindicated for treatment of genital vitiligo. Because of the significant negative psychosexual impact of genital vitiligo, surgical methods of autologous skin grafting are increasingly used in treating genital depigmentation [4].

Pearls

- Vitiligo is the most important cause of hypopigmentation worldwide.
- Genital vitiligo is often associated with a significant negative psychological impact and sexual dysfunction.

References

1. Maatouk I. Vitiligo-like lesions following imiquimod 5% application for condyloma acuminata: an additional case. *Indian J Dermatol Venereol Leprol*. 2016;82:572–4.
2. Silverberg JI, Silverberg NB. Association between vitiligo extent and distribution and quality-of-life impairment. *JAMA Dermatol*. 2013;149:159–64.
3. Morales-Sánchez MA, Vargas-Salinas M, Peralta-Pedrero ML, Olguín-García MG, Jurado-Santa Cruz F. Impact of vitiligo on quality of life. *Actas Dermosifiliogr*. 2017;108:637–42.
4. Li X, Hong W, Xu AE. Two cases of focal scrotal vitiligo successfully treated by autologous cultured melanocyte transplantation. *Dermatol Ther (Heidelb)*. 2014;4:141–4.

Scrotal Epidermal (Epidermoid) Cysts and Idiopathic Scrotal Calcinosis

49

49.1 Definition

Epidermal (epidermoid or infundibular) cysts are common dermal cysts lined by stratified epithelium, which occur mostly on the face, neck and trunk but are also seen on the scrotum. *Idiopathic scrotal calcinosis* is a rare disorder of the scrotum characterized by single or multiple calcified nodules in the setting of normal calcium and phosphate metabolism.

49.2 Aetiology

Epidermal cysts are thought to derive from a pilosebaceous follicle, possibly from implantation of epidermis. Epidermal cysts are usually solitary but are also a feature of Gardner syndrome.

The aetiology of idiopathic scrotal calcinosis is disputed but is thought to be dystrophic calcification of epidermal cysts or necrosis of the dartos muscle with subsequent dystrophic calcification (similar to the process of calcification of uterine leiomyomata) [1].

49.3 Clinical Features

Epidermal cysts are firm dermal cysts that are mobile over deeper structures and may be single or multiple. Most cysts are skin-coloured, but may appear white, yellow or even pink on the scrotum (Figs. 49.1, 49.2, and 49.3). Epidermal cysts vary in size from few millimetres up to 5 cm in diameter. An opening or punctum is often visible overlying an epidermal cyst on the face, neck or trunk. A punctum is not visible with scrotal epidermal cysts. The commonest sites are the face, neck and trunk, but epidermal cysts frequently occur on the scrotum. Epidermal cysts are quite slow-growing and usually asymptomatic, but may become tender when inflamed or infected. Occasionally, epidermal cysts may rupture or discharge. Scrotal epidermal cysts may be quite pruritic. Excoriated papules and nodules may be seen on the scrotum clinically (Fig. 49.4).

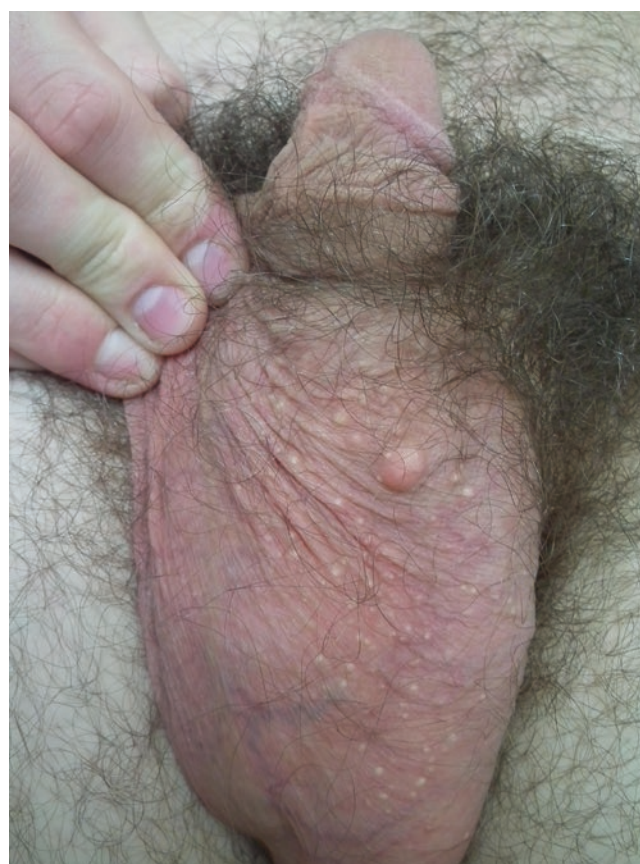

Fig. 49.1 Solitary epidermal cyst of the scrotum with multiple ectopic sebaceous glands

Idiopathic scrotal calcinosis is characterised by single or multiple, firm, white or yellow nodules that appear in adolescence or early adulthood, though patients may present for medical attention years later. Multiple nodules are mostly located on the anterior scrotum (Figs. 49.5 and 49.6) and only rarely occur on the penile shaft or perineum. Scrotal nodules vary in size from a few millimetres to 3 cm in diameter and slowly increase in size. They are initially asymptomatic but may become tender, itchy, or painful. Occasionally, the nodules are quite pedunculated. These

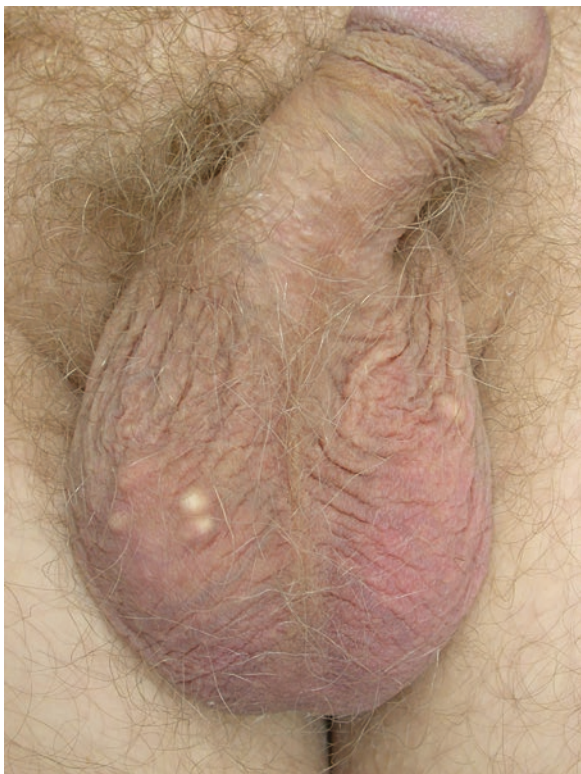


Fig. 49.2 Epidermal cysts of the scrotum

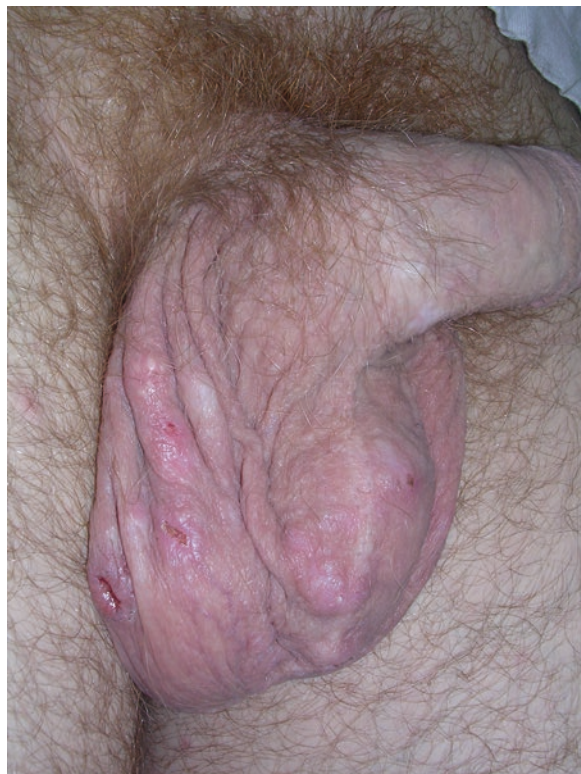

Fig. 49.4 Excoriated pruritic epidermal cysts of the scrotum

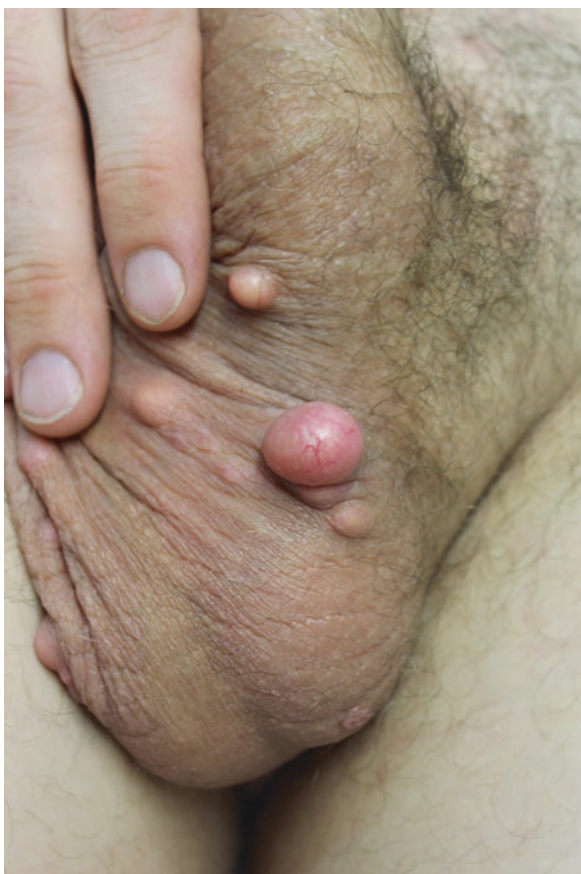

Fig. 49.3 Multiple soft and pedunculated epidermal cysts on the scrotum

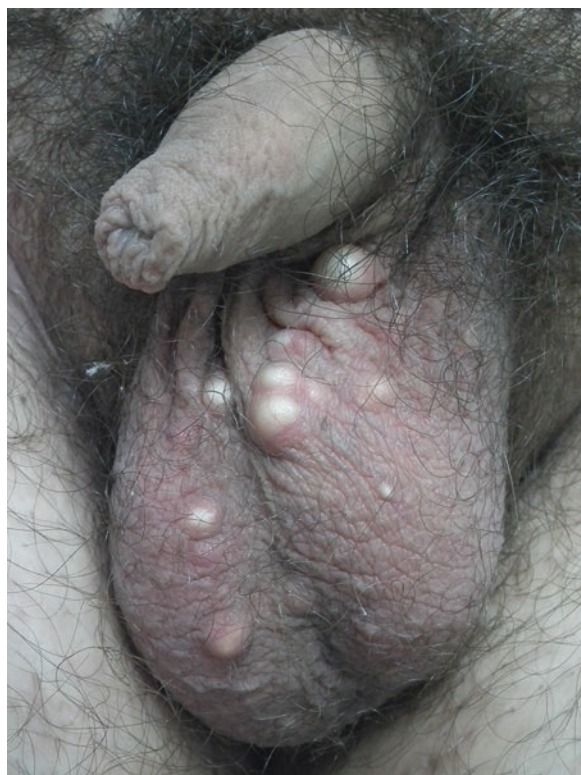

Fig. 49.5 Idiopathic scrotal calcinosis

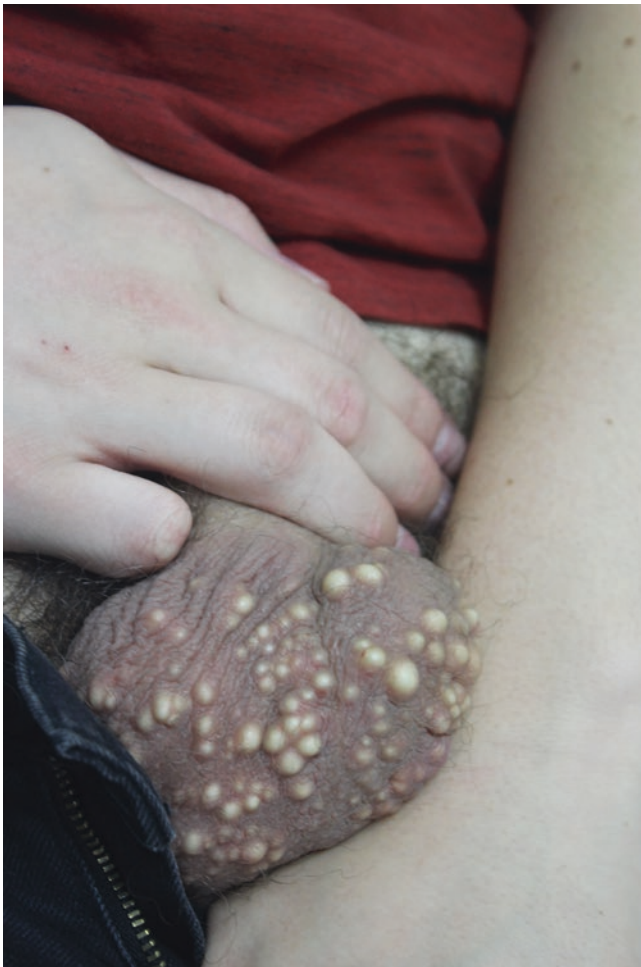

Fig. 49.6 Idiopathic scrotal calcinosis

nodules often cause great embarrassment, with resulting sexual dysfunction. Nodules of idiopathic scrotal calcinosis may discharge white, chalky material and become secondarily infected, like epidermal cysts.

49.4 Diagnosis

Epidermal cysts and idiopathic scrotal calcinosis are diagnosed clinically. It is important to exclude abnormal calcium, phosphate and parathyroid hormone metabolism in both

idiopathic scrotal calcinosis and Gardner syndrome. If an epidermal cyst is excised, the histology reveals a true cyst lined by stratified epithelium with epidermal keratinisation. Rupture of an epidermal cyst may produce a granulomatous foreign body reaction with a heavy inflammatory cell infiltrate in the dermis, resulting in fibrosis.

The histology of idiopathic scrotal calcinosis reveals multiple calcified dermal deposits with no true epithelial lining [2]. A variable focal foreign body granulomatous reaction may be seen, with fibrosis and focal transepidermal elimination of calcium deposits [1].

49.5 Treatment

Though neither epidermal cysts nor idiopathic scrotal calcinosis are considered premalignant diseases, surgical removal is often requested. Simple elliptical excision of these cysts under local anaesthesia is curative. General anaesthesia may be necessary to excise multiple nodules of idiopathic scrotal calcinosis.

Pearls

- Scrotal epidermal cysts and idiopathic scrotal calcinosis presents as multiple scrotal nodules that may result in significant sexual dysfunction.
- Surgical excision of scrotal epidermal cysts and idiopathic scrotal calcinosis nodules is usually curative.

References

1. Pompeo A, Molina WR, Pohlman GD, Sehr D, Kim FJ. Idiopathic scrotal calcinosis: a rare entity and a review of the literature. *Can Urol Assoc J*. 2013;7:E439–41.
2. Wollina U, Schönlebe J, França K, Tchernev G, Lotti T. Idiopathic scrotal calcinosis: a case report. *Open Access Maced J Med Sci*. 2018;6:108–9.

Penile Intraepithelial Neoplasia (Erythroplasia of Queyrat, Bowen's Disease)

50

50.1 Definition

Penile intraepithelial neoplasia (PIN) is *in situ* squamous cell carcinoma of the male genitalia with no invasion into the dermis or lymphovascular system. Penile intraepithelial neoplasia has three variants: erythroplasia of Queyrat, Bowen's disease (Bowen disease), and bowenoid papulosis. The distinction between Bowen's disease of the penis and erythroplasia of Queyrat is historical. Bowen's disease of the penis is *in situ* squamous cell carcinoma (SCC) of genital hair-bearing skin (the penile shaft or scrotum) (Fig. 50.1). Erythroplasia of Queyrat is *in situ* SCC of the glans penis or of the mucosal aspect of the foreskin in uncircumcised men (Figs. 50.2, 50.3, 50.4, and 50.5). The term *erythroplasia of Queyrat* could be abandoned, as it is a subset of male genital Bowen's disease and both are encompassed within penile intraepithelial neoplasia [1]. Bowenoid papulosis exhibits different biologic behaviour from penile Bowen's disease and erythroplasia of Queyrat and is discussed separately in Chap. 51.

50.2 Aetiology

Aetiological factors for penile intraepithelial neoplasia include being uncircumcised (presence of a foreskin), coexisting human papillomavirus (HPV) infection (70–100% of cases), lichen sclerosus [2], smoking and immunosuppression.

50.3 Clinical Features

Penile intra-epithelial neoplasia (PIN) is mostly a disease of uncircumcised men (more than 90%) over 45 years of age, with the peak incidence at 60–70 years. PIN is usually asymptomatic, but some patients report itch, crusting, soreness, pain, ulceration or bleeding. PIN usually presents as a single, slow-growing, smooth, moist red plaque on the glans or the mucosal aspect of the foreskin, but it may

present as multiple macules, papules, or plaques of the glans, foreskin, penile shaft, or scrotum. PIN on the glans penis may involve the urethral meatus and distal penile urethra. In circumcised men, PIN may present as a keratotic skin-coloured or yellow plaque with visible scale on a fully keratinised glans penis.

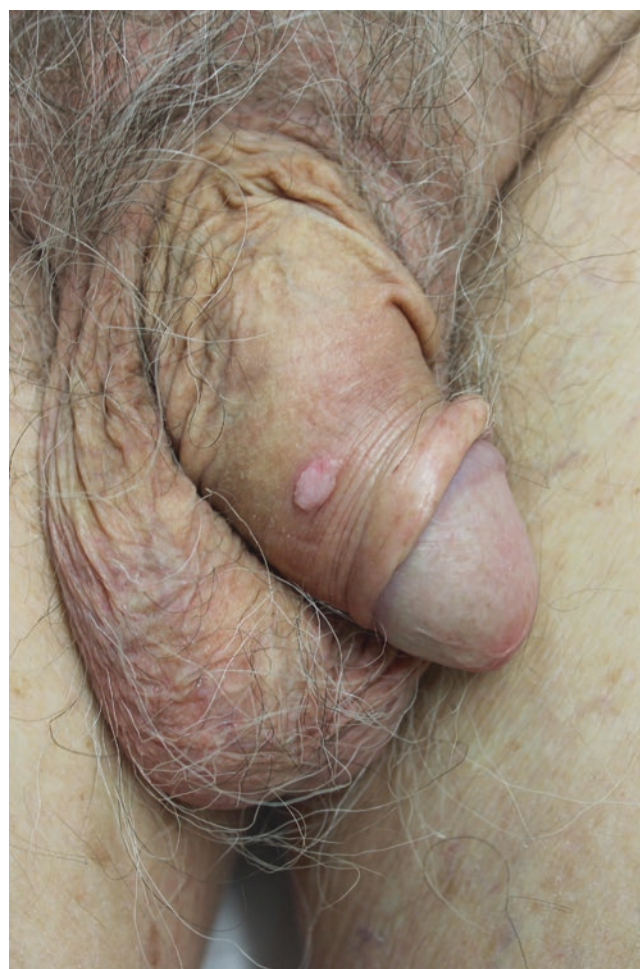

Fig. 50.1 Penile intraepithelial neoplasia of the shaft of the penis (Bowen's disease)

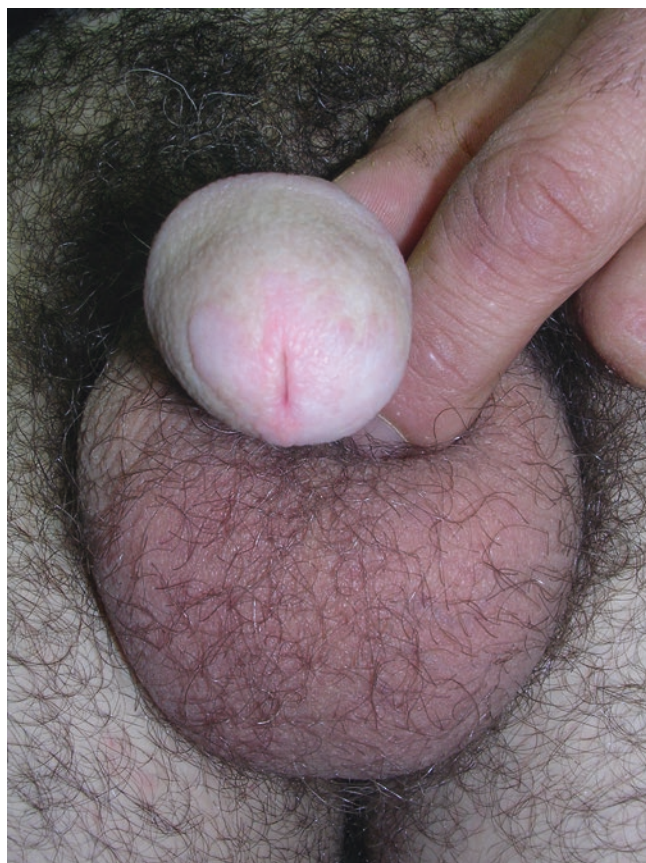

Fig. 50.2 Penile intraepithelial neoplasia of the glans penis (erythroplasia of Queyrat)

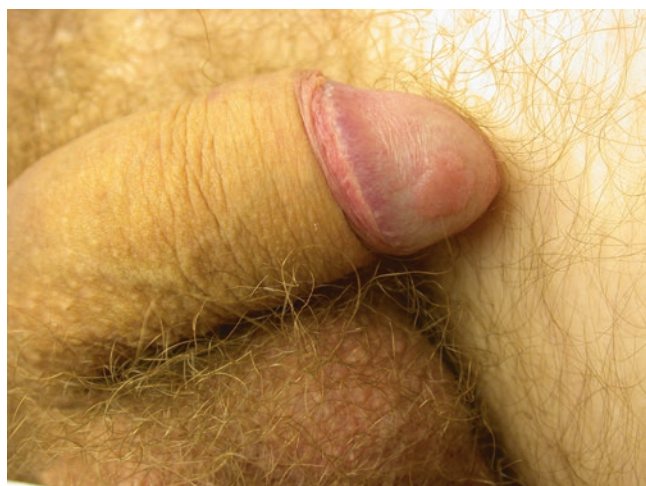


Fig. 50.3 Penile intraepithelial neoplasia of the glans penis

50.4 Diagnosis

PIN is the most important premalignant disease of male genitalia. PIN needs to be excluded for any macule, papule or plaque of the male genitalia, especially those involving the

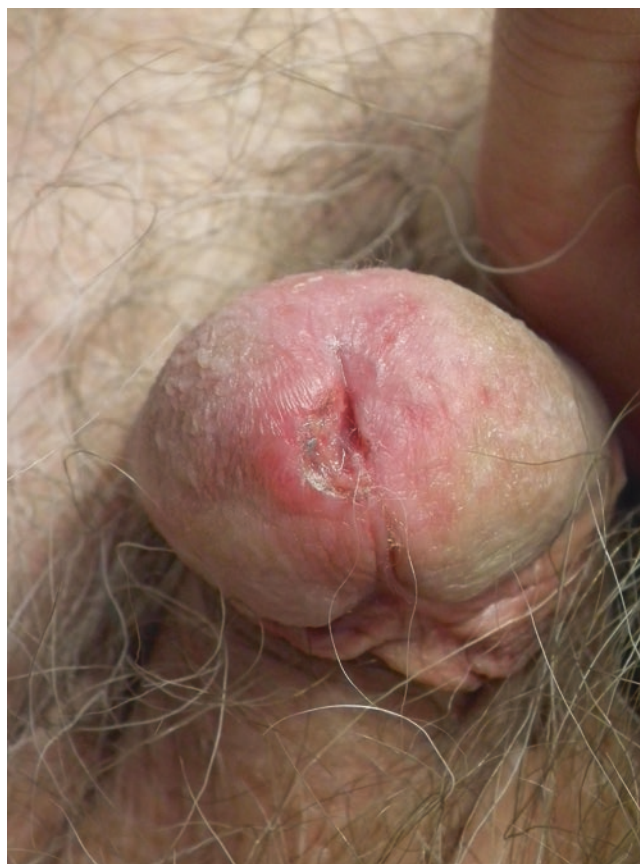

Fig. 50.4 Extensive penile intraepithelial neoplasia of the glans extending to the urethral meatus

glans, urethral meatus or foreskin of an uncircumcised adult. Full clinical examination and ano-genital examination helps to exclude evidence of any associated skin disease such as psoriasis, eczema or lichen planus. Important differential diagnoses of PIN include genital warts (condyloma acuminata), psoriasis, irritant dermatitis, candidiasis, plasma cell (Zoon's) balanitis, fixed drug eruption, seborrhoeic keratoses and early invasive squamous cell carcinoma (SCC). Clinical suspicion of penile intraepithelial neoplasia needs to be confirmed by histology. The best option for the biopsy of PIN of the glans is a punch biopsy with suturing of the biopsy site. Shave biopsy may be preferable for a keratotic plaque on the penile shaft or scrotum.

50.5 Treatment

The risk that PIN will progress to invasive SCC is estimated to be 10–30% [3]. The aims of treatment for PIN are complete removal of the *in situ* SCC while minimising any adverse functional or cosmetic outcome. It is important to balance the necessity of clearing *in situ* SCC with the patient's wishes and any possible adverse cosmetic result.

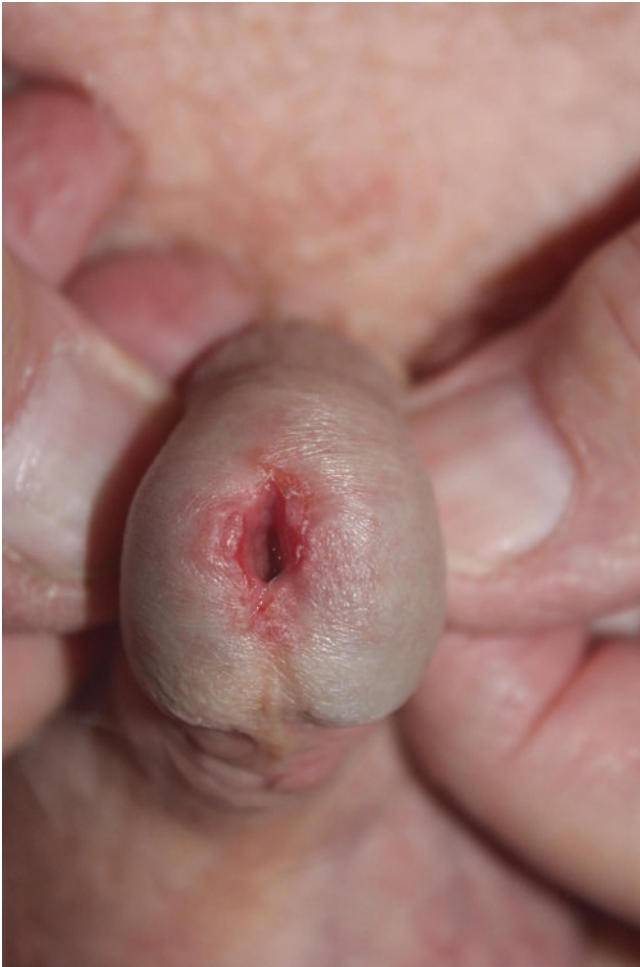

Fig. 50.5 Penile intraepithelial neoplasia of the urethral meatus

Circumcision is important, to debulk the precancerous disease and remove adjacent tissue that may be infected with HPV [2]. Circumcision also permits easier self-application of topical treatments and reduces the likelihood of missing early development of invasive SCC.

Local treatments include shave excision, cryotherapy [4], curettage and electrocautery, topical 5-fluorouracil [5], topical imiquimod [6], topical cidofovir [7], surgical excision, Mohs' micrographic surgery, laser destruction [8, 9] and photodynamic therapy [10]. Topical 5-fluorouracil cream is applied twice daily for 3 weeks. Occlusion under plastic wrap helps prevent the cream from being wiped off onto underwear. The complete response rate for topical 5-fluorouracil at 10 years is 50% [11]. Topical imiquimod 5% cream is applied 5 days per week for 4–6 weeks, with a complete response rate at 10 years of 44% [11]. Topical 5-fluorouracil or topical imiquimod cream may be applied less frequently and subsequently slowly weaned. All patients need to be counselled about adverse effects associated with these topical treatments, including the potential for a partial or no response with the risk of recurrence [12]. Combination

topical treatments can be utilised to treat PIN. Cryotherapy may be combined with either topical 5-fluorouracil or topical imiquimod cream [3]. Sequential or simultaneous topical treatment with topical 5-fluorouracil and topical imiquimod 5% cream may result in greater clearance than either topical treatment alone. Close follow-up is important after treatment with any topical therapy.

If PIN fails to respond to topical therapy or relapses after treatment, surgery is indicated. Penis-conserving surgery is preferred to traditional radical surgery [13]. Total glans resurfacing with skin grafting treats PIN with a good cosmetic result [14]. Partial or total glans resurfacing has demonstrated that 20% of patients with PIN have underlying invasive SCC [11]. Other surgical treatments include Mohs' micrographic surgery, photodynamic therapy (PDT) and laser ablation. Recurrence of PIN is seen with all forms of penile sparing surgery. The best results are seen with glans resurfacing procedures; the highest rates of recurrence are seen after laser ablation [13]. Long-term follow-up is essential to detect recurrence of PIN or development of invasive SCC. Because of the association between PIN and HPV infection, female sexual partners should be advised to have a genital examination and Papanicolaou (Pap) smear or HPV DNA testing of cervical cells.

Pearls

- Penile intraepithelial neoplasia (PIN) is the most important premalignant genital skin disease.
- Penile intraepithelial neoplasia presents as red macules, papules or plaques of glans, urethral meatus, foreskin, penile shaft or scrotum. Skin biopsy is essential.
- If Penile intraepithelial neoplasia fails to respond to topical therapy or relapses after treatment, penile sparing surgery is necessary.

References

1. Shimizu A, Takahashi A, Ishikawa O. Bowen's disease involving the urethra. *J Dermatol*. 2005;32:210–3.
2. Porter WM, Francis N, Hawkins D, Dinneen M, Bunker CB. Penile intraepithelial neoplasia: clinical spectrum and treatment of 35 cases. *Br J Dermatol*. 2002;147:1159–65.
3. Shaw KS, Nguyen GH, Lacouture M, Deng L. Combination of imiquimod with cryotherapy in the treatment of penile intraepithelial neoplasia. *JAAD Case Rep*. 2017;3:546–9.
4. Sonnex TS, Ralfs IG, Plaza De Lanza M, Dawber RP. Treatment of erythroplasia of Queyrat with liquid nitrogen cryosurgery. *Br J Dermatol*. 1982;106:581–4.
5. Goette DK, Carson TE. Erythroplasia of Queyrat: treatment with topical 5-fluorouracil. *Cancer*. 1976;38:1498–502.
6. Micali G, Nasca MR, De Pasquale R. Erythroplasia of Queyrat treated with imiquimod 5% cream. *J Am Acad Dermatol*. 2006;55:901–3.

7. Calista D. Topical cidofovir for erythroplasia of Queyrat of the glans penis. *Br J Dermatol*. 2002;147:399–400.
8. Del Losada JP, Ferré A, San Román B, Vieira V, Fonseca E. Erythroplasia of Queyrat with urethral involvement: treatment with carbon dioxide laser vaporization. *Dermatol Surg*. 2005;31:1454–7.
9. van Bezooijen BP, Horenblas S, Meinhardt W, Newling DW. Laser therapy for carcinoma in situ of the penis. *J Urol*. 2001;166:1670–1.
10. Lee MR, Ryman W. Erythroplasia of Queyrat treated with methyl aminolevulinate photodynamic therapy. *Australas J Dermatol*. 2005;46:196–8.
11. Manjunath A, Brenton T, Wylie S, Corbishley CM, Watkin NA. Topical therapy for non-invasive penile cancer (Tis)-updated results and toxicity. *Transl Androl Urol*. 2017;6:803–8.
12. Deen K, Burdon-Jones D. Imiquimod in the treatment of penile intraepithelial neoplasia: an update. *Australas J Dermatol*. 2017;58:86–92.
13. Chipollini J, Yan S, Ottenhof SR, Zhu Y, Draeger D, Baumgarten AS, et al. Surgical management of penile carcinoma in situ: results from an international collaborative study and review of the literature. *BJU Int*. 2018;121:393–8.
14. Hadway P, Corbishley CM, Watkin NA. Total glans resurfacing for premalignant lesions of the penis: initial outcome data. *BJU Int*. 2006;98:532–6.

Suggested Reading

Morton CA, Birnie AJ, Eedy DJ. British Association of Dermatologists' guidelines for the management of squamous cell carcinoma in situ (Bowen's disease) 2014. *Br J Dermatol*. 2014;170:245–60.

51.1 Definition

Bowenoid papulosis is a clinical variant of penile intraepithelial neoplasia (PIN) with histology of *in situ* squamous cell carcinoma that usually presents as multiple papules on the glans, foreskin or penile shaft. Bowenoid papulosis has a better prognosis than erythroplasia of Queyrat or genital Bowen's disease.

51.2 Aetiology

Bowenoid papulosis has similar risk factors to other variants of penile intra-epithelial neoplasia (PIN) (erythroplasia of Queyrat and Bowen's disease), but is more strongly associated with human papillomavirus (HPV) infection, particularly HPV-16. Other HPV types, including HPV-18, are less commonly associated with bowenoid papulosis. HPV-16 is a high-risk HPV type strongly associated with cervical intraepithelial neoplasia (CIN), cervical carcinoma, vulval intraepithelial neoplasia (VIN), vulval carcinoma, anal intraepithelial neoplasia (AIN) and anal carcinoma. Other risk factors for bowenoid papulosis include being uncircumcised, smoking and immunosuppression. Bowenoid papulosis progresses to penile squamous cell carcinoma (SCC) in less than 1% of patients [1]. The malignant transformation rate may be higher in immunocompromised patients.

51.3 Clinical Features

Bowenoid papulosis is more common than erythroplasia of Queyrat or genital Bowen's disease in younger, sexually active men. Male patients with bowenoid papulosis are mostly 20–40 years of age and uncircumcised. Some have a past history of genital warts. Bowenoid papulosis appears as asymptomatic solitary or multiple macules or papules (1–4 mm in diameter) or as a solitary plaque up to 10 mm in diameter. The colour of bowenoid papulosis on the glans, foreskin and penile shaft varies from skin-coloured to pink,

red, brown, violaceous or black (Figs. 51.1, 51.2, and 51.3). Most lesions of bowenoid papulosis occur on the glans, foreskin, penile shaft or (rarely) the scrotum. Under the foreskin, bowenoid papulosis may present as red erosions (Figs. 51.4, 51.5, and 51.6). Bowenoid papulosis on the penile shaft may be more warty and pigmented, as seen

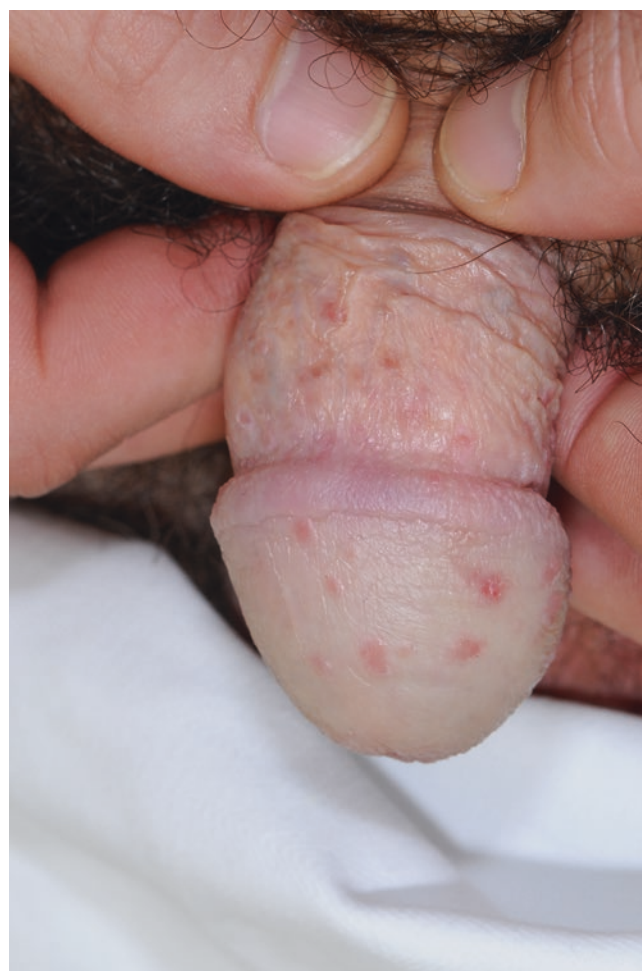

Fig. 51.1 Pink papules of bowenoid papulosis on glans penis and under the foreskin

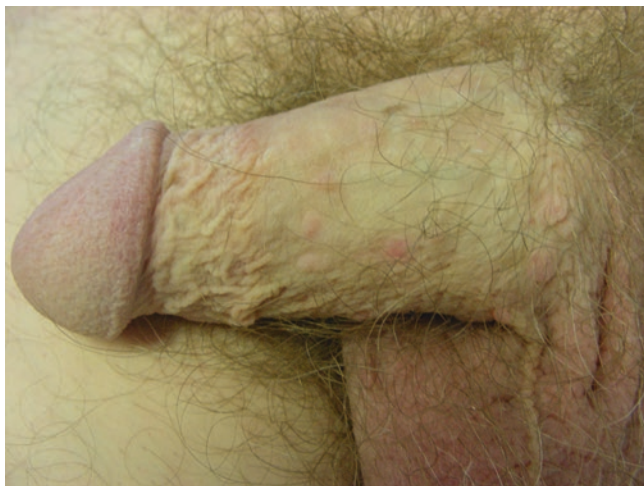

Fig. 51.2 Pink papules of bowenoid papulosis on penile shaft

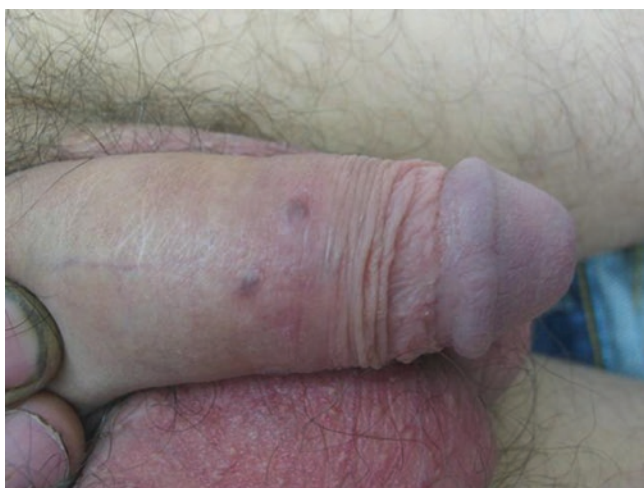

Fig. 51.3 Pigmented papules of bowenoid papulosis on penile shaft

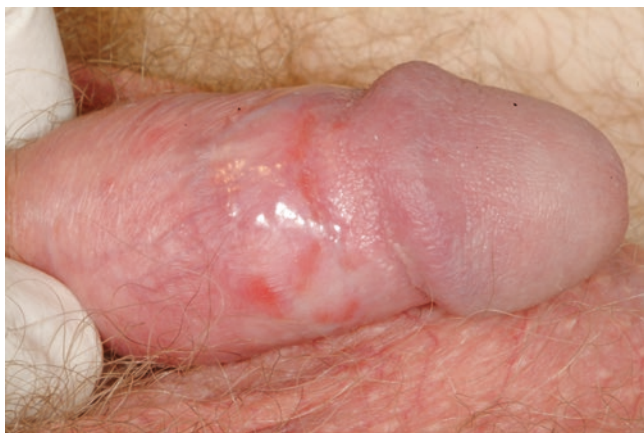

Fig. 51.4 Eroded red papules of bowenoid papulosis under the foreskin

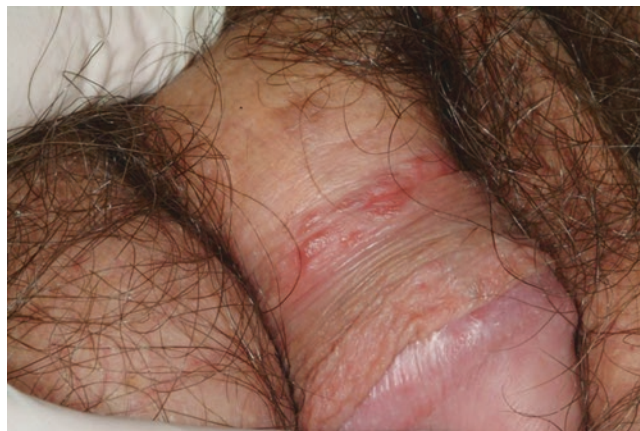

Fig. 51.5 Eroded red-brown papules of bowenoid papulosis under the foreskin

with vulval bowenoid papulosis. The duration of individual lesions ranges from a few weeks to over 10 years, with a mean duration of 8 months [2].

51.4 Diagnosis

Bowenoid papulosis is probably often clinically misdiagnosed and treated as genital warts (condyloma acuminata). Dermoscopy may be used as a diagnostic aid for bowenoid papulosis [3]. Bowenoid papulosis is usually seen in younger men as multiple papules, whereas genital Bowen's disease usually presents as solitary or multiple plaques in older men [4]. Skin biopsy is essential to confirm the diagnosis of *in situ* SCC. Definitive diagnosis of bowenoid papulosis is by clinical and histopathological correlation. Differentiation from erythroplasia of Queyrat and genital Bowen's disease is important, as all three have identical histology but different biologic behaviour. A histopathologist may issue a report of genital Bowen's disease based on histology of *in situ* SCC when insufficient clinical information has been provided. Differentiation of these variants of PIN is possible only when histology is combined with correct interpretation of the clinical findings. Clinical differential diagnoses of bowenoid papulosis include genital warts (condyloma acuminata), erythroplasia of Queyrat, genital Bowen's disease, molluscum contagiosum, seborrhoeic keratoses, melanocytic nevi, lichen planus, and early invasive SCC.

51.5 Treatment

Bowenoid papulosis will probably be prevented or reduced in incidence by widespread HPV vaccination of children and young adults. Bowenoid papulosis may resolve spontane-

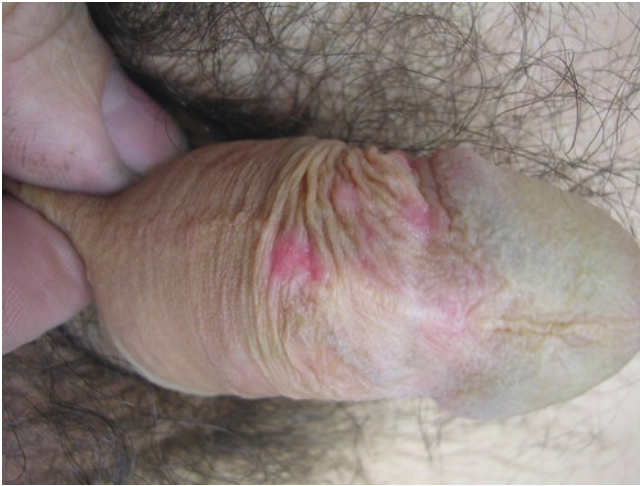

Fig. 51.6 Eroded red papules of bowenoid papulosis ventral penile shaft under foreskin

ously [5], persist, or recur after treatment. Patients should be informed that the estimated rate of transformation of bowenoid papulosis to invasive SCC is less than 1% of cases. If the correct diagnosis is confidently made, any treatment of bowenoid papulosis should be discussed in light of this low rate of malignant transformation, although the rate may be higher in immunosuppressed patients. As with treatment of erythroplasia of Queyrat, circumcision is an important aspect of treatment of bowenoid papulosis [1]. Following circumcision, treatment options include cryotherapy, topical imiquimod, topical 5-fluorouracil, and electrocautery. Combining cryotherapy with topical imiquimod or topical 5-fluorouracil is more likely to maintain a sustained response. Treatment with topical imiquimod has theoretical advantages because of the strong association with HPV-16. Other topical treatments include podophyllin resin, topical cidofovir and topical tazarotene. Excisional surgery, laser destruction, and photodynamic therapy (PDT) have all been reported as treatment for bowenoid papulosis, but are probably more suitable

treatment options for erythroplasia of Queyrat and genital Bowen's disease. Long-term follow-up is essential to assess the efficacy of treatment and to detect recurrence and malignant transformation. Partners of patients with bowenoid papulosis need to be screened for the development of HPV-associated intraepithelial neoplasia (both cervical intraepithelial neoplasia and anal intraepithelial neoplasia) and followed-up long-term [1].

Pearls

- Bowenoid papulosis may appear as skin-coloured, pink or red smooth papules, rather than pigmented verrucous papules.
- Bowenoid papulosis rarely progresses to invasive squamous cell carcinoma.
- Bowenoid papulosis is best treated with a combination of circumcision, cryotherapy and topical imiquimod or topical 5-fluorouracil.

References

1. Porter WM, Francis N, Hawkins D, Dinneen M, Bunker CB. Penile intraepithelial neoplasia: clinical spectrum and treatment of 35 cases. *Br J Dermatol*. 2002;147:1159–65.
2. Peng WS, Tan C. Bowenoid papulosis in a linear distribution. *Postepy Dermatol Alergol*. 2016;33:146–8.
3. Marcucci C, Sabban EC, Friedman P, Peralta R, Calb I, Cabo H. Dermoscopic findings in bowenoid papulosis: report of two cases. *Dermatol Pract Concept*. 2014;4:61–3.
4. Nayak SU, Sheno SD, Bhat ST, Shivamurthy A. Bowenoid papulosis. *Indian J Sex Transm Dis*. 2015;36:223–5.
5. Smith SM, Peters S, Blumenfeld ML, Chen W. Vulvar bowenoid papulosis: histologically high-grade squamous intraepithelial lesion known to spontaneously regress. *J Low Genit Tract Dis*. 2017;21:e30–2.

Pseudoepitheliomatous Keratotic and Micaceous Balanitis and Penile Cutaneous Horn

52

52.1 Definition

Pseudoepitheliomatous, Keratotic, and micaceous balanitis (of Civatte) is a rare precancerous disease of the glans penis, that presents as a thick, scaly plaque. *Penile horn* is a morphologic description for an elongated, hard keratotic growth arising from the glans due to a variety of diseases.

52.2 Aetiology

The aetiologies of both pseudoepitheliomatous, keratotic, and micaceous balanitis (PEKMB) and penile (cutaneous) horn are unknown. PEKMB is associated with circumcision in adult life of older males for phimosis [1]. Chronic irritation and inflammation of long standing phimosis may predispose to PEKMB [2]. It is uncertain whether PEKMB is a precancerous disease of the glans or is a form of locally invasive verrucous carcinoma. It has a high rate of transformation into squamous cell carcinoma (SCC) [1]. Some consider malignant transformation of PEKMB into well-differentiated SCC as universal [3]. Others consider PEKMB has a low-grade malignant potential [4]. Human papillomavirus (HPV) has not been linked to PEKMB.

Cutaneous horns commonly arise from solar (actinic) keratoses on sun-exposed sites. They arise less often from a variety of benign lesions, including seborrhoeic keratoses and from *in situ* SCC and invasive SCC. Penile horn is a morphologic descriptive term with no reference to pathology. Suggested aetiologies for penile horn include chronic inflammation or irritation under the foreskin, phimosis, trauma (including trauma associated with circumcision), HPV infection and radiotherapy. Most of these factors are also aetiologic factors for penile cancer. Development of penile horn has been reported 2 weeks to 12 months after circumcision. Penile horns may originate from genital warts, molluscum contagiosum, PEKMB, keratoacanthoma, verrucous carcinoma or SCC. Penile horn is considered a pre-malignant disease.

52.3 Clinical Features

Most patients with PEKMB are uncircumcised men over 50 years of age [1]. Some have been circumcised as adults for phimosis. PEKMB usually appears as an asymptomatic solitary, well-demarcated, scaly hyperkeratotic plaque on the glans, with a laminated or mica appearance that may be peeled off (Fig. 52.1) [5]. It usually slowly increases in size and may cause phimosis [1] or deviation of the urinary stream. Irritation or burning may be reported. The scaly plaque may look like psoriasis or may be crateriform in appearance and has features in common with verrucous carcinoma. A nodule of SCC may arise within the keratotic plaque.

Men who develop a penile horn are similar to those with PEKMB, being uncircumcised and older than 50 years of age. Similar to an animal horn, a penile horn is a single hard, tapered, keratotic and elongated growth arising from a warty base on the glans. Penile horns are usually curved and are clinically identical to cutaneous horns arising on sun-damaged skin at other body sites. A penile horn may arise on the glans after circumcision for

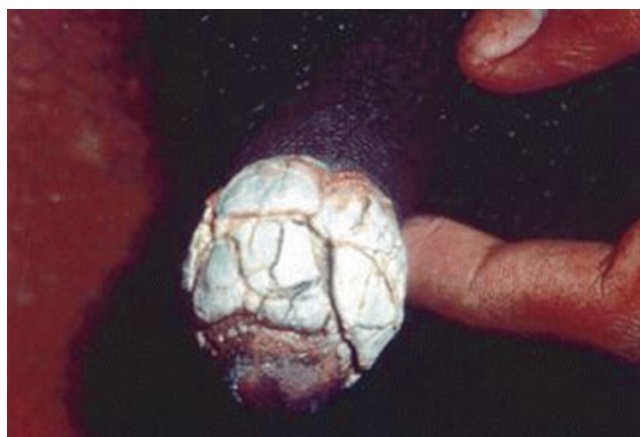

Fig. 52.1 Pseudoepitheliomatous, keratotic, and micaceous balanitis of the glans penis. (From Bunker [5]; with permission from Elsevier.)

phimosis. The main patient concern is the cosmetic appearance, but penile horns may be painful if knocked or with sexual activity.

52.4 Diagnosis

PEKMB may be clinically indistinguishable from psoriasis, genital warts, penile intraepithelial neoplasia, early invasive SCC or verrucous carcinoma. The diagnosis of PEKMB needs to be confirmed by histopathology. A complete shave excision biopsy of the entire lesion is preferred for histological examination, but a partial shave biopsy or incisional biopsy is usually adequate. Histology confirms hyperkeratosis, parakeratosis, acanthosis with mild epidermal dysplasia, or features of verrucous carcinoma with acanthotic downgrowths of well-differentiated SCC.

Similarly, it is essential to confirm the diagnosis of penile horn by histology. A complete shave excision of the penile horn is best for diagnostic and therapeutic reasons. Alternatively, some prefer an incisional or excisional biopsy that allows suturing of the biopsy site to achieve hemostasis. Histology of a penile horn demonstrates amorphous or lamellated keratotic material arising from either a benign, premalignant, or malignant lesion. Approximately one third of penile horns arise from a penile cancer [3].

52.5 Treatment

Treatment of PEKMB is aimed at total removal of the lesion with glans-preserving surgery. Treatment is partly based on patient factors such as patient age and the histology of the underlying disease process. If there is no cytological atypia, treatment may be more conservative, with circumcision combined with shave excision, cryotherapy or topical 5-fluorouracil [1, 2, 4–6]. If the lesion is treated with cryotherapy or topical 5-fluorouracil, post-treatment skin biopsies to confirm disease clearance are wise [2]. If histology shows well-differentiated

SCC, treatment with local surgical excision or Mohs' surgery is preferable. Alternative treatments include photodynamic therapy or radiotherapy. Follow-up is important to detect recurrence after treatment [4].

Treatment of penile horn is based on the pathology of the underlying disease. All treatments are aimed at penile conservation, as the prognosis for a penile horn arising from SCC is good. Circumcision is combined with local penile preserving surgery. Partial or total glansectomy or partial penectomy may be necessary, depending on pathology. Long-term follow-up is important to detect recurrence or invasive transformation, particularly if SCC is not detected by the initial biopsy.

Pearls

- Pseudoepitheliomatous, keratotic and micaceous balanitis is a precancerous disease with features in common with verrucous carcinoma.
- Penile horn is a premalignant, hard, elongated keratotic outgrowth from the glans penis.

References

1. Malkud S, Dyavannanavar V. Pseudoepitheliomatous, keratotic and micaceous balanitis: a case report. *J Clin Diagn Res.* 2015;9(10):WD01–2.
2. Das S, Ghoshal L. Pseudoepitheliomatous keratotic and micaceous balanitis of Civatte. *Indian Dermatol Online J.* 2014;5(2):148–50.
3. von Krogh G, Horenblas S. Diagnosis and clinical presentation of premalignant lesions of the penis. *Scand J Urol Nephrol Suppl.* 2000;205:201–14.
4. Adya KA, Palit A, Inamadar AC. Pseudoepitheliomatous keratotic and micaceous balanitis. *Indian J Sex Transm Dis.* 2013;34(2):123–5.
5. Bunker CB. *Male genital skin disease.* London: Elsevier Saunders; 2004.
6. Hanumaiah B, Mohan LNB, Kumaraswamy SK, Vijaya B. Pseudoepitheliomatous keratotic and micaceous balanitis: a rare condition successfully treated with topical 5-fluorouracil. *Indian J Dermatol.* 2013;58(6):492.

53.1 Definition

Cancers of the penis are cutaneous malignancies involving the glans, foreskin or penile shaft. Most penile cancers are squamous cell carcinomas (SCC). Rarer penile cancers include melanoma, giant condyloma of Buschke-Lowenstein, extramammary Paget's disease, Kaposi's sarcoma, basal cell carcinoma, and genital cutaneous metastases.

53.2 Aetiology

Over 90% of penile cancers are SCCs. Other penile cancers include verrucous carcinoma (a low-grade, well-differentiated variant of SCC), melanoma, basal cell carcinoma, Kaposi's sarcoma and extramammary Paget's disease. Penile SCCs may arise *de novo* or from preexisting lesions. Penile SCC has two pathogenic pathways: penile SCC can be associated with human papillomavirus (HPV) or independent of HPV. Predisposing factors include increasing age, presence of the foreskin (neonatal circumcision is partially protective for penile SCC), poor genital hygiene, phimosis, HPV infection, chronic genital inflammatory skin disease ("chronic balanitis"), prior psoralen and UVA photochemotherapy (PUVA) treatment and smoking. Penile SCC is predominantly a malignancy of uncircumcised older males, mostly over 50 years of age. In developed countries, penile cancer represents less than 1% of all male cancers. Penile cancer represents up to 10% of cancers in the developing world (Asia, Africa, South America). Neonatal circumcision is partially protective for penile SCC. This may relate to better genital hygiene, minimal smegma accumulation, prevention of phimosis, prevention of lichen sclerosus and less HPV infection in adult life.

The most important premalignant lesion is penile intraepithelial neoplasia (PIN), which includes erythroplasia of Queyrat of the glans and Bowen's disease of the penile shaft or scrotum. HPV infection is associated with less than 50% of invasive penile SCCs [1] but HPV infection is associated with

70–100% of cases of *in situ* SCC (PIN) [2]. Male recipients of solid organ transplants are at increased risk for penile cancer, suggesting that immunosuppression is a host co-factor [3]. Lichen sclerosus with phimosis is the most important premalignant chronic genital inflammatory skin disease. Kaposi's sarcoma is a vascular tumour associated with human herpesvirus type 8 (HHV-8) that may involve skin or viscera. Kaposi's sarcoma is more common in immunosuppressed patients and has increased in frequency with the rise in HIV infection.

53.3 Clinical Features

Most men with penile SCC are uncircumcised, with a mean age of 60 years. Invasive penile SCC may be asymptomatic or patients may complain of itch, pain, bleeding, discharge, or malodour. SCC of the penis may appear as subtle macular erythema arising from *in situ* SCC (PIN) (Fig. 53.1). More commonly, it appears as an exophytic, warty nodule or plaque, which may erode or ulcerate (Fig. 53.2). Penile SCC also may present as a prominent fungating growth (Figs. 53.3 and 53.4). Penile SCCs occur most often on the glans and less commonly on the foreskin, coronal sulcus, or penile shaft. A full clinical examination is important to detect evidence of local or distant spread. Palpable inguinal lymphadenopathy is present in half of patients with penile cancer at presentation. Half of these patients with palpable inguinal lymphadenopathy have local metastatic spread, whereas the remainder show only reactive inflammatory change.

Kaposi's sarcoma, a vascular tumour associated with HHV-8, involves the skin and internal viscera. It appears as violaceous macules, papules, or plaques on skin and genitalia, but most commonly presents as single or multiple longitudinal, solid, smooth violaceous plaques. Basal cell carcinoma (BCC) is the commonest human cutaneous cancer, usually associated with ultraviolet (UV) light exposure. BCCs rarely occur on sun-protected sites such as male genitalia. When BCCs occur on male genitalia, their clinical appearance resembles BCCs seen elsewhere,

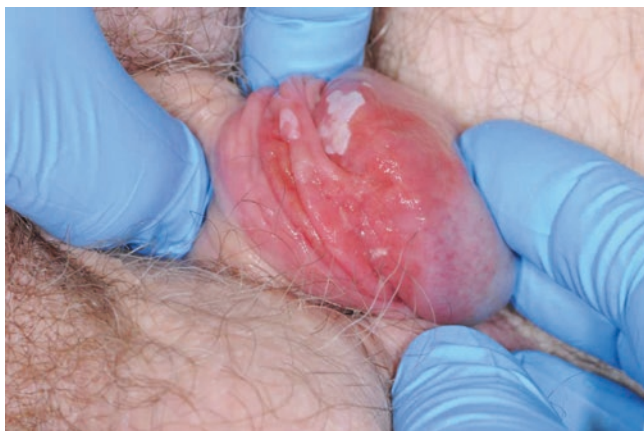

Fig. 53.1 Early invasive squamous cell carcinoma under the foreskin

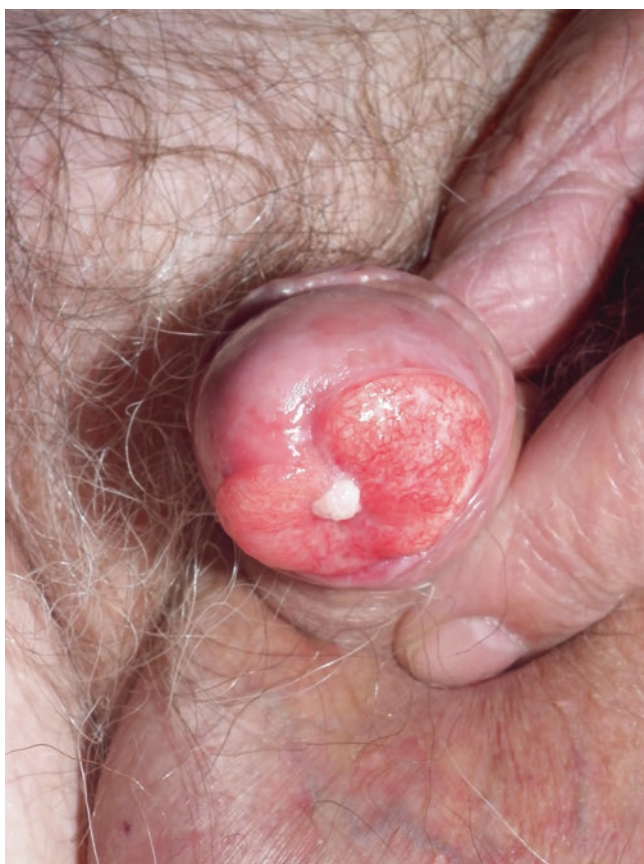

Fig. 53.2 Squamous cell carcinoma of the glans penis

as a slowly growing, red macule, papule, nodule or plaque. Nodular BCCs may appear as translucent papules or nodules. Superficial BCCs often show a pearly border (“string of pearls”). BCCs may ulcerate and may be pigmented, mimicking melanoma. Genital cutaneous metastatic deposits may mimic a BCC or Kaposi’s sarcoma. Cutaneous metastases should be considered in any patient

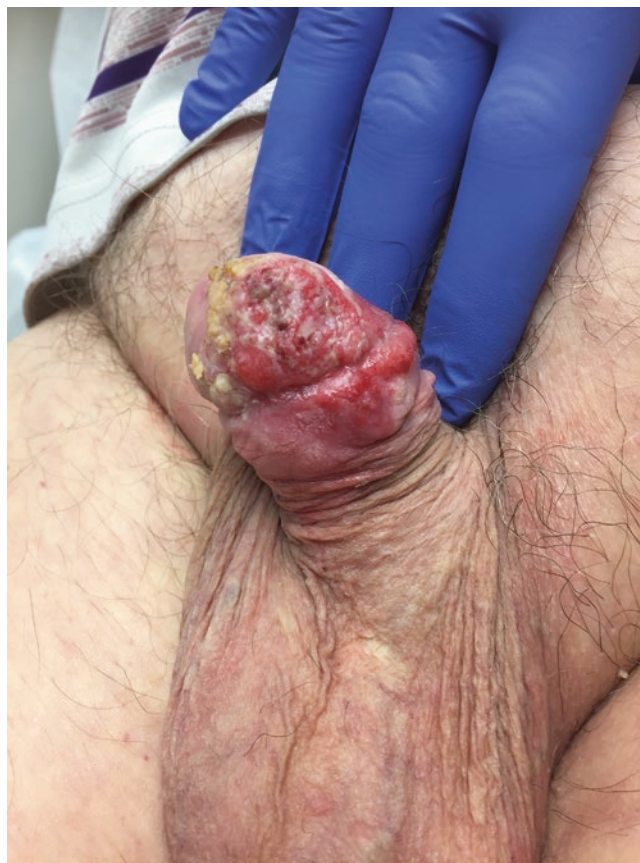

Fig. 53.3 Fungating squamous cell carcinoma of the glans penis

with known internal cancer (Fig. 53.5). Clinical features of giant condyloma of Buschke-Lowenstein, melanoma, and extramammary Paget’s disease are discussed in subsequent chapters.

53.4 Diagnosis

Penile cancer of the glans is often clinically apparent, but clinical diagnosis always needs histologic confirmation. Punch biopsy, deep incisional biopsy, or total excisional biopsy (if the lesion is small) are all options when penile cancer is suspected. Over 90% of penile cancers are SCCs. Verrucous carcinoma are a low-grade, well-differentiated variant of SCC that appears wart-like and exophytic (cauliflower-like). Verrucous carcinomas are slow-growing but locally destructive. Important differential diagnoses of penile cancers include genital warts, psoriasis, lichen planus, plasma cell (Zoon’s) balanitis, syphilis and *in situ* SCC (penile intraepithelial neoplasia).

A full clinical examination is necessary to clinically stage penile cancer, particularly examining regional lymph nodes. Magnetic resonance imaging (MRI) may help with local

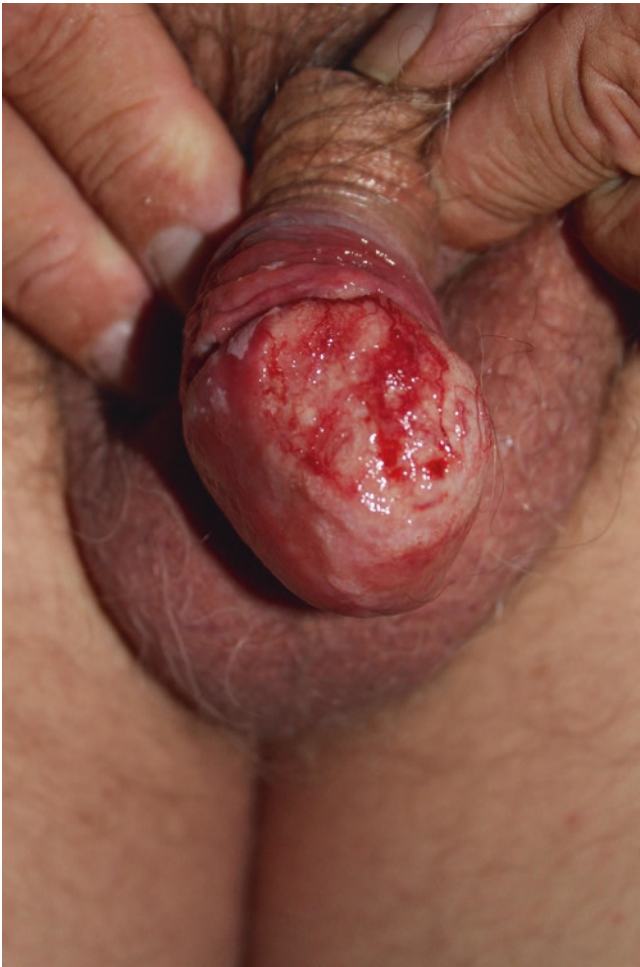

Fig. 53.4 Poorly differentiated squamous cell carcinoma of glans penis. (Patient subsequently died of metastatic squamous cell carcinoma from this penile SCC)

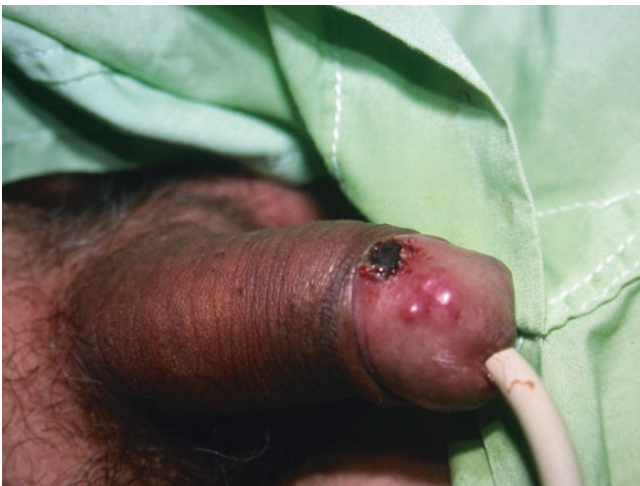

Fig. 53.5 Metastases from prostate cancer on glans penis

staging. Palpable lymph nodes can be sampled by ultrasound-guided fine needle aspiration (FNA) for histological exami-

nation. Sentinel lymph node biopsy may help staging when lymph nodes are not clinically involved. If suspicious of distant metastases, positron emission tomography (PET) is probably more reliable than routine chest radiography, radionuclide bone scanning or computerised tomography (CT) scans.

53.5 Treatment

Treatment of penile cancer needs to balance complete removal of the cancer while minimising any adverse functional or cosmetic outcome. Penile cancer is a potentially fatal disease with greater than 85% 5-year survival if the lymph nodes are histologically clear but less than 45% 5-year survival if lymph nodes are involved. Though surgical excision is the standard of care for invasive penile SCC, non-surgical treatments are appropriate for *in situ* SCC (PIN). Penile preserving surgery is preferred and achievable, as most penile SCCs occur on the glans. Partial glansectomy, total glansectomy or total penectomy are surgical options. Mohs' micrographic surgery (with the aim of maximising clearance of the cancer while minimising the tissue excised) has been successfully used for penile SCC. Alternatives to surgical excision include radiotherapy with external beam radiotherapy or brachytherapy, both achieving excellent results. Chemotherapy is reserved for metastatic disease. Lymph node dissection may be performed prophylactically if lymph nodes are not clinically involved, or therapeutically if there is clinical or histological evidence of spread. Sentinel lymph node biopsy aids the staging of penile cancer and helps in deciding if regional lymph node dissection is necessary. Targeted therapy will become more important for advanced disease, but presently it has shown more benefit for metastatic or advanced BCCs than for cutaneous SCC. Careful follow-up of all patients with penile cancer is necessary after treatment. Female sexual partners should be checked for HPV infection and any cervical abnormality as well as HPV DNA testing of cervical cells or a Papanicolaou (Pap) smear test.

Penile cancer appears to be increasing in the developed world [4, 5]. This increase may be explained by changes in sexual practices, greater exposure to sexually transmitted HPV and decreasing rates of neonatal circumcision [5]. Penile cancer may be partly preventable by treatment of acquired phimosis (mostly lichen sclerosus), limiting penile HPV infections (through HPV vaccination and condom use) and encouraging smoking cessation [6]. Because of the long lag-time between HPV infection and the development of penile SCC, it will take many years to prove whether HPV vaccination will reduce or prevent penile cancer.

Pearls

- Biopsy any suspicious penile lesion, especially eroded or ulcerated lesions of the glans.
- Penile carcinoma is rare in circumcised men but may occur after circumcision for lichen sclerosus with phimosis.
- Male recipients of solid organ transplants have increased risk for penile cancer. Genital examination should be part of routine post-transplant surveillance.
- Penile cancer may be partly preventable by neonatal circumcision, treatment of phimosis, HPV vaccination, treatment of genital inflammatory skin diseases, avoidance of genital UV exposure and cessation of smoking.

References

1. Gregoire L, Cubilla AL, Reuter VE, Haas GP, Lancaster WD. Preferential association of human papillomavirus with high-grade histologic variants of penile-invasive squamous cell carcinoma. *J Natl Cancer Inst.* 1995;87:1705–9.
2. Dillner J, von Krogh G, Horenblas S, Meijer CJ. Etiology of squamous cell carcinoma of the penis. *Scand J Urol Nephrol Suppl.* 2000;34(205):189–93.
3. Nadhan KS, Larijani M, Abbott J, Doyle AM, Linfante AW, Chung CL. Prevalence and types of genital lesions in organ transplant recipients. *JAMA Dermatol.* 2018;154:323–9.
4. Frisch M, Van Howe RS. Is the trend in primary penile cancer in England real? *Cancer Causes Control.* 2014;25:405–6.
5. Arya M, Li R, Pegler K, Sangar V, Kelly JD, Minhas S, et al. Long-term trends in incidence, survival and mortality of primary penile cancer in England. *Cancer Causes Control.* 2013;24:2169–76.
6. Marchionne E, Perez C, Hui A, Khachemoune A. Penile squamous cell carcinoma: a review of the literature and case report treated with Mohs micrographic surgery. *An Bras Dermatol.* 2017;92:95–9.

Buschke-Löwenstein Tumour (Giant Condyloma Acuminatum) and Verrucous Carcinoma

54

54.1 Definition

Buschke-Löwenstein tumour or giant condyloma acuminatum is a rare, slow-growing, exophytic anogenital tumour that is locally destructive and has significant risk for malignant transformation. Buschke-Löwenstein tumour is considered a variant of verrucous carcinoma.

54.2 Aetiology

Common genital warts (condyloma acuminata) are most commonly associated with the low-risk human papilloma-virus (HPV) types 6 and 11. As most Buschke-Löwenstein tumours (giant condyloma acuminatum) are associated with these low-risk HPV types 6 and 11 (and occasionally with high-risk HPV types 16 and 18), Buschke-Löwenstein tumour may be considered a sexually transmissible infection (STI) [1, 2]. Most genital warts regress or involute within a few years (more than 90% within 18 months). Rarely common genital warts progress to Buschke-Löwenstein tumour if the warts are untreated and the patient's immune status is impaired by congenital or acquired immunodeficiency. Factors leading to progression to Buschke-Löwenstein tumour include being uncircumcised (having a foreskin), alcoholism, diabetes, smoking, early onset of sexual activity, co-infection with herpes simplex virus or HIV and chemotherapy [1, 3]. After many years, Buschke-Löwenstein tumour may become locally destructive in approximately 50% of cases, but only rarely develops metastatic spread. Buschke-Löwenstein tumour is considered a variant of verrucous carcinoma, a low-grade, well-differentiated squamous cell carcinoma (SCC) [1, 2].

54.3 Clinical Features

Most patients are over 50 years of age and uncircumcised. Some have a past history of ano-genital warts (condyloma acuminata) or other previous STIs (including HIV infection), diabetes mellitus, immunosuppression, alcoholism or are undergoing chemotherapy. The Buschke-Löwenstein tumour has often been growing slowly for years, as embarrassment leads many patients to present late. Offensive odor, bleeding or discomfort may bring the patient to medical attention. Buschke-Löwenstein tumour of the perineum or perianal region may lead to sinuses and fistulae. Most patients are systemically unwell only if their tumour is well advanced. Buschke-Löwenstein tumours are usually large, cauliflower-like tumours of the glans, scrotum, perianal or perineal regions (Figs. 54.1 and 54.2). The tumour may be eroded, ulcerated, weeping or bleeding, with an offensive odor. The fungating tumour may totally destroy the glans and the distal penile shaft and can extend onto adjacent groins, perineum, perianal region or buttocks (Fig. 54.2).

54.4 Diagnosis

Diagnosis of Buschke-Löwenstein tumour is based on clinical findings of a slow-growing, cauliflower-like ano-genital tumour that is locally destructive, with an otherwise normal clinical examination, exclusion of distant spread by imaging and supported by histopathology. A large, slow-growing cauliflower-like penile tumour that progressively destroys the glans, scrotum or perianal region is suggestive of Buschke-Löwenstein tumour (*see* Fig. 54.1). Careful clinical examination, including perineal, perianal and rectal examination, is important to exclude local lymph node involvement or evi-

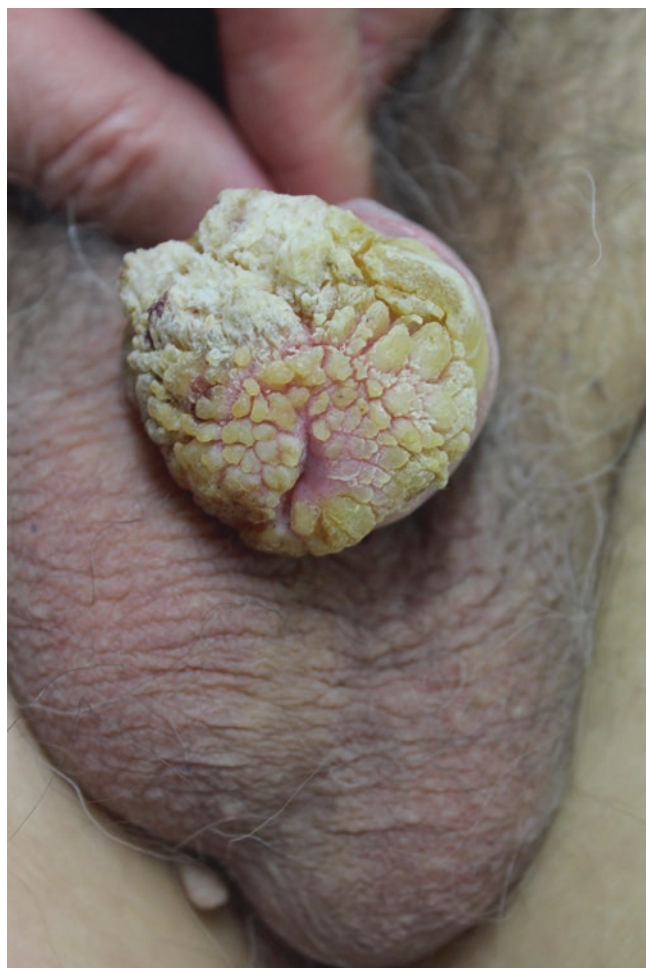

Fig. 54.1 Wart-like Buschke-Löwenstein tumour of the glans penis

dence of spread. Deep excisional biopsy is necessary to confirm the diagnosis of Buschke-Löwenstein tumour, but histology is not always definitive. The histology is similar to common benign genital warts with acanthosis, hyperkeratosis, papillomatosis and koilocytosis, consistent with HPV infection [1, 2]. Deep local invasion or evidence of low-grade, well-differentiated SCC may be present. Although the histology appears benign, Buschke-Löwenstein tumour is a locally destructive tumour that does not spontaneously resolve. Important investigations include exclusion of other STIs, including HIV and syphilis. Imaging with computerised tomography (CT) or magnetic resonance imaging (MRI) of the local tumour, pelvis, abdomen and chest is necessary to exclude local and distant spread. Differential diagnoses include extensive genital warts, condyloma lata (syphilis), multiple seborrhoeic keratoses and ano-genital squamous cell carcinoma (SCC).

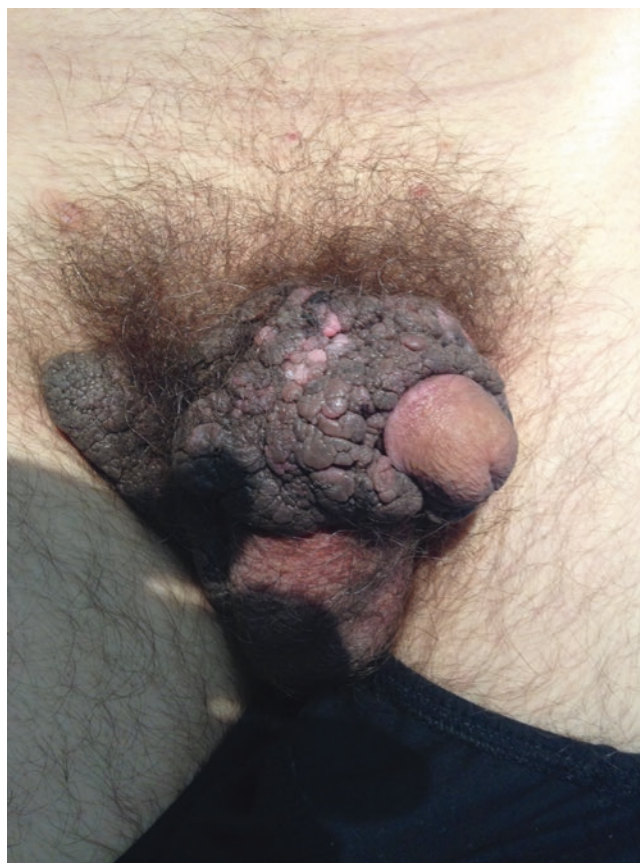

Fig. 54.2 Large pigmented Buschke-Löwenstein tumour surrounding penile shaft and extending to right groin

54.5 Treatment

Adequate early treatment of anogenital warts (condyloma acuminata) may halt progression to Buschke-Löwenstein tumour [1]. Increasing use of HPV vaccine has been shown to reduce the incidence of genital warts, so HPV vaccine may also reduce the likelihood of Buschke-Löwenstein tumour in susceptible people if given before or after HPV exposure [2]. Early treatment of Buschke-Löwenstein tumour with wide local excision may prevent local destruction [1, 2, 4], as up to 50% of Buschke-Löwenstein tumours progress to invasive cancer [2, 3]. Topical treatments such as cryotherapy and topical imiquimod are suitable for common genital warts but are not adequate to treat Buschke-Löwenstein tumour. Alternatives to wide local excision include Mohs' micrographic surgery and laser destruction. An HIV-infected patient with a large pelvic Buschke-Löwenstein tumour was successfully treated with antiretroviral therapy without surgery [5]. Treatment with radiotherapy is contraindicated because of the potential risk of transformation to anaplastic carcinoma [2]. Buschke-Löwenstein tumour has a recurrence

rate up to 50% [3], so careful long-term follow-up is necessary. Extensive disease or recurrent disease may need treatment with chemotherapy or even radiotherapy, despite the potential risk of transformation to anaplastic carcinoma. Newer targeted biologic therapies may prove more effective for advanced disease in the future. The overall mortality rate for Buschke-Löwenstein tumour is 20% [2].

Pearls

- Buschke-Löwenstein tumour is a rare, slow-growing, but locally destructive tumour, with significant risk of malignant transformation.
- Genital warts may rarely transform into Buschke-Löwenstein tumour in susceptible people.
- Wide local excision is the treatment of choice for Buschke-Löwenstein tumour.
- HPV vaccine prevents genital warts and may prevent Buschke-Löwenstein tumour.

References

1. Kim HG, Kesey JE, Griswold JA. Giant anorectal condyloma acuminatum of Buschke-Löwenstein presents difficult management decisions. *J Surg Case Rep.* 2018;2018:rjy058.
2. Sandhu R, Min Z, Bhanot N. A gigantic anogenital lesion: Buschke-Löwenstein tumor. *Case Rep Dermatol Med.* 2014;2014:650714.
3. Venter F, Heidari A, Viehweg M, Rivera M, Natarajan P, Cobos E. Giant condylomata acuminata of Buschke-Löwenstein associated with paraneoplastic hypercalcemia. *J Investig Med High Impact Case Rep.* 2018;6:2324709618758348. eCollection 2018 Jan-Dec.
4. Patel R, Kaloucava S. A case of penile Buschke-Löwenstein tumor in a developing country. *Clin Case Rep.* 2017;5:257-9.
5. Grodner C, Henn A, Lelièvre JD, Gallien S. Successful improvement of Buschke-Löwenstein tumour in an HIV-infected patient with anti-retroviral therapy alone. *BMJ Case Rep.* 2016;2016:bcr2016217753. <https://doi.org/10.1136/bcr-2016-217753>.

55.1 Definition

Melanoma is a cutaneous cancer of melanocytes (pigment-producing cells) that may appear on sun-protected sites such as ano-genital region.

55.2 Aetiology

Genital melanoma is very rare, representing less than 2% of all penile cancers and less than 1% of all cutaneous melanomas [1, 2]. Cutaneous melanomas arise as result of a mutation in melanocytes (pigment-producing cells). Melanoma has the greatest number of mutations of any human cancer. Genetic and environmental factors (mostly ultraviolet radiation) are both important in the development of cutaneous melanoma. A past history or positive family history for melanoma are important risk factors. Cutaneous melanoma and genital melanoma are predominantly cancers of fair-skinned people. Because the genitals are mostly sun-protected, aetiological factors for genital melanoma are unknown.

55.3 Clinical Features

Genital melanoma occurs mostly in fair-skinned men aged 50–70 years. A past or family history for melanoma and non-melanoma skin cancers is important. An asymptomatic brown to black lesion may be detected on the penis or scrotum (Figs. 55.1 and 55.2). A recent change in the size or appearance of this lesion may bring the patient to medical attention. The pigmented lesion may have been present for some time, as many men conceal concerns of genital disease because of embarrassment or fear. Rarely, genital melanoma may result in ulceration, bleeding, urinary difficulties or pain with sexual activity. Genital melanoma may be detected at a routine skin examination. Clinically, genital melanoma usually appears as a solitary brown to black irregular macule or small patch. Nodular melanoma may be detected as a

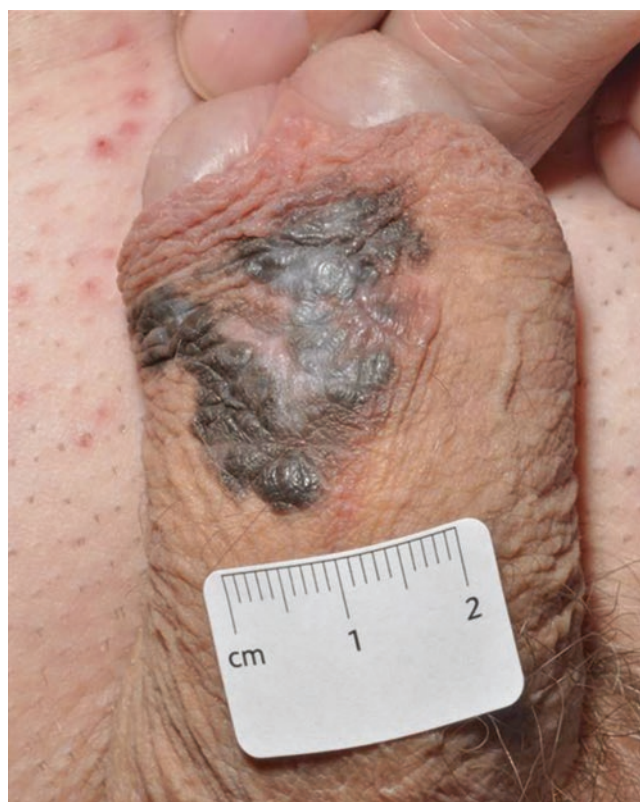

Fig. 55.1 Melanoma of the penile shaft

pigmented papule or nodule. Rarely, genital melanomas may be multifocal. The most common site for a genital melanoma is the glans, followed by the foreskin, penile shaft, urethral meatus, and rarely, the scrotum [1, 3].

55.4 Diagnosis

Penile melanoma is the most important pigmented genital lesion to diagnose. Unfortunately, penile melanoma is often diagnosed late. Clinical suspicion is important as early diagnosis and treatment may improve prognosis. No diagnostic criteria have been formulated for genital melanoma, but the

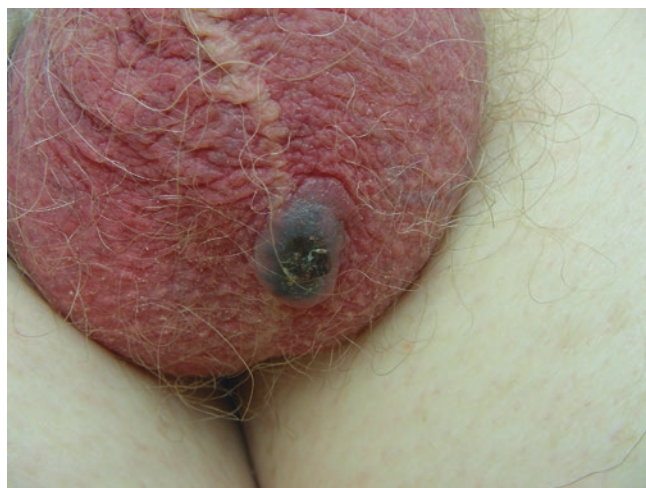

Fig. 55.2 Melanoma of the scrotum

“ABCDE” criteria (*asymmetric* pigmentation, *border* irregularity, more than one *colour*, *diameter* greater than 6 mm, and *evolving* or *enlargement*) that are used to differentiate benign melanocytic nevi from melanoma, may be useful for diagnosing a genital melanoma. Dermoscopy may aid clinical diagnosis [4, 5]. Full body examination is important as 40–50% of patients with penile melanomas have inguinal lymph node enlargement at the time of diagnosis [1]. Full skin examination may also detect other pigmented lesions or skin cancers. Histological confirmation of clinical diagnosis is essential. Biopsy of a pigmented lesion on the glans may be difficult, but incisional biopsy, excisional biopsy or shave biopsy are the best options. A small punch biopsy of a pigmented lesion should be avoided as the limited, small sample risks missing a focus of melanoma. Important differential diagnoses include genital melanotic macule (genital melanosis); junctional, compound, or dysplastic melanocytic nevus; lentigo; post-inflammatory hyperpigmentation; lichen sclerosus; lichen planus; and pigmented *in situ* squamous cell carcinoma (SCC) (penile intraepithelial neoplasia). Hypopigmented or amelanotic melanoma has a broader differential diagnosis that includes many non-pigmented diseases such as eczema, psoriasis, genital warts, plasma cell (Zoon’s) balanitis and fixed drug eruption.

55.5 Treatment

Overall, genital melanoma has a poorer prognosis than melanoma at other sites. Prognosis is determined by Breslow thickness, Clark’s level, ulceration, mitotic figures, and clinical or histological evidence of metastases to inguinal or pelvic lymph nodes [2, 4]. Primary excision is the treatment of

choice, aiming for adequate clearance with clear histologic margins [6]. There is no consensus on excision margins for genital melanoma, but excision margins are based on Breslow thickness. Opinions differ on the extent of surgery for local disease, owing to the poorer prognosis of genital melanoma. Recommended surgical margins range from circumcision (for melanoma confined to the foreskin) to simple local excision, wide local excision, glansectomy, partial penectomy and total penectomy [1, 2]. Mohs’ micrographic surgery is an alternative surgical approach. If there is clinical inguinal lymph node enlargement, bilateral inguinal lymph node dissection is usually performed. There is debate on the management of clinically uninvolved lymph nodes. Sentinel lymph node biopsy might determine if a patient may benefit from regional lymph node dissection, but sentinel lymph node biopsy presents difficulties when applied to penile melanoma [6]. Topical imiquimod has been used to successfully treat *in situ* penile melanoma [7]. Metastatic disease is treated with surgical resection of metastatic deposits, chemotherapy, immunotherapy, and targeted (biologic) therapy [6].

Pearls

- Benign genital melanotic macules (genital melanosis) mimic genital melanoma.
- Melanoma of the male genitals has a poorer prognosis than melanoma at other sites.
- Early diagnosis of genital melanoma is important for earlier treatment.

References

1. Baraziol R, Schiavon M, Fraccalanza E, De Giorgi G. Melanoma in situ of penis: a very rare entity: a case report and review of the literature. *Medicine (Baltimore)*. 2017;96:e7652.
2. Li Y, Yuan H, Wang A, Zhang Z, Wu J, Wei Q. Malignant melanoma of the penis and urethra: one case report. *World J Surg Oncol*. 2014;12:340.
3. Zikry J, Chapman LW, Korta DZ, Smith J. Scrotal melanoma: a systematic review of presentation, treatment, and outcomes. *Dermatol Surg*. 2017;43:765–70.
4. Bechara GR, Schwindt AB, Ornellas AA, Silva DE, Lott FM, Campos FS. Penile primary melanoma: analysis of 6 patients treated at Brazilian National Cancer Institute in the last eight years. *Int Braz J Urol*. 2013;39:823–31.
5. De Giorgi V, Grazzini M, Massi D, Rossari S, Gori A, Janowska A, et al. Melanoma of the penis: a clinical dermoscopic case study. *Acta Derm Venereol*. 2010;90:87–8.
6. Moses KA, Sfakianos JP, Winer A, Bernstein M, Russo P, Dalbagni G. Non-squamous cell carcinoma of the penis: single-center, 15-year experience. *World J Urol*. 2014;32:1347–53.
7. Napolitano M, Annessi G, Didona D, Didona B. Multifocal melanoma in situ of the penis treated with topical imiquimod. *J Eur Acad Dermatol Venereol*. 2016;30:458–60.

56.1 Definition

Extramammary Paget's disease is a rare intraepithelial adenocarcinoma of ano-genital or axillary regions that resembles Paget's disease of the breast clinically and histologically.

56.2 Aetiology

Paget's (or Paget) disease of the nipple is epidermal invasion of intraductal carcinoma of the breast. Extramammary Paget's disease is a rare intraepidermal adenocarcinoma arising from apocrine glands of the anogenital region and axillae. Extramammary Paget's disease is seen in both sexes. Extramammary Paget's disease is divided into primary and secondary disease, but this distinction is not always clear. Primary extramammary Paget's disease occurs without internal malignancy, whereas secondary disease is defined as cutaneous disease occurring within 5 years of an internal cancer. Primary disease is assumed to arise within the skin. Up to 11% of patients with extramammary Paget's disease have an associated urinary or gastrointestinal tract cancer [1, 2]. Secondary extramammary Paget's disease is assumed to extend from the underlying internal adenocarcinoma.

56.3 Clinical Features

Extramammary Paget's disease usually appears in patients between 60 and 70 years of age as a slowly progressing red patch or plaque of the ano-genital region. Symptoms include itch, irritation, burning sensation, weeping, oozing, discharge or bleeding. Often many topical treatments have been tried or prescribed for presumed eczema with limited effect. The initial site is usually the inguinal region or scrotum (Fig. 56.1). Extramammary Paget's disease slowly progresses to a well-demarcated plaque of the groin, scrotum, penis, perineum, or perianal region, that may be unilateral

(Fig. 56.2) or symmetrical ("underpants" pattern) (Fig. 56.3). Scale, excoriation or lichenification may be seen. Extramammary Paget's disease may be multifocal. The cosmetic impact may be considerable. Focal thickening or ulceration may indicate dermal invasion, that occurs in up to 25% of patients with primary extramammary Paget's disease [1]. Extramammary Paget's disease may metastasise to regional lymph nodes (up to 23% of cases) or more distantly [2].

56.4 Diagnosis

There is often significant delay in diagnosis [2]. Extramammary Paget's disease is often mistaken for irritant dermatitis ("jock itch"), psoriasis, candidiasis or tinea cruris. Other differential diagnoses include Hailey-Hailey disease, flexural Darier's disease, *in situ* squamous cell carcinoma and basal cell carcinoma. Occasionally, extramammary Paget's disease presents as a white patch that is mistaken for vitiligo or lichen sclerosus. Diagnosis is based on clinical suspicion and diagnostic biopsy. Histological features are similar to mammary Paget's disease, with clear pagetoid cells scattered within the epidermis, an upper dermal lymphocytic inflammatory cell infiltrate, associated papillomatosis, acanthosis, crusting and an eroded or atrophic epidermis. Extramammary Paget's disease needs to be histologically differentiated from superficial spreading melanoma. A full clinical examination is necessary, including examination of the regional lymph nodes and rectum. Clinically enlarged regional lymph nodes can be assessed by ultrasonography or fine needle aspiration cytology. A thorough search should be undertaken for any associated internal malignancy of the urinary tract, prostate, and lower gastrointestinal tract. Useful investigations include pelvic computed tomography (CT) scans, positron emission tomography-CT (PET-CT) imaging, colonoscopy, bladder endoscopy and prostate examination.

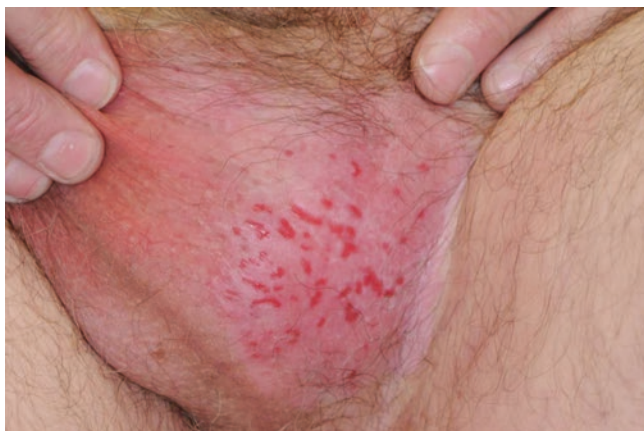

Fig. 56.1 Erosions of groin and scrotum of early extramammary Paget's disease

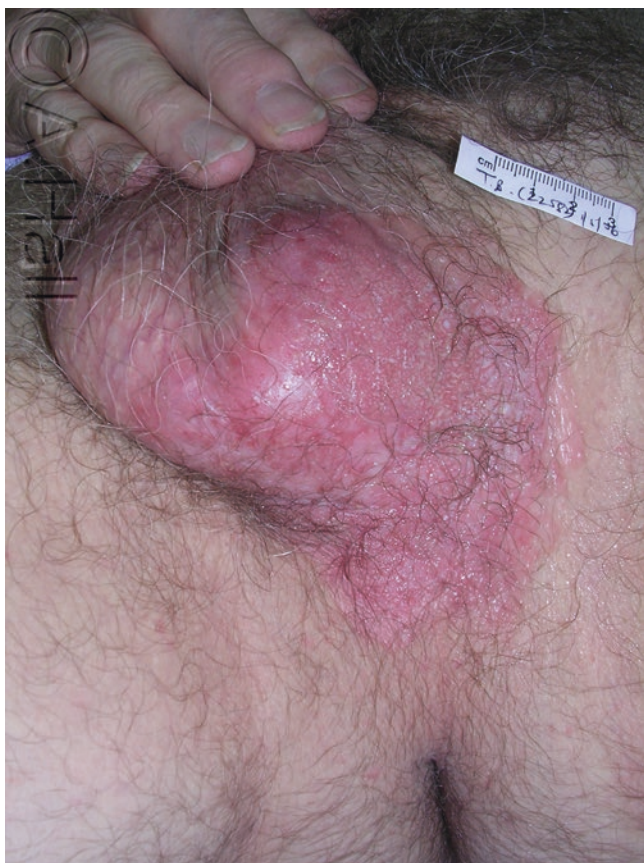

Fig. 56.2 Thick plaque of extramammary Paget's disease on the left scrotum and groin

56.5 Treatment

Extramammary Paget's disease is a complex disease with primary and secondary forms that may be multifocal (skip lesions), making treatment more complicated. Medical literature is biased towards more advanced disease, which subse-

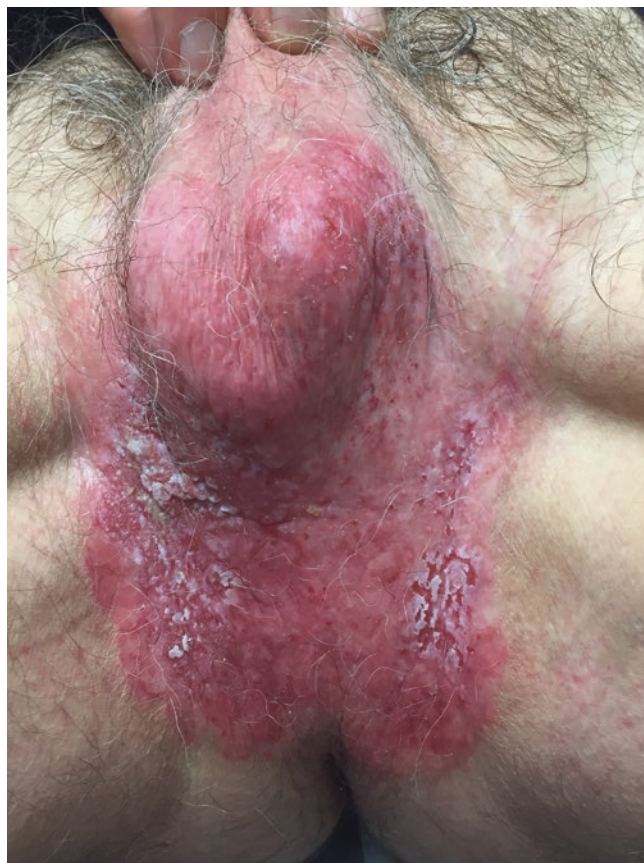

Fig. 56.3 Symmetrical ("underpants") pattern of extramammary Paget's disease involving the scrotum, groins, and perineum

quently biases treatment options. The risk of malignant transformation to invasive adenocarcinoma, the risk of associated internal malignancy (secondary disease), rates of recurrence after local excision and overall prognosis are not accurately known.

No single treatment is universally effective for all patients. Before beginning treatment, it is important to assess the patient's general health, age, and desire for active treatment. Management by a multidisciplinary team is best. All treatment options need to be openly discussed, including simple observation and symptomatic treatment. Treatment of any associated malignancy takes priority. Recurrence rates are significant (up to 25%), with a greater recurrence rate (up to 50%) for patients with perianal disease [1, 3]. Nonsurgical treatments include cryotherapy, topical 5-fluorouracil, topical imiquimod [4], laser ablation, and photodynamic therapy (PDT). Surgical treatments include wide local excision with a 2-centimetre margin and Mohs' micrographic surgery. The wide surgical excision margin may need to be modified in the anogenital region. Topical imiquimod may be used for small local recurrences. The role of prophylactic regional lymph node dissection is debated [5]. Dynamic sentinel lymph node biopsy may detect subclinical spread to regional

lymph nodes and help to direct elective surgical lymphadenectomy. Elective surgical lymphadenectomy is recommended for infiltrative disease or metastases to groin lymph nodes [1]. Superficial radiotherapy is an alternative non-surgical treatment modality that may have been underexplored. Treatment of metastatic disease requires chemotherapy. The role of targeted (biologic) therapies is presently unclear. All patients need ongoing support, careful monitoring and long-term follow-up.

Pearls

- Extramammary Paget's disease is often misdiagnosed and treated as irritant dermatitis.
- Treatment of genital extramammary Paget's disease requires a multimodality approach.
- Male genital extramammary Paget's disease is often multifocal and recurrences are common. Long-term follow-up is essential.

References

1. Christodoulidou M, Khetrapal P, Mitra A, Muneer A. A case of metastatic adenocarcinoma on a background of penoscrotal extramammary Paget's disease. *BMJ Case Rep.* 2015;2015:bcr2015211350. <https://doi.org/10.1136/bcr-2015-211350>.
2. Kang Z, Zhang Q, Zhang Q, Li X, Hu T, Xu X, et al. Clinical and pathological characteristics of extramammary Paget's disease: report of 246 Chinese male patients. *Int J Clin Exp Pathol.* 2015;8:13233–40.
3. Perez DR, Trakarnsanga A, Shia J, Nash GM, Temple LK, Paty PB, et al. Management and outcome of perianal Paget's disease: a 6-decade institutional experience. *Dis Colon Rectum.* 2014;57:747–51.
4. Liao MM, Yang SS, Tan KB, Aw CW. Topical imiquimod in the treatment of extramammary Paget's disease: a 10 year retrospective analysis in an Asian tertiary Centre. *Dermatol Ther.* 2016;29:459–62.
5. Dai B, Kong YY, Chang K, Qu YY, Ye DW, Zhang SL, et al. Primary invasive carcinoma associated with penoscrotal extramammary Paget's disease: a clinicopathological analysis of 56 cases. *BJU Int.* 2015;115:153–60.

Index

A

Abscesses, 133
Acantholytic dermatosis, 126
Aciclovir, 85
Acne inversa, 133
Acrofacial vitiligo, 161
Addison's disease, 154
Adenocarcinoma, 189, 190
Alezzandrini syndrome, 162
Allergen, 49
Allergic contact dermatitis, 29, 59
 aetiology, 49
 clinical features, 49
 definition, 49
 diagnosis, 49
 treatment, 50
Anal intraepithelial neoplasia (AIN), 89, 173
Anderson-Fabry disease, 19
Angiofibromas, 13
Angiokeratoma of Fordyce
 aetiology of, 19
 clinical features, 19
 definition, 19
 diagnosis of, 19
 treatment of, 19
Angiotensin-converting enzyme, 114
Ano-genital chronic dermatitis, 54
Anti-tumour necrosis factor (TNF) therapy, 115
Aphthous stomatitis, 141
Aphthous ulcers
 aetiology, 141
 clinical features, 141
 definition, 141
 diagnosis, 141
 treatment, 142, 143
Artefactual disease, 147
Atopic dermatitis
 aetiology, 41
 definition, 41
 diagnosis, 41
 treatment, 42, 43
Atopic eczema, 41
ATP2A2 gene, 125
ATP2C1 gene, 129
Atypical nevi, 151
Auto-amputation, 149
Autoimmune diseases, 161

B

Balanitis and balanoposthitis
 aetiology, 29
 clinical features, 29
 definition, 29
 diagnosis, 30
 treatment, 31
Balanitis circumscripta plasmacellularis, 71
Balanitis xerotica obliterans (BXO), 25, 61
Bannayan-Riley-Ruvalcaba
 syndrome, 153, 154
Basal cell carcinoma (BCC), 179
Behçet's disease
 aetiology, 141
 clinical features, 141
 definition, 141
 diagnosis, 142
 genital ulcers of, 142
 oral aphthous ulceration, 142
 scrotal ulcer of, 142
 treatment, 143
Benign melanocytic nevus
 aetiology, 151
 clinical features, 151
 definition, 151
 diagnosis, 152
 glans penis, 151
 penile shaft of an adult male, 152
 shaft of penis, 151
 treatment, 152
Bland emollients, 11
Boils, 135
Bowen's disease, 169
Bowenoid papulosis, 169
 aetiology, 173
 clinical features, 173, 174
 definition, 173
 diagnosis, 174
 treatment, 174, 175
Bulla, 6
Burning scrotum syndrome, 117
Buschke-Löwenstein tumour, 158
 aetiology, 183
 clinical features, 183
 definition, 183
 diagnosis of, 183, 184
 treatment, 184, 185

C

Calcineurin inhibitors, 11
 Calcipotriol, 11
Candida albicans, 75
 Candidiasis, 29, 34
 aetiology, 75
 clinical features, 75
 definition, 75
 diagnosis, 76
 treatment, 76
 Canker sores, 141
 Carbon dioxide laser, 14
 Carney complex, 154
 Cayenne pepper, 71
 Cellulitis, 41
 Cerebrospinal fluid (CSF) testing, 100
 Cervical intraepithelial neoplasia (CIN), 173
 Chancres, 99
Chlamydia trachomatis infection, 7, 145
 Chronic genital lymphedema
 aetiology, 113
 clinical features, 113, 114
 definition, 113
 diagnosis, 114, 115
 treatment, 115
 Chronic plaque psoriasis, 37
 Cicatricial pemphigoid, 137
 Circinate balanitis, 145
 Circumcision, 26
 Clark's nevus, 151
 Clinico-pathological correlation, 7
 Cobblestone, 53
 Colonoscopy, 135
 Comedones, 133
 Community-acquired methicillin resistance (MRSA), 94
 Complex aphthosis, 141
 Compound melanocytic nevi, 152
 Condyloma acuminata, 13, 87
 Condylomata lata, 89, 99
 Congenital melanocytic nevi, 151
 Conjunctivitis, 145
 Cool bathing, 11
Corynebacterium minutissimum, 97
 C-reactive protein (CRP), 135, 145
 Crohn's disease, 109
 Crusted scabies, 103
 Cryotherapy, 14, 159
 Curettage, 14
 Curette biopsy, 8
 Cutaneous patch testing, 49

D

Dandruff, 57
 Darier's disease, 59
 clinical features, 125, 126
 definition, 125
 diagnosis, 127
 etiology, 125
 treatment, 127
 Delayed (type 4) hypersensitivity, 49
 Depigmentation, 23
 aetiology, 161
 clinical features, 161
 definition, 161
 diagnosis, 161, 162
 treatment, 163

Dermatitis artifacta, 29
 Dermatophytic fungi, 79
 Dermatoses, 158
 Dermoscopy, 67, 188
 Disease-modifying antirheumatic drugs (DMARDs), 146
 DNA pox virus, 91
 Dowling-Degos disease, 127
 Dry skin swab, 7
 Dysfunctional foreskin, 71
 Dyspareunia, 61
 Dysplastic nevus, 151

E

Ecthyma, 93
 Ectopic sebaceous glands, 15
 Eczema, 45
 Electrodesiccation, 14
 Epidermal cysts
 aetiology, 165
 clinical features, 165
 definition, 165
 diagnosis, 167
 treatment, 167
Epidermophyton floccosum, 79
 Er:YAG laser, 14
 Erosions, 6, 137
 Erosive, 67–69
 Erythrasma
 aetiology, 97
 clinical features, 97
 definition, 97
 diagnosis, 98
 treatment, 98
 Erythrocyte sedimentation rate (ESR), 135
 Erythrodermic psoriasis, 37
 Erythromelalgia, 117
 Erythroplasia of Queyrat, 169
 Excisional biopsy, 7
 Extensive scabies papules, 104
 Extramammary Paget's disease, 58, 59, 179
 aetiology, 189
 clinical features, 189
 definition, 189
 diagnosis, 189
 treatment, 190, 191

F

Factitious disorder, 147
 Famciclovir, 85
 Familial benign chronic pemphigus, 129
 Filariasis, 115
 Fine needle aspiration (FNA), 181
 Fixed drug eruption, 29
 aetiology, 123
 clinical features, 123
 definition, 123
 diagnosis of, 123, 124
 treatment, 124
 Flexural Darier's disease, 189
 Flexural psoriasis, 59
 Fluorescent treponemal antibody absorbed (FTA-Abs)
 test, 100
Follicular occlusion triad, 133
 Fordyce spots, 13

- aetiology, 15
- clinical features, 15
- definition, 15
- treatment of, 16

Foreskin, 1, 2, 25, 29

Fournier's gangrene

- aetiology, 95
- clinical features, 95
- definition, 95
- diagnosis, 95
- treatment, 95

Fractionated CO₂ laser, 14

G

Gardner syndrome, 167

Genital cutaneous metastases, 179

Genital erosions, 83

Genital granulomatosis, 109

Genital granulomatous diseases

- aetiology, 109
- clinical features, 109, 110
- definition, 109
- diagnosis of, 110
- treatment, 111

Genital lentiginosis

- aetiology, 153
- clinical features, 154
- definition, 153
- diagnosis, 154
- treatment, 155

Genital melanoma

- aetiology, 187
- clinical features, 187
- definition, 187
- diagnosis, 187, 188
- treatment, 188

Genital melanosis, 188

Genital melanotic macules, 21, 23

- aetiology, 153
- clinical features, 153, 154
- definition, 153
- diagnosis, 154
- treatment, 155

Genital skin disease, 1

- clinical examination, 5, 6
- history, 3
- investigations, 7
- management of, 11
- skin biopsy, 7–9

Genital trauma

- aetiology, 147
- clinical features, 148
- definition, 147
- diagnosis of, 148
- treatment, 149

Genital ulceration, 83

Genital warts, 159

- aetiology, 87
- clinical features, 87
- definition, 87
- diagnosis of, 89
- treatment, 89

Giant condyloma acuminatum, 183

Glans penis, 29

Gummatous lesions, 99

Guttate psoriasis, 37

H

Hailey-Hailey disease, 58, 59, 189

- aetiology, 129
- clinical features, 129
- definition, 129
- diagnosis, 129
- treatment, 129, 130

Hair follicles, 15

Head lice, 107

Hematoxylin and eosin (H&E) staining, 110

Herpes simplex virus (HSV), 7, 95, 141, 142

- aetiology, 83
- clinical features, 83, 84
- definition, 83
- treatment, 85

Herpes simplex virus type 1 (HSV-1), 83

Herpes simplex virus type 2 (HSV-2), 83

Hidradenitis suppurativa

- aetiology, 133
- clinical features, 133
- definition, 133
- diagnosis, 135
- treatment, 135

HLA-B27 testing, 146

HPV type 6 (HPV-6), 87

HPV type 11 (HPV-11), 87

HPV type 16 (HPV-16), 87

HPV type 18 (HPV-18), 87

Human leukocyte antigen B27 (HLA-B27), 145

Human papillomavirus (HPV) infection, 87, 169, 173, 179, 183

Hypercoagulability, 121

Hyperkeratotic plaque, 67, 68

Hyperpigmentation, 21

Hypertrophic scar, 6

Hypopigmentation, 21, 161, 162

I

Idiopathic scrotal calcinosis

- aetiology, 165
- clinical features, 165
- definition, 165
- diagnosis, 167
- treatment, 167

Immuno-bullous diseases, 137

Impetiginisation, 41

Impetigo

- aetiology, 93
- clinical features, 93
- definition, 93
- diagnosis, 93
- treatment, 94

In situ squamous cell carcinoma (SCC), 76, 169

Incisional biopsy, 7

Infestation, 103

Infundibular cysts, 165

Interferon-gamma release assay test, 114

Intertriginous dermatoses

- aetiology, 33
- causes of, 33
- clinical features, 34
- definition, 33
- diagnosis, 35
- treatment, 35

Intertrigo, 33, 129

Intradermal nevi, 152

Intraepithelial adenocarcinoma, 189

Inverse (flexural) psoriasis, 37
 Inverse psoriasis, 33, 34
 Irritant (contact) dermatitis, 29, 59, 76
 aetiology, 45
 balanoposthitis, 45
 clinical features, 45, 46
 definition, 45
 diagnosis of, 46
 ill-defined erythema, 46
 oral isotretinoin, 47
 secondarily infected irritant dermatitis, 46
 topical povidone-iodine solution, 47
 treatment, 46, 47
 Isomorphic phenomenon, 161

K

Kaposi's sarcoma, 179
 Keloid scar, 6
Keratoderma blenorrhagicum, 145
 Keratotic
 aetiology, 177
 clinical features, 177
 definition, 177
 diagnosis, 178
 treatment, 178
 Kissing lesion, 71
 Koebner phenomenon, 129

L

LAMB syndrome, 153
 Laugier-Hunziker syndrome, 153, 154
 Lentigo, 153
 LEOPARD syndrome, 153, 154
 Lichen planus, 76
 aetiology, 67
 clinical features, 67
 definition, 67
 diagnosis, 67
 treatment, 68
 Lichen sclerosus, 25, 29, 76
 aetiology, 61
 clinical features, 61
 definition, 61
 diagnosis, 62
 treatment, 62, 63
 Lichen simplex chronicus
 aetiology, 53
 clinical features, 53
 definition, 53
 diagnosis, 53, 54
 treatment, 54, 55

M

Macule, 6
Malassezia furfur, 57
 Male genital dysaesthesia
 aetiology, 117
 clinical features, 117
 definition, 117
 diagnosis, 117
 treatment, 117, 118
 Male genitalia, 1, 2
 Median raphe cysts

 aetiology, 15
 clinical features, 15
 definition, 15
 diagnosis of, 16
 treatment of, 16
 Melkersson-Rosenthal syndrome, 109, 113
 Micaceous balanitis
 aetiology, 177
 clinical features, 177
 definition, 177
 diagnosis, 178
 treatment, 178
 Milroy's disease, 113
 Moh's micrographic surgery, 171
 Moisturiser, 11
 Molluscum contagiosum
 aetiology, 91
 clinical features, 91
 definition, 91
 diagnosis of, 92
 Mucosal melanosis, 153
 Mycotic infection, 79

N

Narrow-band UVB (NB-UVB), 163
 Necrobiosis lipoidica, 109
 Necrotising fasciitis, 95
Neisseria gonorrhoeae infection, 7
 Neo-foreskin, 5
 Nodules, 133
 Norwegian scabies, 103
 Nucleic acid amplification testing, 7

O

Oral ivermectin, 105
 Orofacial granulomatosis, 113
 Osteomyelitis, 41

P

Palmoplantar psoriasis, 37
 Papanicolaou (Pap) smear test, 181
 Papular acantholytic dyskeratosis, 125, 126
 Papule, 6
 Papulosis nigra, 158
 Paraffin, 11
 Paraphimosis, 25
 Patch testing, 7, 49
 Pearly penile papules
 aetiology of, 13
 clinical features, 13
 definition, 13
 diagnosis, 13
 treatment, 14
 Pediculosis pubis
 aetiology, 107
 clinical features, 107
 definition, 107
 diagnosis, 107
 treatment, 107, 108
 Pemphigoid, 29
 Pemphigus and pemphigoid
 aetiology, 137
 clinical features, 137

- definition, 137
 - diagnosis, 137
 - treatment, 138
 - Pemphigus foliaceus, 137
 - Penile cancer
 - aetiology, 179
 - clinical features, 179
 - definition, 179
 - diagnosis, 180
 - treatment, 181
 - Penile cutaneous horn
 - aetiology, 177
 - clinical features, 177
 - definition, 177
 - diagnosis, 178
 - treatment, 178
 - Penile intraepithelial neoplasia (PIN), 29, 145, 173
 - aetiology, 169
 - clinical features, 169
 - definition, 169
 - diagnosis, 170
 - treatment, 170, 171
 - Penile Mondor's disease
 - aetiology, 121
 - clinical features, 121
 - definition, 121
 - diagnosis of, 121
 - treatment, 121, 122
 - Periodic acid–Schiff (PAS) staining, 80, 110
 - Permethrin, 105
 - Petrolatum, 11, 39
 - Petroleum jelly, 11
 - Peutz-Jeghers syndrome, 153, 154
 - Phimosis, 5, 61–63
 - aetiology, 25
 - clinical features, 25
 - definition, 25
 - diagnosis, 26
 - treatment, 26
 - Photodynamic therapy (PDT), 63, 127, 130, 171, 175, 190
 - Phthirus pubis, 107
 - Physiologic phimosis, 25
 - Picker's nodule
 - aetiology, 53
 - clinical features, 53
 - definition, 53
 - diagnosis, 53, 54
 - treatment, 54, 55
 - Pigmentary disorders
 - aetiology, 21
 - clinical features, 21, 22
 - definition, 21
 - diagnosis of, 23
 - treatment, 23
 - Pimecrolimus, 11
 - Pineapple skin, 53
 - Pityrosporum ovale*, 57
 - Plasma cell (Zoon's) balanitis
 - aetiology, 71
 - clinical features, 71
 - definition, 71
 - diagnosis, 72, 73
 - treatment, 73
 - Polygonal papules, 67
 - Polymerase chain reaction (PCR) testing, 7, 30, 85
 - Positron emission tomography (PET), 181
 - Post-inflammatory hyperpigmentation (PIH), 21, 23
 - Prurigo nodularis
 - aetiology, 53
 - clinical features, 53
 - definition, 53
 - diagnosis, 53, 54
 - treatment, 54, 55
 - Pruritic papules, 67
 - Pseudoepitheliomatous
 - aetiology, 177
 - clinical features, 177
 - definition, 177
 - diagnosis, 178
 - treatment, 178
 - Psoriasis, 29, 76
 - aetiology, 37
 - clinical features, 37, 38
 - definition, 37
 - diagnosis, 38, 39
 - treatment, 39, 40
 - Pubic lice, 107
 - Pulsed dye laser, 14
 - Punch biopsy, 7
 - Purple papules, 19
 - Pustular psoriasis, 37
 - PUVA lentigines, 153
- Q**
- QuantiFERON-TB Gold test, 114, 146
- R**
- Rapid diagnostic tests (RDTs), 100
 - Rapid plasma reagin (RPR), 100
 - Reactive arthritis
 - aetiology, 145
 - clinical features, 145
 - definition, 145
 - diagnosis, 145, 146
 - treatment, 146
 - Red scrotum syndrome, 22, 117
 - Reiter syndrome, 145
 - Restless genital syndrome, 117
 - Retroglandular sulcus, 2
 - Rhagades, 129
 - Roseola syphilitica, 99
- S**
- Sarcoidosis, 109
 - Sarcoptes scabiei*, 103
 - Scabies
 - aetiology, 103
 - clinical features, 103
 - definition, 103
 - diagnosis, 103, 104
 - digital web spaces, 105
 - glans penis, 104
 - hyperkeratotic, 105
 - light microscope, 105
 - treatment, 105, 106
 - Scaly plaques, 37
 - Scaly psoriasiform plaque, 145
 - Scattered scabies papules, 104
 - Sclerosing lymphangitis, 121

- Scrotal skin, 45, 49
 Scrotum, 19
 Sebo-psoriasis
 aetiology, 57
 clinical features, 57, 58
 definition, 57
 diagnosis, 58, 59
 treatment, 59
 Seborrhoeic dermatitis
 aetiology, 57
 clinical features, 57, 58
 definition, 57
 diagnosis, 58, 59
 treatment, 59
 Seborrhoeic keratosis
 aetiology, 157
 clinical features, 157, 158
 definition, 157
 diagnosis, 159
 treatment, 159
 Septic arthritis, 41
 Septicaemia, 41
 Serological testing, 7
 Sexually transmissible infection (STI), 1, 3, 11, 46, 54, 83, 92, 100, 114, 117, 121, 143, 159
 Shave biopsy, 7, 9
 Sitz bath, 11
 Skin lesions, 6
 Skin scrapings, 35
 Smegma, 5
 Snip biopsy, 8
 Soft white paraffin, 39
 Spirochete, 99
 Squamous cell carcinomas (SCC), 53, 64, 179
Staphylococcus aureus, 41, 93
Streptococcus pyogenes, 93
 Stucco keratoses, 158
 Subprepuce, 2, 5
 Suprabasilar acantholysis, 129
 Surgical excision, 14
 Syphilis, 109
 aetiology, 99
 clinical features, 99
 definition, 99
 diagnosis, 100
 treatment, 100
- T**
 Tacrolimus, 11
 Thrombosis, 121
 Tinea corporis, 80
 Tinea cruris, 34, 35, 59, 79
 Tinea incognito, 80
 Tinea/dermatophytosis
 aetiology, 79
 clinical features, 79, 80
 definition, 79
- diagnosis, 80
 treatment, 81
 Topical anthralin (dithranol), 11
 Topical calcineurin inhibitors, 42, 50
 Topical corticosteroids, 11
 Topical tazarotene, 11
 Transmission, 83
Treponema pallidum, 99
Treponema pallidum particle agglutination assay (TPPA), 100
Trichophyton mentagrophytes, 79
Trichophyton rubrum, 79
Trichophyton tonsurans, 79
 Trichrome vitiligo, 161
 Tuberculosis, 109
 Tyson's glands, 15
- U**
 Ultraviolet (UV) light treatment, 11
 Ultraviolet B therapy, 130
 Umbilication, 91
- V**
 Valaciclovir, 85
 Varicella zoster virus (VZV) infection, 85, 95
 Vegetations, 129
 Venereal Disease Research Laboratory (VDRL), 100
 Verrucous, 87
 Verrucous carcinoma, 177, 183
 Vesicle, 6
 Violaceous papules, 67
 Vitamin D analogues, 11, 40
 Vitiligo, 21, 22
 aetiology, 161
 clinical features, 161
 definition, 161
 diagnosis, 161, 162
 treatment, 163
 Vogt-Koyanagi-Harada syndrome, 162
 Vulval intraepithelial neoplasia (VIN), 173
- W**
 Waisting, 5, 25
 Wickham's striae, 67
 Wood's (UVA) lamp, 7, 97
- Y**
 Yeast organism, 75
- Z**
 Ziehl-Neelsen stain, 110
 Zoon's balanitis, 71
 Zoon's plasma cell balanitis, 29